

Research Article

Open Access

Birth and Neonatal Care Injuries: A Special Aspect of Newborn Surgery

Andreas Fette*

National Research Centre for Mother and Child Health, University of Astana, Kazakhstan
University of Pecs, Medical School, Hungary

Abstract

Nowadays birth (BI) and Neonatal Care (NCI) injuries have to be considered as a significant cause of neonatal morbidity and mortality. Since they are always delicate to manage after disclosure, they are usually less often reported. Thus, selections of extraordinary cases are presented most considerably.

The institutional files of 18 neonates have been selected. In the BI-group 2 complex injuries happened during Caesareans, 5 during vaginal deliveries, while in the NCI-group 8 happened during NICU and 3 during home care. Median time of presentation has been the 2nd (Range 1-3) day, respectively the 1st (Range 1-3) week of life. Six neonates underwent surgery, 4 closed bone reduction, the remaining 8 could be treated non-surgical. Even lethal outcomes have to be considered.

BI- injuries and NCI-injuries present as a special aspect of newborn surgery. For their successful management great expertise and empathy is needed by every individual carer in charge.

Keywords: Birth injuries; Neonatal care injuries; Obstetrical trauma; Newborn surgery

Introduction

Simple birth injuries, like clavicular fracture, cephal ohematoma or caput succedaneum, and neonatal care injuries, like bruises or malpuncture marks do happen in all day clinical practice, and for sure they will never be completely avoidable (Figure 1). However, our full attention to reduce them to an absolute minimum should nowadays be the golden standard.

But, will these tiny and most innocent babies not be at a constant risk to suffer an even more complex obstetrical (birth injury) or carer-related trauma (neonatal care injury) during or shortly after birth, anyway? Especially, since neonatal care is always multidisciplinary with obstetricians, neonatologists, intensivists, paediatric surgeons and a variety of different nursing staff involved. Focusing in their activities exclusively on one tiny individuum, and since these traumata are rare, they are usually underreported in literature and textbooks as well. Thus, in order to avoid and prevent these complex birth- and neonatal care injuries, or even their simple counterparts, highest personal attention and alert should be put up by every neonatal carer in charge.

Of course, such a topic in general and any disclosure will always are considered as very critical and unpleasant. Thus any report or discussion should never be understood in the sense of accusation, claim or harsh critique about any well-meant action undertaken by the individual neonatal carer in charge. Quite the contrary, any frank discussion and open disclosure might support and encourage us in re-focusing and re-evaluating of actual and past treatment standards and might finally provide us with the highest possible quality improvement in neonatal care.

Patients and Method

Labour ward and NICU consultation records out of the last decade regarding extraordinary birth- and neonatal care injuries have been revisited retrospectively. Sampled in either Emerging, I^o or III^o World Country institutions worldwide, the authors have been affiliated with.

The files of 18 neonates (11 term, 7 preterm, sex ratio = 1:1) have been selected for further evaluation and follow-up, before their presentation in this short communication in front of a focused literature review providing necessary background information.

According to the mode of incident and main diagnosis our sample has been divided into a birth- or neonatal care injury group. Before being further sub-classified into injuries, which have happened during Caesarean Section vs. vaginal delivery, respectively injuries that have happened in the neonatal intensive care unit vs. the neonatal home care setting. Gestational age and co-morbidities have been taken into consideration, too. Diagnoses comprised the skull, the skeleton, the integument and certain viscera, but not exclusively. In Table 1, more detailed information about the type and time of incident or injury, diagnoses and therapies are provided.

Results

According to the individual diagnosis and main incident, out of the 18 selected neonates, 7 have been classified into the birth and 11 into the neonatal care injury group, respectively.

In the birth injury group, 1 baby has been identified as preterm, the other 6 as term deliveries. The sex ratio has been 5 males to 2 females

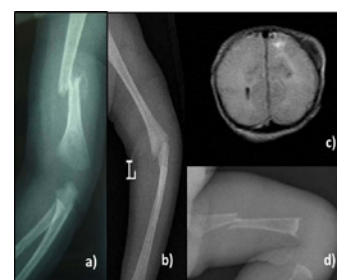


Figure 1: a) Humerus shaft fracture b) Slipped distal humerus epiphysiolysis c) Biparietal skull fracture, minor ICB, cephal hematoma d) Femur shaft fracture.

***Corresponding author:** Professor Andreas Fette, National Research Centre for Mother and Child Health, University of Astana, Kazakhstan, E-mail: andreas.fette@gmx.de

Received June 18, 2012; Accepted July 24, 2012; Published July 26, 2012

Citation: Fette A (2012) Birth and Neonatal Care Injuries: A Special Aspect of Newborn Surgery. *Pediat Therapeut* 2:132. doi:10.4172/2161-0665.1000132

Copyright: © 2012 Fette A. This is an open-access article distributed under the terms of the Creative Commons Attribution License, which permits unrestricted use, distribution, and reproduction in any medium, provided the original author and source are credited.

A) Birth Injury Group (n = 7)	
Male term, hypertrophic, delayed vaginal delivery, 1 st DOL	Incident: manual extraction on his arm Diagnosis: <i>right humerus shaft fracture</i> (Fig 1 a) Therapy: reduction, splinting .
Female term, shoulder presentation, 2 nd DOL	Incident: manual extraction on her arm Diagnosis: <i>slipped left distal humerus epiphysiolysis, slight plexus palsy</i> (Fig 1 b) Therapy: closed reduction, POP splinting, physiotherapy.
Male term, C/S, 2 nd DOL	Incident: manual extraction/forceps Diagnosis: <i>biparietal skull fracture, major ICB, (cephal hematoma)</i> Therapy: neuro-monitoring
Male term, delayed vaginal delivery, 1 st DOL	Incident: forceps extraction Diagnosis: <i>biparietal skull fracture, minor ICB, severe fits, (cephalhematoma)</i> (Fig 1 c) Therapy: neuromonitoring
Male preterm, delayed vaginal delivery, 3rd DOL	Incident: forced manual extraction Diagnosis: left femur shaft fracture, (ARDS/lung immaturity) (Fig 1 d) Therapy: closed reduction, POP splinting
Female term, C/S, 3 rd DOL	Incident: forced manual extraction Diagnosis: <i>left adrenal gland hemorrhage, (asphyxia)</i> (Fig 2 a) Therapy: monitoring, conservative.
Male term, delayed vaginal delivery, 1 st DOL	Incident: small bowel surface tearing Diagnosis: <i>mass haemorrhage, Vit K deficiency, (gastroschisis)</i> (Fig 2 b) Therapy: emergency surgery
B) NEONATAL CARE INJURY GROUP (n = 11)	
Female term, NICU, 1 st WOL	Incident: nasal probe replacement Diagnosis: <i>(artificial) gastric perforation, (nasal probe feeding)</i> (Fig 2 c) Therapy: open surgical repair.
Male preterm, NICU, 1 st WOL	Incident: umbilical cord bleeding Diagnosis: <i>perumbilical bleeding postoperative, Vit K deficiency, (gastroschisis)</i> (Fig 2 d) Therapy: CPR, revision surgery.
Female term, NHC, 1 st WOL	Incident: traditional healer herbs Diagnosis: <i>caustic soft tissue lesions both heels, (bilateral wounded heels)</i> (Fig 3 a) Therapy: normal saline dressing
Female term, NHC, 2 nd WOL	Incident: hormone-induced hair loss of the mother Diagnosis: <i>hair-thread-toe-tourniquet-syndrome, (strangulated left little toe)</i> (Fig 3 a (inlay)) Therapy: surgical removal.
Female preterm, NICU, 3 rd WOL	Incident: tissueing sodium bicarbonate drip Diagnosis: <i>paravasate left ankle, (small bowel perforations revision surgery)</i> (Fig 3 b) Therapy: Low Level Laser treatment, alginate dressing.
Male preterm, NICU, 3 rd WOL	Incident: tight oxygen saturation monitor clip Diagnosis: <i>pressure-induced subtotal pulp amputation left little finger, (prematurity)</i> (Fig 3 c) Therapy: removal of the clip, hydrocolloid (foil) dressing.
Male term, NHC, 3 rd WOL	Incident: (repetitive) blood gas and electrolytes disturbance, catabolism Diagnosis: <i>marasmus, cachexia, (pspseudohyper-aldosteronism), (st p surgery for pyloric atresia)</i> Therapy: rebalance, to cuddle up.
Male preterm, NICU, 1 st WOL	Incident: iv line attempt during NEC surgery Diagnosis: <i>right distal radius fracture, (NEC, ARDS/lung immaturity)</i> Therapy: closed reduction, POP splinting
Female preterm, NICU, 1 st WOL	Incident: iaaccess attempt Diagnosis: <i>vascular catastrophe right hand and elbow, (left tibia/ankle), (misdiagnosed phlegmone !), (asphyxia, post CPR)</i> (Fig 3 d) Therapy: right hand amputation.
Female preterm, NICU, 1 st WOL	Incident: umbilical cord catheterization Diagnosis: <i>vascular catastrophe right leg-arterial embolism-, (ARDS/lung immaturity, lobular emphysema)</i> (Fig 3 e) Therapy: catheter removal, heparine, hemipelvectomy.
Female term, NICU, 3 rd WOL	Incident: wet cautery neutral electrode Diagnosis: <i>electrical current burn anterior chest, coccygeal teratoma</i> Therapy: sulfadiazine silver crème dressing.

Table 1: A) BIRTH- and B) NEONATAL CARE INJURIES at-a-glance (n = 18). ARDS = Acute Respiratory Distress Syndrome; CPR = Cardio-Pulmonary Resuscitation; C/S = Cesarean Section; DOL= Day Of Life; ICB = IntraCerebral Bleeding; NEC = Necrotizing Enterocolitis; NHC = Neonatal Home Care; NICU = Neonatal Intensive Care Unit; POP = Plaster Of Paris; WOL= Week Of Life.

in this particular group, and the Median time of presentation of incident has been reported to be the 2nd (Range 1-3) day of life. Within this group, 2 complex injuries happened during Caesarean section and 5 during vaginal deliveries. One neonate rushed into surgery, 3 undergone closed bone reduction procedures and the remaining 3 were treated non-surgical.

In contrast, 6 babies in the neonatal care injury group have been identified as preterm while the remaining 5 have been identified as term babies. In this particular group the sex ratio has been stated as 4 males to 7 females, and the Median time of presentation of incident has been reported to be the 1st (Range 1-3) week of life. 8 of the complex injuries happened in the neonatal intensive care unit and 3 in the neonatal home care setting. For their further treatment 5 neonates have to undergo emergency surgery, one closed bone reduction, while the remaining 5 could be treated non-surgical.

Follow-up comprised up to 2 years. Restitutio ad integrum has been reported in all cases with fractured limbs (3 in the birth, 1 in the neonatal care injury-group), the baby with the adrenal gland haemorrhage (birth injury-group) and the baby suffering an electrical current burn preoperatively (neonatal care injury-group) (Figure 2). Good outcomes (accepting slight scarring) could be obtained in the 4 patients out of the neonatal care injury group suffering mainly injuries related to their integument (paravasate, irritation by caustic herbs, hair-thread-toe-tourniquet-syndrome and subtotal pulp amputation) (Figure 3). But not exclusively, since good outcomes could also been

achieved in one of the head injury patients (birth injury group) as well as the patients with metabolic disturbance and stomach perforation out of the neonatal care injury group. One fair result has to be accepted finally in the second head injury patient (birth injury group). In each group the baby with gastroschisis and complicated haemorrhage has been bleeding to death, despite rushing them into emergency surgery (author's remark: no Vit K substitution available at this time). Both babies out of the neonatal care injury group diagnosed with vascular catastrophe have undergone amputation surgery by other surgeons in due course and at different times. The baby with the hand amputation surgery survived after delayed and complicated secondary wound healing. The other baby unfortunately has had a lethal outcome, too (author's remark: no adequate fibrinolytic or antithrombotic medication available at this time).

Discussion

Injuries happening to a newborn baby during delivery and the entire birth process are usually classified under birth or perinatal trauma in medical literature [1-3]. In a report of the American Joint Commission on Accreditation of Healthcare Organizations the general importance of recognition of such birth trauma in clinical practice for all neonate and infant health care providers is clearly demonstrated. Especially according to the fact, that birth trauma occurs in 2 to 7 % of all deliveries, and that it is usually associated with an increase in both, mortality and morbidity [4].

This is in coincidence with a most recent historical correspondence found in the British Medical Journal stating that birth and postnatal trauma has already been recognized to be responsible for the high mortality and morbidity rates found at that time. With postnatal trauma numbers being three times higher, if compared to the classical birth trauma itself [5].

In general, morbidity and mortality as illustrated by the residuals of trauma already received during birth and the postnatal period could have the potential to be incorrectly interpreted as non-accidental trauma/child abuse too, as far as forensic medicine literature is concerned [6]. Thus, a continuous evaluation of actual or already healing residual birth and postnatal injuries is essential, since there is only little knowledge about injuries resulting from accidents (incidental or non-incidental) during the other periods of premobile infant's life as well.

Here postal questionnaire data analysis regarding young infants until 6 months of age revealed, that falls are common and burns are rare. In the majority these injuries have been reported as non-visible injuries; with falls being predominantly trivial and almost entirely confined to the head. They are unlikely to result in a skull fracture. Burns have been caused mostly by contact with radiators or cookers, scalds by hot drinks or water. More serious injuries could be observed only after more complex accidents [7].

According to Papanaglotou [2], birth trauma alone is responsible for less than 2 % of all neonatal deaths, after mortality caused by birth trauma dropped by 88 % in the 1970s and mid 1980s due to the technical progress made in obstetrics at that time. Namely, by identification of high risk deliveries by fetal and perinatal ultrasound prior to labour, the use of less harmful obstetrical instruments and techniques and last but not least Cesarean sections becoming more and more accepted.

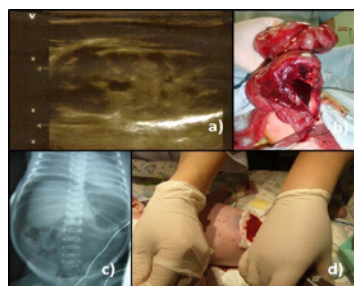

Figure 2: a) Adrenal gland haemorrhage b) Gastroschisis, small bowel surface tearing c) (artificial) Gastric perforation d) Gastroschisis, perumbilical bleeding postoperative.

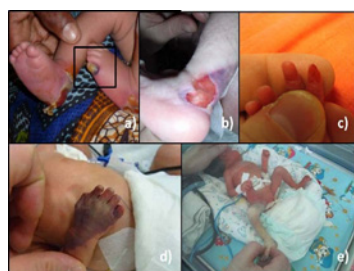

Figure 3: a) Caustic soft tissue lesions both heels (inlay: hair-thread-toe-tourniquet-syndrome) b) (sodium bicarbonate) paravasate left ankle c) (pressure-induced) subtotal pulp amputation left little finger d) Vascular catastrophe hand and elbow vascular catastrophe -arterial embolism-lower extremity.

If signs of trauma like “cerebral damage” or “cerebral disturbance” have been present after birth, hypoxia during birth or birth asphyxia has mostly likely been the cause. Quite often this asphyxia is the result of prolonged labour, midforceps or breech delivery in full term infants, abruption placenta, maternal sedation in premature infants or unattended precipitate deliveries in immature infants, but not exclusively. However, hypoxia during birth or birth asphyxia is usually not recognized as a birth injury per se [1,2,8,9].

Fetal distress due to hypoxia may be succeeded by petechial subarachnoid and intracerebral hemorrhage in due course. Intraventricular hemorrhage occurs in preterm infants, especially in those with respiratory distress syndrome, and is considered as a common cause of death in this specific group of patients [1,2,8].

Common birth injuries of the head include caput succedaneum, cephal or subgaleal hematoma and minor intracranial hemorrhage due to the mechanical traction or compression forces during delivery. Usually none of them require any further attention, since they are expected to heal or disappear within the first weeks of life without any further sequelae [1,2].

In comparison to childhood and adolescence skull fractures following head injuries occur more frequently during infancy. The still flexible bones and open sutures of the neonate's skull explain the main characteristics of such fractures and their incidence best. They could happen either during vaginal (forceps) or Caesarean section delivery. Usually, the presence of a simple (linear) skull fracture alone require little or even no further medical attention, especially in neonates and early infancy. But nevertheless, the correct initial clinical evaluation and diagnosis are crucial, since infants with significant head injury are always at a greater risk for major complications and sequelae [8]. Thus, an impressive but rather simple lesion like a cephalic hematoma should not draw off our attention from serious (biparietal) skull fractures or intracerebral bleeding, maybe already complicated by fits.

Regarding the skeleton a fractured clavicle is the most common birth injury in the neonate [1,3]. Usually it does not need any specific treatment at all [10].

With a reported incidence of 0.09/1000 births the fractured humerus is the most common long bone fracture in the neonate, indeed. The fracture sites are distributed equally on each third of the humerus, with equal gender distribution, but a predominance for the right side [11]. In the majority of cases diagnosis is made during their first day of life [11], either by X-ray or ultrasound scan [1,11]. Despite the fact, that a Cesarean section is usually considered to be the safer mode regarding limb extraction, quite surprisingly a significant number of humerus fractures are reported to happen during Cesarean in comparison to vaginal delivery as well [11,12]. The regular treatment consists of splinting the arm to the infant's body with a crepe bandage until bony reunion occurs [1,13].

Another rare birth injury, that is often considered as a specific type of humerus fracture is the slipped humerus epiphysis. Frequently, this diagnosis is missed and the neonate is admitted quite late. But nevertheless, immediate and competent paediatric orthopaedic treatment is needed to avoid life-long sequelae [14-16].

Any deficit in spontaneous movement, any pathological neurological finding or absent reflexe on the upper extremity could be an indicator for a birth injury to the brachial plexus. Frequently, such a lesion is associated with a humerus or clavicular fracture already mentioned above. Any injuries to the brachial plexus, either single or

in combination should be seen by the paediatric (orthopaedic) surgeon and undergo at least physiotherapy [1].

Other complex skeletal birth or neonatal care injuries to mention are rib fractures (under resuscitation) [16,17], respectively forearm fractures due to difficult iv-line access or other carer procedures. Potential metabolic bone disorders (i.e. rickets, is ontogenesis imperfect) bone fragility and child abuse have to be excluded as differential diagnosis [16].

Other authors reported about birth-associated femur fractures happening either during Caesarean section or vaginal delivery, but also during neonatal care. In the latter bone fragility or child abuse has to be considered as a cause [16,18-21,]. Splinting until bony reunion occurs is considered as the appropriate treatment in the majority of cases [18-21].

However, any fracture of a long bone of an otherwise healthy neonate is a rare complication of delivery, regardless of by Caesarean or by vaginal delivery, and should alert any obstetrician or neonatal carer to avoid any potential risk for a fracture either during limb extraction, or during positioning, anyway.

Hematoma, edema or superficial bruises are the most common skin and soft tissue lesions found in the newborn baby suffering a birth- or neonatal care injury to the integument [1-3]. Since the skin of the neonate is very sensitive to pressure, the resulting subcutaneous fat necrosis will produce a firm subcutaneous area at the pressure site, especially in birth injuries when an obstetrical forceps has been used too tightly. The area might be red and tender, but usually no further specific treatment is needed. If the lesion is in an unusual location and the swelling not noticed for several days after birth, the area of necrosis might be misdiagnosed as a pyogenic abscess [1].

But definitive tissue necrosis in neonatal care can even start from a too tight monitor clip measuring oxygen saturation resulting in a subtotal finger pulp amputation. Or the tissue necrosis followed caustic skin burns, induced by the incorrect use of a traditional healer's herbs. Respectively, by a faulty electrical current burn caused intraoperatively by the neutral diathermy electrode after violation of patient's safety rules. Or, tissue necrosis followed a tissueing sodium bicarbonate drip set up in the intensive care unit to correct pH in metabolic acidosis after neonatal surgery. Treatment has been by normal saline washouts, hydrocolloid dressings and Low Level Laser therapy if indicated [12,22-24].

In the hair-thread-toe-tourniquet-syndrome the tissue necrosis is caused by strangulation of the infant's toe by accidentally wrapped around hair of the mother. This excessive hair loss of the mother is hormone-related after giving birth. A hair-thread-toe-tourniquet-syndrome requires immediate surgical intervention to save the infant's toe [25].

Multiple repeated attempts for an arterial (to some extent venous) access, either peripheral or central, can lead to a vascular catastrophe like thromboembolism, vasospasm, vessel perforation, hemorrhage, or infection and tissue damage among others. Despite such catheters are routinely used for the critically ill newborn now for quite a long time [26-31]. Additional risk factors include maternal lupus or diabetes, birth asphyxia, neonatal polycythemia or elevated hematocrit, sepsis, poor cardiac output, and dehydration [26,30,31]. Complications related to catheters like this can occur during any phase of treatment: insertion, while indwelling, or even after the catheter has been discontinued already. Neonatal caregivers should be aware of this and monitor carefully for associated complications at all time [26-29].

Thrombosis in neonates is rare but associated with a high morbidity [26-31]. According to a Canadian registry report, the overall incidence of symptomatic neonatal thromboembolism is as high as 2.4 per 1,000 neonatal intensive care unit admissions [30]. Other authors reported the incidence of a symptomatic neonatal thromboembolism to be 0.5 per 10,000 live births, respectively [26, 31]. The venous and arterial systems are equally involved [30]. The incidence of thromboembolism related to an umbilical artery catheter is reported to be 1-3 % based on clinical signs alone, 14-35 % if investigated by Doppler ultrasound, and 64 % with angiographic confirmation [26].

In general, neonates have a different availability and concentration of coagulation and fibrinolytic components compared with older children and adults. Due to these differences in the hemostatic system, newborns are at increased risk of both bleeding and thrombotic complications in comparison with older children or adults [26,30,31].

So far only single case reports about such vascular catastrophes could be found in literature review [26, 31-33], like ieperinatal compartment syndrome [32,33], or a large left subclavian-axillary-brachial artery thrombosis with regard to the upper extremity [26]. Respectively, a vascular catastrophe mimicking a dry gangrene ending up in an amputation like in our case. Regarding the lower extremity, a premature male suffered an arterial thrombosis of the right pelvis axis similar to our case report. In his case a single umbilical artery and hypoplastic appearing iliac arteries have been identified antenatally, a prothrombin G 2021A mutation postnatally, but no attempt to puncture the umbilical or femoral vessels has been undertaken at any time [31].

As already mentioned, every neonatal thromboembolism requires urgent intervention to restore perfusion and to avoid morbidity and mortality. But treatment of neonatal thromboembolism is difficult. However, immediate removal of the (arterial) catheter is almost always indicated and performed. Surgical thrombectomy is rarely an option in neonates due to the small size of their blood vessels and the clinical instability at presentation. Severe symptomatic thromboembolism therefore is typically treated with anticoagulants and/or thrombolytic agents, especially if thrombi are thought to be threatening to life, limb, or organs. But since there are major side effects and complications (ie cerebral bleeding) the administration of these agents need to be considered seriously [26,31].

Due to the differences in their hemostatic system newborns, next to their potential thromboembolic complications are at an increased risk of massive bleeding, too [26,30,31]. Therefore, any birth- or neonatal care injury causing visceral hemorrhage or damage will be of major concern as well.

The diagnosis of the birth injury "ruptured spleen after difficult delivery" is quite popular in the literature. An injury that could either happen to enlarged or normal spleens, either during vaginal or Caesarean deliveries. The onset of symptoms is variable, but usually symptoms occur within the first 24 hours of life, right before the full-blown classical picture evolves. Coagulation disorders, vascular malformations or hemangiomas are reported to be another cause for splenic hemorrhage as well [34-38]. Spleen sparing procedures are found (sparse) in the literature [39,40], and in one of the authors' former affiliate a record of a neonate with a traumatic splenic rupture after Caesarian section and spleen sparing therapy has been identified, too.

The prenatal diagnosis of an abdominal wall defect of the fetus like gastroschisis or omphalocele has led some obstetricians to advocate elective Caesarian delivery in all mothers carrying a fetus with

this known ventral wall defect. Their belief is that Cesarean delivery protects the abdominal viscera from birth trauma (tearing and avulsion injuries) and ischemia, prevents exposure of the uncovered viscera to the bacterial flora of the vagina, and removes the likelihood of birth dystocia caused by the exteriorized bowel. But finally both studies concluded, that fetuses with an antenatal diagnosis of an isolated ventral wall defect may safely be delivered vaginally, thus eliminating the need for an elective Cesarean delivery as well as the resultant maternal morbidity and mortality [41,42].

But despite ongoing advances in the care of neonates with ventral abdominal wall defects, these patients still present with significant morbidity [43], and mortality rates of 29 % for omphalocele and 13.5 % for gastroschisis, respectively [41]. Here especially preterm babies with gastroschisis have been identified to have a 14 times higher risk for any of the recorded morbidities if compared to their term counterparts. Namely, sepsis, longer duration to reach full enteral feedings and longer length of hospital stay as well as failure to thrive at discharge and greater drop in weight percentile during hospitalization. Elective preterm delivery of neonates with gastroschisis is often advocated in order to avoid the intestinal damage that may be sustained with prolonged exposure to the amniotic fluid. But preterm delivery may impose additional morbidities to this disease process on the other hand as well. Thus, since there has been no clear benefit to the gut in avoiding derivative injuries found in this study, it has been concluded, that preterm delivery should be better avoided [43]. In our case series preterm and term vaginal and Cesarean deliveries have been found equally.

Gastric perforation among neonates is a rare but frequently fatal condition of uncertain etiology. In the majority historical reports described gastric perforation in the neonatal population as "spontaneous", until more recently, several variables including prematurity and nasal ventilation, sepsis or corticosteroid treatment have been implicated as contributing factors, too [44-46]. Recommended treatment consists out of emergency surgery with primary repair of the gastric wall, usually followed by a prompt and fast recovery. Since early diagnosis and prompt management before clinical deterioration occurs improve outcome of these patients, markedly [44-46].

Hyponatremia is a very rare but always serious condition in newborns, that might occur even long time after birth. Then, according to an American study, breast milk despite standard fortification might contain an insufficient quantity of sodium to meet the needs of very low birth weight infants [47]. In our report a (term) baby presented from home with an extreme life-threatening hyponatremia after an initially uneventful recovery from his pyloric atresia surgery on his first days of life. During short term follow-up the baby had to be readmitted with repeated episodes of hyponatremia. Final lab results for suspected pseudohyperaldosteronism are still inconclusive.

Conclusion

Birth- and Neonatal Care injuries in general present as a very special and delicate aspect of newborn surgery. They are supposed to happen more frequently during complex deliveries like Cesarean section or in the NICU setting, however they do happen during routine deliveries or neonatal home care as well. For their successful management great expertise and empathy is needed by every individual carer in charge.

Conflicts of Interest

No conflict of interest or any source of funding must be declared by the author.

References

1. Valman HB (1979) Birth Trauma. *British Medical Journal* 15: 1566-1567.
2. Papanaglotou P, Rohrer T, Roth C, Politi M, Zimmer A, et al. (2009) Kraniales Geburtstrauma. *Radiologe* 49: 913-917.
3. Uhing MR (2004) Management of birth injuries. *Pediatr Clin North Am* 51: 1169-1186.
4. Parker LA (2005) Part 1: Early recognition and treatment of birth trauma: injuries to the head and face. *Adv Neonatal Care* 5: 288-297.
5. Haas L (1965) Injured Baby. *BMJ correspondance*: 645.
6. Patonay BC, Oliver WR (2010) Can birth trauma be confused for abuse? *J Forensic Sci* 55: 1123-1125.
7. Warrington SA, Wright CM, ALSPAC Study Team (2001) Accidents and resulting injuries in premobile infants: data from the ALSPAC study. *Arch Dis Child* 85: 104-107.
8. Raimondi AJ, Choux M, Di Rocco C (1980) Head Injuries in the Newborn and Infant. New York: Springer, ISBN 0-387-96208-5.
9. O'Brien JR, Usher RH, Maughan GB (1966) Causes of Birth Asphyxia and Trauma. *Can Med Assoc J* 94: 1077-1085.
10. Blab E, Geissler W, Rokitansky A (1999) Sonographic management of infantile clavicular fractures. *Pediatr Surg Int* 15: 251-254.
11. Sherr-Lurie N, Bialik GM, Ganel A, Schindler A and Givon U (2011) Fractures of the humerus in the neonatal period. *Isr Med Assoc J* 13: 363-365.
12. Sadoh AE, Ogungbe RO (2008) Multiple fractures and iatrogenic burns in a newborn due to unskilled delivery: a case report. *Afr J Reprod Health* 12: 197-206.
13. Riebel T, Nasir R (1995) Ultrasound of extremity lesions caused by birth trauma. *Ultraschall Med* 16: 196-199.
14. Princic J, Tonin M, Ales A (1995) Birth trauma as the cause of fracture of the distal epiphysis of the humerus. A case report. *Unfallchirurg* 98: 487-488.
15. Fette A, Mayr J (2008) Neonatal distal humerus epiphysiolysis. A rare obstetrical injury easily detected by ultrasound. *Arch Dis Child* 93: Suppl I/I.
16. Dwek JR (2011) The Radiographic Approach To Child Abuse. *Clin Orthop Relat Res* 469: 776-789.
17. Bulloch B, Schubert CJ, Brophy PD, Johnson N, Reed MH, et al. (2000) Cause and clinical characteristics of rib fractures in infants. *Pediatrics* 105: E48.
18. Morris S, Cassidy N, Stephens M, McCormack D, McManus F (2002) Birth-associated femoral fractures: incidence and outcome. *J Pediatr Orthop* 22: 27-30.
19. Cebesoy FB, Ceseboy O, Incebiyik A (2009) Bilateral femur fracture in a newborn: an extreme complication of cesarean delivery. *Arch Gynecol Obstet* 279: 73-74.
20. Rijal L, Ansari T, Trikha V, Yadhav CS (2009) Birth injuries in Caesarian sections: cases of fracture femur and humerus following Caesarian section. *Nepal Med Coll J* 11: 207-208.
21. Al-Habdan I (2003) Birth-related fractures of long bones. *Indian J Pediatr* 70: 959-960.
22. Fette A (2004) Softlaserbehandlung eines Bikarbonat-Gewebeparavasates bei einem Frühgeborenen. *Laser Journal, Zeitschrift für innovative Lasermedizin, Oemus Media AG, Leipzig* 7. Jahrgang, Heft 2: 20-21.
23. Martin PH, Carver N, Petros AJ (1994) Use of liposuction and saline washout for the treatment of extensive subcutaneous extravasation of corrosive drugs. *Br J Anaesth* 72: 702-704.
24. Brown AS, Hoelzer DJ, Piercy SA (1979) Skin necrosis from extravasation of intravenous fluids in children. *Plast Reconstr Surg* 64: 145-150.
25. Fette A (2005) Unfall oder Kindesmisshandlung? Das Haarschnürringsyndrom als "übersehener" Kindertotfall. *Rettungsdienst* 3: 74-75.
26. Aslam M, Guglietti D, Hansen AR (2008) Neonatal Arterial Thrombosis at Birth: Case Report and literature review. *Am J Perinatol* 25: 347-352.
27. Green C, Yohannan MD (1998) Umbilical arterial and venous catheters: placement, use, and complications. *Neonatal Netw* 17: 23-28.

28. Bradshaw WT, Furdon SA (2006) A nurse's guide to early detection of umbilical venous catheter complications in infants. *Adv Neonatal Care* Jun 6: 127-138.
29. Furdon SA, Horgan MJ, Bradshaw WT, Clark DA (2006) Nurses' guide to early detection of umbilical arterial catheter complications in infants. *Adv Neonatal Care* 6: 242-256.
30. Narang S, Roy J, Stevens TP, Butler-O'Hara M, Mullen CA, et al. (2009) Risk Factors for Umbilical Venous Catheter-Associated Thrombosis in Very Low Birth Weight Infants. *Pediatr Blood Cancer* 52: 75-79.
31. Haase R, Kunze C, Nagel F, Merkel N, Burdach S, et al. (2004) Thrombosis of the iliac artery in a premature neonate: Thrombolytic Therapy using rt-PA. *Z Geburtshilfe Neonatol* 208: 36-41.
32. Ragland R 3rd, Moukoko D, Ezaki M, Carter PR, Mills J (2005) Forearm Compartment Syndrome in the Newborn. Report of 24 cases. *J Hand Surg* 30: 997-1003.
33. Landi A, Abate M (2010) The Perinatal Compartment Syndrome. In MS Chung, GH BAEKeds(2010) *Hand Surgery 2010 IFSSH*. Seoul, Korea: HS Gong Konnja Publishing: ISBN 978-89-6278-331-5, 303-305.
34. Hui CM Tsui KY (2002) Splenic rupture in a newborn. *J Pediatr Surg* 37: E3.
35. Bickler S, Ramachandran V, Gittes GK, Alonso M, Snyder CL (2000) Nonoperative management of newborn splenic injury: a case report. *J Pediatr Surg* 35: 500-501.
36. Parker LA (2006) Part 2: Birth trauma: injuries to the intraabdominal organs, peripheral nerves, and skeletal system. *Adv Neonatal Care* 6: 7-14.
37. Sokol DM, Tompkins D, Izant Jr RJ (1974) Rupture of the spleen and liver in the newborn: a report of the first survivor and a review of the literature. *J Pediatr Surg* 9: 227-229.
38. Traggis DG, Maunz DL, Baroudy R (1984) Splenic hemorrhage in a neonate of a mother on anticonvulsant therapy. *J Pediatr Surg* 19: 598-599.
39. Fasoli L, Bettili G, Bianchi S, Dal Moro A, Ottolenghi A (1998) Spleen rupture in the newborn: conservative surgical treatment using absorbable mesh. *J Trauma* 45: 642-643.
40. Driscoll K, Benjamin LC, Gilbert JC et al.(2004) Non-operative management of neonatal splenic rupture. *Am Surg* 70: 1085-1087.
41. Kirk EP, Wah RM (1983) Obstetric management of the fetus with omphalocele or gastroschisis: a review and report of one hundred twelve cases. *Am J Obstet Gynecol* 146: 512-518.
42. How HY, Harris BJ, Pietrantonio M, Evans JC, Dutton St, et al. (2000) Is vaginal delivery preferable to elective Cesarean delivery in fetuses with a known ventral wall defect? *Am J Obstet Gynecol* 182: 1527-1534.
43. Maramreddy H, Fisher J, Slim M, LaGamma EF, Parvez B (2009) Delivery of gastroschisis patients before 37 weeks of gestation is associated with increased morbidities. *J Pediatr Surg* 44: 1360-1366.
44. Lin CM, Lee HC, Kao HA, Hung HY, Hsu CH, et al. (2008) Neonatal gastric perforation: report of 15 cases and review of the literature. *Pediatr Neonatol* 49: 65-70.
45. Leone RJ jr, Krasna IH (2000) Spontaneous neonatal gastric perforation: Is it really spontaneous?? *J Pediatr Surg* 35:1066-1069.
46. Oztürk H, Onen A, Otcu S, Dokucu AI, Gedik S (2003) Gastric perforation in neonates: analysis of five cases. *Acta Gastroenterol Belg* 66: 271-273.
47. Kloiber LL, Winn NJ, Shaffer SG, Hassanein RS (1996) Late hyponatremia in very-low-birth-weight infants: incidence and associated risk factors. *J Am Diet Assoc* 96: 880-884.