

# Autologous Serum Eye Drop in Refractory Neurotrophic Corneal Ulcer: A Case Report

Poonam Lavaju<sup>1\*</sup>, Sangeeta Shah<sup>1</sup>, Icchya Joshi<sup>2</sup> and Aashish Raj Pant<sup>3</sup>

<sup>1</sup>Department of Ophthalmology, BP Koiral Institute of Health Sciences, Dharan, Nepal

<sup>2</sup>Biratnagar Eye Hospital, Biratnagar, Nepal

<sup>3</sup>Mechi Eye Hospital, Mechi, Nepal

\*Corresponding author: Poonam Lavaju, Department of Ophthalmology, BP Koirala Institute of Health sciences, Dharan, Nepal, Tel: 00977-9852047026; E-mail: drpoonamlavaju@yahoo.com

Received date: March 30, 2017; Accepted date: April 17, 2017; Published date: April 29, 2017

Copyright: ©2017 Lavaju P, et al. This is an open-access article distributed under the terms of the Creative Commons Attribution License, which permits unrestricted use, distribution, and reproduction in any medium, provided the original author and source are credited.

## Abstract

**Purpose:** To report a case of refractive neurotrophic corneal ulcer, treated successfully with 20% autologous serum eye drops.

**Case Report:** A 20 year old male presented with redness and foreign body sensation since three months associated with photophobia and progressive diminution of vision of both the eyes, right eye more than left, since 2 months. At presentation, the best corrected visual acuity in the right eye was 1/60 and left 6/12. Right eye showed ciliary congestion and epithelial defect of 4.5 × 1.5 mm with thinning (~80%). Left eye had diffuse superficial keratopathy with paracentral nebular corneal opacity. Corneal sensation was decreased with schirmer's test I reading of 1 mm in both the eyes. With the provisional diagnosis of refractory neurotrophic corneal ulcer, 20% autologous serum eye drops was started in the right eye four hourly along with topical preservative free tear substitutes. After one week, there was dramatic improvement in the right eye with healed cornea and decrease in thinning.

**Conclusion:** Autologous serum eye drops is beneficial in the treatment of neurotrophic corneal ulcer and can prevent further complications.

**Keywords:** Neurotrophic keratopathy; Autologous serum; Corneal ulcer; Persistent epithelial defect

## Introduction

Neurotrophic keratopathy (NK) is a rare degenerative corneal disease caused by an impairment of trigeminal corneal innervations, leading to a decrease or absence of corneal sensation, impaired healing, persistent epithelial defect and neurotrophic ulcers [1,2]. It is associated with many ocular and systemic diseases. Management of NK is challenging. Meticulous management is necessary to halt its progression and prevent corneal complications such as melting and perforation. Many modalities have been stated in the literature for the treatment of neurotrophic corneal ulcer.

Here in, we report a case of NK, refractive to conservative treatment which was treated successfully with 20% autologous serum eye drops.

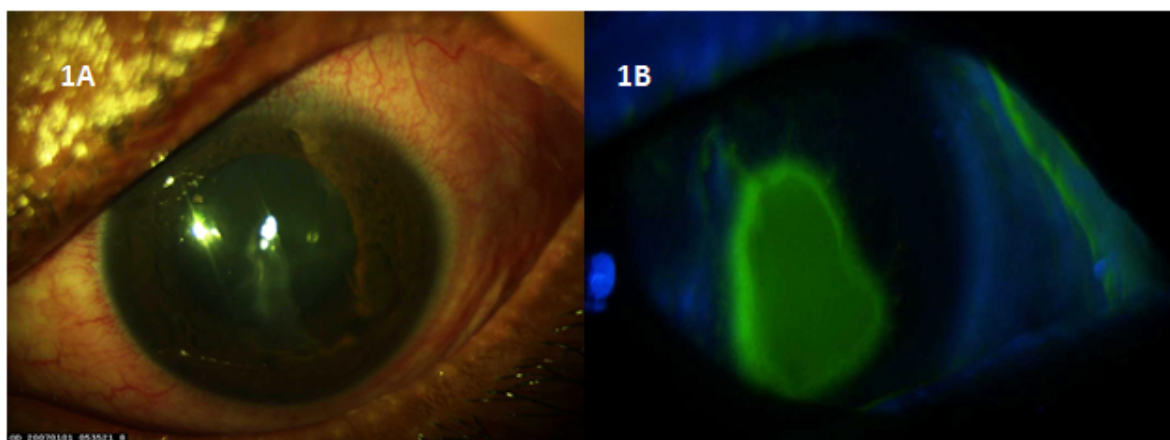
## Case Report

A 20-year-old-male presented with pain, redness, gritty sensation and diminution of vision in both the eyes for three months, right eye more than the left. He was getting treatment from outside with topical steroid eye drops (1% prednisolone eye drops) in tapering dose and

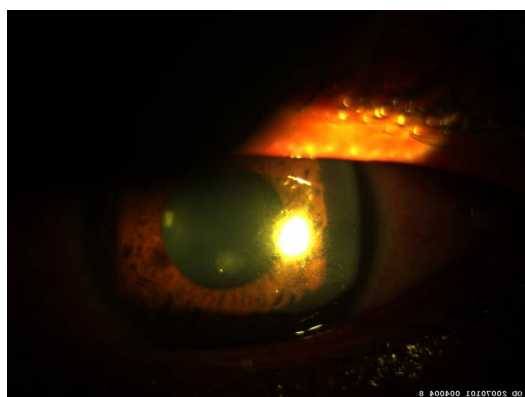
antibiotic eye drops four times a day with no improvement in signs and symptoms. He gave history of recurrent mouth ulcers. There was no significant past history.

At presentation, best corrected visual acuity, was 1/60 in the right eye (RE) and 6/12 in the left. Blepharospasm was present in the both eyes (OU). Upper lid examination showed posterior blepharitis with thickening of the eyelid margins and keratinization, bilateral conjunctival xerosis and diffuse ciliary congestion OU.

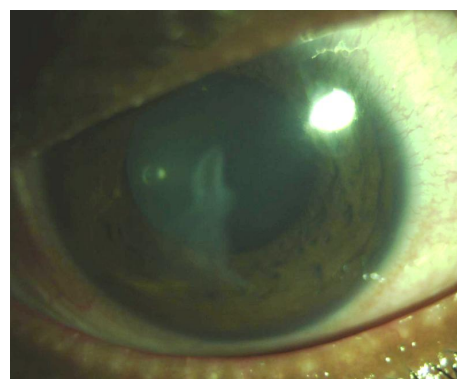
Right eye examination revealed, ciliary congestion, epithelial defect of 4.5 × 2 mm with rolled out margins and thinning of approximately 80% (Stage 2 NK according to Mackie classification) [3] with diffuse superficial punctate epithelial keratopathy (SPKs) (Figures 1A and 1B). In the left eye, cornea showed diffuse SPKs with nebular corneal opacity in the paracentral area (Figure 2). Corneal sensitivity test with a wisp of cotton was found to be decreased in both the eyes (OU). Schirmer's tear test value was 1 mm (OU) at 5 minutes. Intraocular pressure in the right eye was digitally normal and in the left 15 mm Hg (Goldmann applanation tonometer). Rest of the ocular examinations was within normal limits. Laboratory examination; complete blood count: normal, rheumatoid factor: <12 IU/ml, HIV, Hbs Ag, HCV: negative. Conjunctival biopsy showed presence of inflammatory cells with absence of goblet cells. Buccal mucosa biopsy was normal.



**Figure 1:** Slit lamp findings. A: showing epithelial defect with rolled out margins and thinning. B: epithelial defect stained with 20% fluorescein dye.



**Figure 2:** Left eye showing nebular corneal opacity.



**Figure 3:** After three months of treatment, the epithelial defect healed with corneal scarring.

With the presumed diagnosis of NK and as the patient was refractive to topical steroids and 0.1% cyclosporine eye drops; was commenced on 20% autologous serum eye drop diluted in preservative free tear substitute four times a day in the right eye and tear substitutes in the left. He was also prescribed oral doxycycline 100 mg twice a day. With the initiation of this treatment there was a dramatic improvement in the signs and symptoms in the right eye. At three months follow up, patient was asymptomatic with decrease in corneal thinning and residual corneal scarring in the right eye (Figure 3). Left eye cornea was clear except had nebular corneal opacity in the paracentral area.

## Discussion

Neurotrophic corneal ulcer (NK) is an ocular surface disease induced by decrease or absence of corneal sensation [4]. Although several modalities of treatment both medical and surgical have been reported in the literature for the treatment of NK, its management is still a biggest challenge for any ophthalmologist. The goals of treatment are to suppress inflammation, to promote epithelial healing and prevent progression of the disease to stromal melting and perforation [5].

Many modalities of treatment like use of topical steroids, immunosuppressive drugs, amniotic membrane transplantation [1,3,5], thymosin beta 4 [6], fibronectin [7,8] and substance P [9] have been reported in the literature.

Recently autologous serum (AS) have proven in management of many ocular surface disorders like persistent epithelial defect, peripheral ulcerative keratitis, mooren's ulcer, dry eye, NK, vernal keratoconjunctivitis including neurotrophic corneal ulcer.

Autologous serum contains some of the factors that are necessary for proliferation, migration and maturation of corneal epithelial cells. Significantly increased concentrations of nerve growth factor, insulin-like growth factor and substance P were noted in the serum tears that were not found in the patient's normal tear samples. It harbors neurotrophic factors and may provide neurologic healers for a compromised ocular surface [5,6].

Matsumoto et al. reported the effectiveness of the treatment of 14 eyes of 11 patients with NK with application of 20% autologous serum five to ten times a day [5]. There was improving in epithelization with improvement in best corrected visual acuity in 78.6%. Poon et al. used 20% AS in four eyes with NK and it proved effective in two eyes [10]. Turkoglu et al did a study to comparative the efficacy of autologous serum eye drops with amniotic membrane transplantation in NK; found that both the treatment were effective for eyes with NK [4].

Though we were not able to perform laboratory investigations to prove viral etiology, decreased corneal sensation and presence of nebular corneal opacities could justify that the pathophysiology of NK could be secondary to herpetic keratitis. With the initiation of 20% autologous serum eye drop dramatic response was seen, with healed epithelial defect and decreased thinning. Some authors have stated that use of oral tetracycline 250 mg b.d or doxycycline 100 mg every other day can speed up corneal healing by combining with the antibiotic therapy with matrix metalloproteinase inhibitors [11].

This case shows that meticulous examination, early diagnosis and treatment of NK can prevent corneal complications such as scarring and perforation. Use of autologous serum eye drops has a promising result in NK cases refractive to conservative therapy, avoiding need for surgical interventions.

## Conclusion

Management of refractory neurotrophic corneal ulcer is a challenging. Autologous serum eye drops is promising in treatment of neurotrophic corneal ulcer refractive to conservative and immunosuppressive therapy.

## References

1. Khokhar S, Natung T, Sony P, Sharma N, Agrawal N, et al. (2005) Amniotic membrane transplantation in refractory neurotrophic corneal ulcers. *Cornea* 24: 654-660.
2. Chen HJ, Pires R, Tseng S (2000) Amniotic membrane transplantation for severe neurotrophic corneal ulcers. *Br J Ophthalmol* 84: 826-833.
3. Mackie IA (1995) Neuroparalytic keratitis. In: Fraunfelder F, Roy FH, Meyer SM, editors. *Current Ocular Therapy*. WB Saunders, Philadelphia, PA, USA.
4. Turkoglu E, Celik E, Alagoz G (2014) Comparison of the efficacy of autologous serum eye drops with amniotic membrane transplantation in neurotrophic keratitis. *Seminars in Ophthalmology* 29: 119-126A.
5. Matsumoto Y, Dogru M, Goto E, Ohashi Y, Kojima T, et al. (2004) Autologous serum application in the treatment of neurotrophic keratopathy. *Ophthalmology* 111: 1115-1120.
6. Dunn S, Heidemann D, Chow C, Crockford D, Turjman N (2010) Treatment of chronic nonhealing neurotrophic corneal epithelial defects with thymosin beta 4. *Arch Ophthalmol* 128: 636-638.
7. Nishida T, Ohashi Y, Awata T, Manabe R (1983) Fibronectin. A new therapy for corneal trophic ulcer. *Arch Ophthalmol* 101: 1046-1048.
8. Phan TM, Foster CS, Boruchoff SA, Zaqachin LM, Colvin RB (1987) Topical fibronectin in the treatment of persistent corneal epithelial defects and trophic ulcers. *Am J Ophthalmol* 104: 494-501.
9. Brown SM, Lamberts DW, Reid TW, Nishida T, Murphy CJ (1997) Neurotrophic and anhidrotic keratopathy treated with substance P and insulin like growth factor 1. *Arch Ophthalmol* 115: 926-927.
10. Poon AC, Geerling G, Dart JK, Fraenkel GE, Daniels JT (2001) Autologous serum eye drops for dry eyes and epithelial defects: Clinical and in vitro toxicity studies. *Br J Ophthalmol* 85: 1188-1197.
11. Brooks DE, Ollivier FJ (2004) Matrix metalloproteinase inhibition in corneal ulceration. *Vet Clin North Am Small Anim Pract* 34: 611-622.