

## Arthroscopic-Assisted Anterior Cruciate Ligament Reconstruction Using Hamstring Autograft Augmented with a Dehydrated Human Amnion/Chorion Membrane Allograft: A Retrospective Case Report

Gary A Levengood\*

Sports Medicine South, Lawrenceville, USA

\*Corresponding author: Gary A. Levengood, MD, Sports Medicine South, 1900 Riverside Parkway, Lawrenceville, GA 30043, USA, Tel: 770-237-3475, Fax: 770-237-3475; E-mail: [Levenacl@gmail.com](mailto:Levenacl@gmail.com)

Received date: May 02, 2016; Accepted date: May 20, 2016; Published date: May 27, 2016

Copyright: © 2016 Levengood GA. This is an open-access article distributed under the terms of the Creative Commons Attribution License, which permits unrestricted use, distribution and reproduction in any medium, provided the original author and source are credited.

### Abstract

Anterior Cruciate Ligament (ACL) rupture is a very common sports related knee injury. Surgical reconstruction using either autograft or allograft is the gold-standard treatment for a ruptured ACL. Presented is a case of a 23-year old female skier with a Magnetic Resonance Imaging (MRI) confirmed primary ACL tear that underwent an arthroscopic-assisted ACL reconstruction using a quadruple-stranded hamstring autograft augmented with a Dehydrated Human Amnion/Chorion Membrane (dHACM) allograft patch. Post-operative follow-up MRI scans at three and six months show early vascularization and maturation of the hamstring graft. Additionally, the patient's rehabilitation progressed at an accelerated timeline with regards to strength and proprioception with subsequent clearance to return to play at 8 months post-op.

**Keywords:** ACL reconstruction; Amniotic membrane; Hamstring autograft

### Introduction

There are over 80,000 primary Anterior Cruciate Ligament (ACL) reconstructions performed in the United States annually [1]. For many patients with Anterior Cruciate Ligament (ACL) rupture the primary treatment goal is rapid return to sports activities at the level experienced pre-injury [2]. ACL reconstruction includes using autografts or allografts, yet there is insufficient evidence to support the use of one graft over another in all circumstances [3]. Autografts have benefits associated with earlier incorporation without risk for rejection or disease transmission, while the benefits of allografts include elimination of donor-site morbidity, availability of multiple grafts, shorter operative times, reduced pain and more rapid rehabilitation [3]. Utilizing other tissue technologies to further enhance intra-articular and intraosseous healing processes in ACL reconstruction may provide for more rapid return to function. With written consent from the patient, this report discusses outcomes of an ACL rupture treated surgically by arthroscopic-assisted reconstruction using a quadruple-stranded hamstring autograft augmented with a Dehydrated Human Amnion/Chorion Membrane (dHACM) (AmnioFix<sup>®</sup>, MiMedx Group, Inc., Marietta, GA) allograft patch.

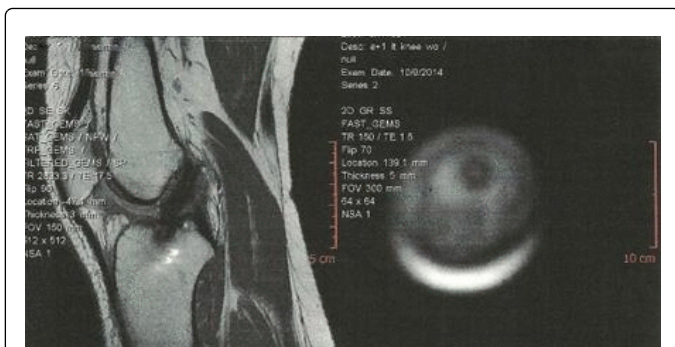
### Case Report

A 23-year old female presented to a sports medicine clinic with left knee pain and swelling. She reportedly injured her knee skiing seven months prior but returned to normal activities upon resolution of initial symptoms. The patient reinjured her knee attending a concert when she felt a "pop" and subsequently noticed knee swelling. Physical examination of the knee revealed moderate effusion and tenderness along the medial joint. Knee was limited in passive and active extension and flexion held at approximately -40° extension. Patient had

a positive anterior drawer test for ACL involvement, positive McMurray medially recreating the pain and no distinct endpoint was noted with Lachmans test. A Magnetic Resonance Imaging (MRI) revealed an acute to sub-acute full thickness tear/rupture of the ACL within its proximal to mid portions with a possible mild grade 1 sprain to the Medial Collateral Ligament (MCL).

Surgical options were discussed to repair the complete ACL tear. The patient elected to have arthroscopic-assisted ACL reconstruction technique using quadruple-stranded hamstring autograft augmented with a dHACM allograft patch fixated using the Tape Locking Screw (TLS<sup>®</sup>) technique. The hamstring autograft was harvested from semitendinosus and gracilis muscles. The two strands were wrapped in dHACM and rolled around two posts to form a four-strand closed loop with TLS<sup>®</sup> strips passed through two ends of the tendon loops. An arthroscope was placed infrapatellar laterally. Visualization of the ACL tear was noted, the Posterior Cruciate Ligament (PCL) was intact. The K-wire was placed at 2 o'clock position and overreamed to a depth of 10 mm. The footprint of the ACL was overreamed to a depth of 9 mm. The graft was passed through the medial port and the tape was pulled through the femur and secured using a 10x20 TLS<sup>®</sup> interference screw. The remaining portion of the graft was pulled through the socket on the tibial site and secured in place using a 10x25 TLS<sup>®</sup> interference screw.

Post-operatively, physical therapy for strength and flexibility with agility/proprioception testing was ordered. MRI scans were gathered at three months (Figure 1) and six months (Figure 2) to assess the ACL graft healing and maturation. MRI scans of the ACL reconstructed knee at three months shows increased dark signal compatible with early vascularization and maturation of the autograft with continued maturation shown in the six month scan.



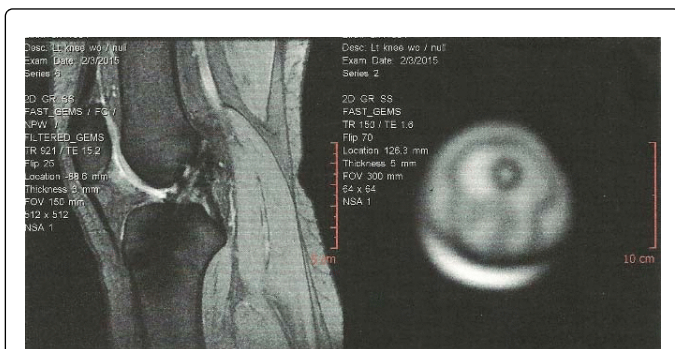
**Figure 1:** Post-op MRI at three months showing increased dark signal compatible with early vascularization and maturation of the autograft.

Rehabilitation progressed rapidly with regard to strength and proprioception. At six weeks, range-of-motion was within normal limits with demonstration of a stable knee, solid Lachman with negative effusion and only mild intermittent effusion.

At ten weeks, the patient had a normal gait and no longer wore her brace. At twelve weeks, the patient demonstrated negative pivot shift, stable knee, negative Lachman and negative effusion. Her range-of-motion was noted as 0 to 135 degrees with good quadriceps recruitment. Given progress and clinical presentation at eight months post-op, the treating physician released her to full sports activity.

## Discussion

Complete rupture of the ACL, although common, can be a detrimental setback to any patient and in particular, athletes whom it commonly affects.



**Figure 2:** Post-op MRI at six months with continued healing and maturation.

The associated therapies have been widely studied over the years and have evolved into the various options available to the surgeon today. Aside from the decision to perform surgery following an ACL tear, the treating physician's next two crucial decisions involve what type of graft to use and the timing of the athlete's return to sports activities. The latter, although dependent on a multitude of factors, is determined by the degree of post-operative graft maturation through the complex progression of recollagenization and increase in

mineralization after the initial inflammatory response typically seen in wound healing [4].

The reconstruction of the ACL through the use of a tendon autograft is challenging as the insertion site tissue changes from ligament to bone in four progressive zones: ligament, unmineralized fibrocartilage, mineralized fibrocartilage, and bone. This progression in tissue stiffness is largely dependent on collagen fiber alignment and a steady increase in tissue mineralization [4]. Following surgery, tissue macrophages and fibroblasts are recruited to the graft site and begin to form scar tissue at the tendon-bone interface. This tissue is weaker and has decreased pull out strength due to less organized collagen deposition of the new fibrovascular scar tissue. Eight weeks postoperatively, however, this tendon-bone interface undergoes major immunohistological changes. Sharpey-like fibers begin developing due to the shear stresses between the bone tunnel and graft whose size and numbers have been known to be positively correlated with graft pull-out strength. Returning the patient to sports activity too early could impair healing due to continuous microtrauma in these tissues which prolongs the inflammatory response and leads to osteoclastic activation and bone tunnel widening [4]. Timely healing involves a cascade of cytokines including TGF, BMP, and IGF families, MMPs, FGFs, VEGFs, and PDGFs. Research efforts are focusing on creating synergies that enhance healing response times through promotion of cytokines.

One such promising technology is the augmentation of tissue grafts with human amniotic membrane. The amniotic membrane is a non-vascular tissue consisting of chorion and amnion layers. Histological evaluation shows the membrane layers consist of epithelium cells, thin reticular fibers, a thick compact layer and fibroblast layer. The fibrous layer of the amnion contains cell anchoring collagen types: IV, V and VII and over 50 growth factors [5]. *In vivo* and *in vitro* studies have shown biochemical properties of amniotic membrane help modulate inflammation and enhance tissue healing [6,7].

The amniotic membrane product used in this case was AmnioFix<sup>®</sup> (MiMedx Group, Inc., Marietta, GA) a composite amniotic tissue membrane minimally manipulated to protect the collagen matrix and its natural properties. AmnioFix<sup>®</sup> is processed through the proprietary PURION<sup>®</sup> Process that combines cleaning, dehydration and sterilization, and it may be stored at ambient conditions for up to five years. The proprietary PURION<sup>®</sup> Process protects the delicate scaffold during processing, leaving an intact collagen matrix. The result is a durable allograft with natural barrier properties to optimize surgical performance and ease of use.

## Conclusion

With a goal of promoting enhanced healing the hamstring autograft used in this case was augmented with the dHACM allograft. MRI scans at three and six months reflected evidence of early maturation and healing of the graft from what is generally observed in many patients undergoing ACL reconstruction without the addition of the dHACM allograft. These encouraging results warrant further investigation into whether surgeons can safely return patients to sports activity earlier than previously experienced.

## References

1. Griffin LY, Agel J, Albohm MJ, Arendt EA, Dick RW, et al. (2000) Noncontact anterior cruciate ligament injuries: risk factors and prevention strategies. *J Am Acad Orthop Surg* 8: 141-150.

2. Bien DP, Dubuque TJ (2015) Considerations for late stage ACL rehabilitation and return to sport to limit re-injury risk and maximize athletic performance. *Int J Sports Phys Ther* 10: 256-271.
3. Hu J, Qu J, Xu D, Zhou J, Lu H (2013) Allograft versus autograft for anterior cruciate ligament reconstruction: an up-to-date meta-analysis of prospective studies. *Int Orthop* 37: 311-20.
4. Muller B, Bowman KF, Bedi A (2013) ACL graft healing and biologics. *Clin Sports Med* 32: 93-109.
5. Maan ZN, Rennert RC, Koob TJ, Januszyk M, Li WW, Gurtner GC (2015) Cell recruitment by amnion chorion grafts promotes neovascularization. *J Surg Res* 193: 953-962.
6. Koob TJ, Lim JJ, Masee M, Zabek N, Denozière G (2014) Properties of dehydrated human amnion/chorion composite grafts: implications for wound repair and soft tissue regeneration. *J Biomed Mater Res B Appl Biomater* 102: 1353-62.
7. Koob TJ, Rennert R, Zabek N, Masee M, Lim JJ, et al. (2013) Biological properties of dehydrated human amnion/chorion composite graft: implications for chronic wound healing. *Int Wound J* 10: 493-500.