

Anatomical Insight into the Muscle Petropharyngeus-a Supernumerary Muscle of the Posterior Pharyngeal Wall

Siddiqui AU^{1*}, Satapathy BC¹, Siddiqui AT² and Gill SS³

^{1,2}Department of Anatomy, All India Institute of Medical Sciences (AIIMS), Raipur, Chhattisgarh, India

²Department of Cardiothoracic and Vascular Surgery, Charak Hospital, Dubagga, Lucknow, UP, India

³Department of Psychiatry, Grey Nuns Hospital, 1100 Youville Dr W Northwest, Edmonton, Alberta, Canada

*Corresponding author: Siddiqui AU, Assistant Professor, Department of Anatomy, First Floor, Medical College, All India Institute of Medical Sciences (AIIMS), Gate No 5, Tatibandh, GE Road, Raipur, Chhattisgarh, India, Tel: +918518881750; E-mail: anatmicro@gmail.com

Received Date: March 23, 2017; Accepted Date: March 25, 2017; Published Date: March 31, 2017

Copyright: © 2017 Siddiqui AU, et al. This is an open-access article distributed under the terms of the Creative Commons Attribution License, which permits unrestricted use, distribution, and reproduction in any medium, provided the original author and source are credited.

Abstract

Introduction

The patency of pharynx largely depends on its muscular character. Apart from the three constrictor and three longitudinal muscles there are various supernumerary muscles in the pharynx. The present study was planned to provide an anatomical insight into one of the supernumerary muscles-the petropharyngeus.

Materials and methods

The posterior pharyngeal walls were exposed in 44 cadaveric heads and examined for presence of the supernumerary muscle; petropharyngeus. The relationship of the glossopharyngeal nerve in relation to the stylopharyngeus was also examined.

Results

Three cases (7%) presented with petropharyngeus. Two out of these three presented as a muscular entity while in one case it was fibromuscular. 57% cases presented with the glossopharyngeal nerve running along the inferior border of the stylopharyngeus.

Conclusion

The petropharyngeus has an undetermined role in pharyngeal function. The accurate knowledge of this supernumerary muscle can prove useful for the pharyngeal interventionists and utilizing it for the benefit of clinical cases.

Keywords: Petropharyngeus; Supernumerary; Posterior pharyngeal wall; Superior pharyngeal constrictor; Anatomical variations

Introduction

The pharynx has been described as a 12-14 cm long tube which is musculo-membranous in character and is of the shape of an inverted cone. The pharyngeal musculature comprises of three constrictors and three elevators(longitudinal).The dimensions of the pharyngeal width varies constantly because it is dependent on the tone of the muscles, especially the constrictors. The pharynx is limited above by the posterior part of the body of sphenoid and the basilar part of the occipital bone [1]. It is a complex anatomical structure and serves the functions of respiration, speech and swallowing. The human pharyngeal airway is largely dependent on muscular activity so as to maintain its patency. This dependency is the end result of the anatomy and collapsibility of the passage [2]. It is a widely accepted fact that up to 26 muscles and 6 cranial nerves work in unison and an expert coordinated manner to accomplish the task of transporting food or

liquid from mouth till the esophagus. This involves an integrated motion path and neuromuscular coordination pertinent to normal swallowing [3].

The adaptation of the pharynx in performing its function is due to various factors which include the pharyngeal wall, pharyngeal portion of the tongue, oropharynx and the hypopharynx. Constriction of the lumen of pharynx is a peristaltic sequence and results from displacement of tongue, hyoid bone, and larynx and due to the contractility of the constrictor muscles as well as the three longitudinal muscles [4-6]. The complexity of the human pharyngeal airway is substantiated by studies addressing their respiratory modulation. The constrictor muscles have been described as to close the airway as a part of swallowing. These muscles also exhibit a mechanical effect that depends on the lung volume. At high lung volumes they act as constrictors but at low lung volumes they act as dilators [7]. The pharyngeal muscular wall is stated to be surprisingly thin. All the pharyngeal constrictors overlap posteriorly. They are telescoped into each other, just like cups being stacked upon each other [8].

Apart from the three constrictor muscles and three longitudinal muscles of the pharynx, there are various reports mentioning the supernumerary muscles of the pharynx. Bergmann stated that these supernumerary muscles are common [9]. Some earlier workers have described the complicated morphology of the constrictors as well as the supernumerary muscles or structures in the region [10-18]. Shimada et al in a study on 614 Japanese cadavers observed the muscle petropharyngeus in 7 cadavers. This supernumerary muscle of the pharynx is said to be one of the variations of the stylopharyngeus [18]. Bergmann stated that this muscle originated from the petrous portion of the temporal bone in front of the carotid canal. Apart from petropharyngeus, other variations of the stylopharyngeus may present as the occipitopharyngeus, mastoidopharyngeus and the azygopharyngis [9].

The present study was planned to explore the posterior pharyngeal wall for the supernumerary muscles, especially the variations of the stylopharyngeus. Another incidental finding, which was also recorded, was the location of the glossopharyngeal nerve in relation to the petropharyngeus and stylopharyngeus muscle.

Materials and Methods

The present study was done on 44 cadaveric heads fixed in 10% formalin over a period of three years in the Department of Anatomy of the participating institutes. The posterior pharyngeal wall was exposed according to the method described in Grant's Dissector [19]. The region was carefully examined for the presence of supernumerary muscles (if any), especially in proximity to the stylopharyngeus. The cases presenting with the supernumerary muscle were photographed and a schematic diagram was drawn for a better understanding of the case. Moreover the incidental findings related to the relationship of the glossopharyngeal nerve with stylopharyngeus were also observed and charted.

Results

Out of 44 cadaveric heads undertaken for the study, the muscle petropharyngeus was observed in 3(7%). Two out of these three presented as a muscular entity while in one case the petropharyngeus was more like a fibromuscular band. In case number 1 (Figure 1) the petropharyngeus was bilaterally present and the glossopharyngeal nerve ran along the superior border of the stylopharyngeus. In case no 2 (Figure 2) the petropharyngeus was present bilaterally but we could photograph only side as the other sided muscles were destroyed while removing the occipital bone. One interesting observation in case no 2 (Figure 2) was that the course of the glossopharyngeal nerve was along the inferior border of the stylopharyngeus. Case no 3 (Figure 3) presented with unilateral petropharyngeus but instead of being muscular; it was a fibromuscular structure. Moreover it was more horizontally disposed as compared to case no 1 and 2 (where the fibers of the petropharyngeus were more obliquely oriented).

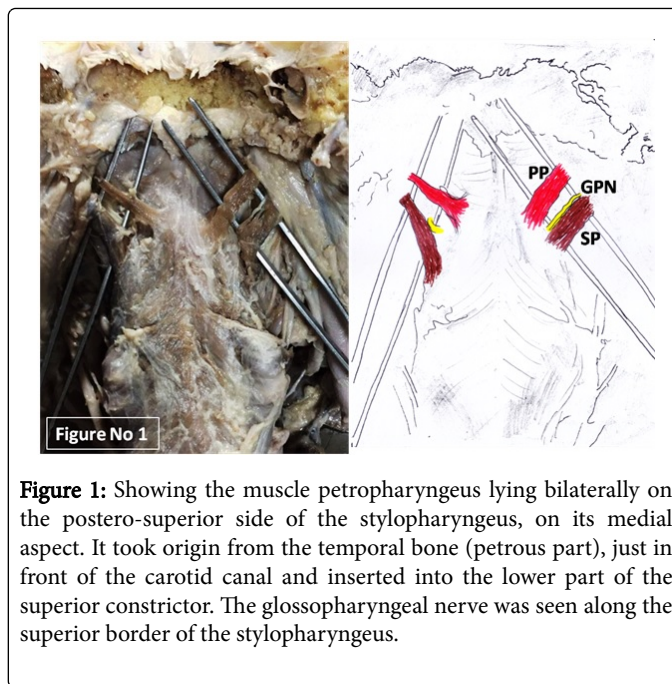


Figure 1: Showing the muscle petropharyngeus lying bilaterally on the postero-superior side of the stylopharyngeus, on its medial aspect. It took origin from the temporal bone (petrous part), just in front of the carotid canal and inserted into the lower part of the superior constrictor. The glossopharyngeal nerve was seen along the superior border of the stylopharyngeus.

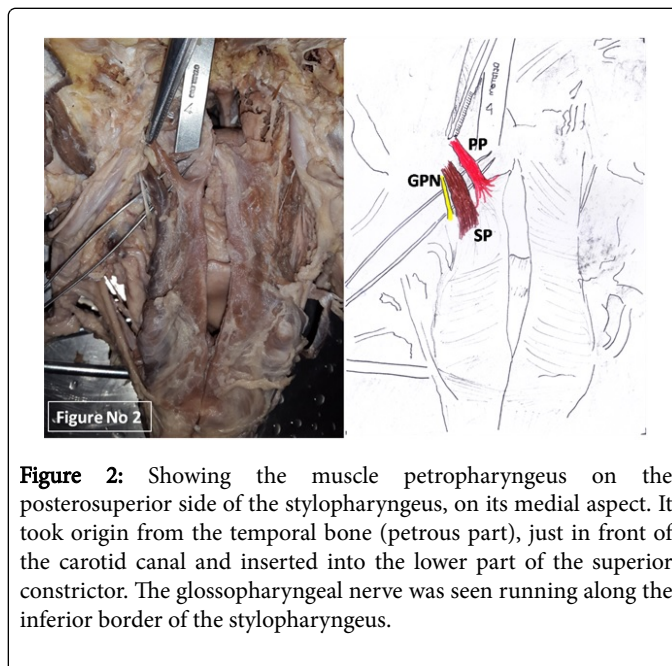


Figure 2: Showing the muscle petropharyngeus on the posterosuperior side of the stylopharyngeus, on its medial aspect. It took origin from the temporal bone (petrous part), just in front of the carotid canal and inserted into the lower part of the superior constrictor. The glossopharyngeal nerve was seen running along the inferior border of the stylopharyngeus.

Cases 4 and 5 (Figures 4 and 5) were photographed for the variant location of the glossopharyngeal nerve in relation to the normal stylopharyngeus muscle. Case no 4 (Figure 4) had the nerve passing along the inferior border whereas case no 5 (Figure 5) had the nerve passing along the superior border of the stylopharyngeus. In both these cases no supernumerary muscles were observed. Out of the 44 cases examined, 19 had the glossopharyngeal nerve running along the superior border of the stylopharyngeus (43%) whereas 25 cases presented with the glossopharyngeal nerve running along the inferior border of the stylopharyngeus (57%).

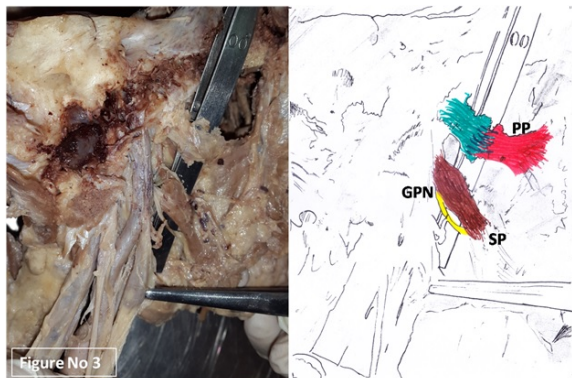


Figure 3: Showing the muscle petropharyngeus lying unilaterally but instead of being muscular was present as a fibromuscular entity and was more horizontally disposed as compared to Figures 1 and 2 (where the petropharyngeal fibers were more obliquely placed).

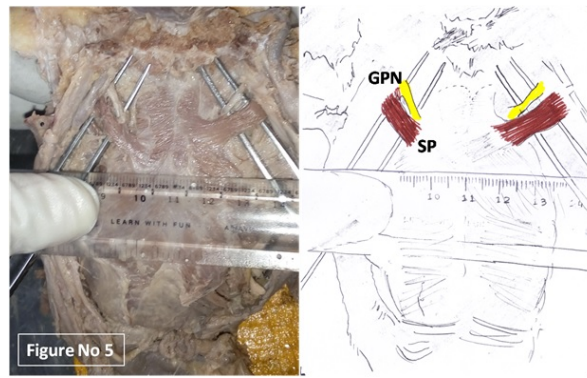


Figure 5: Showing the muscle stylopharyngeus (no petropharyngeus present). The glossopharyngeal nerve was seen along the superior border of the stylopharyngeus.

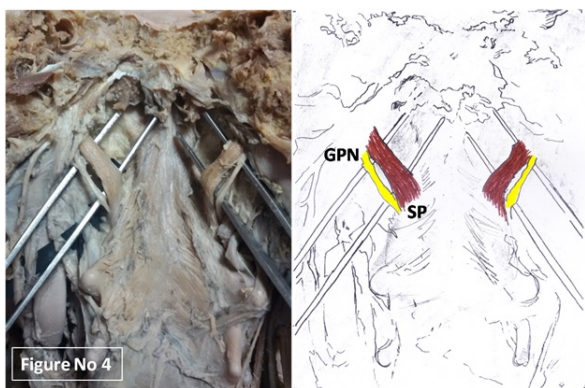


Figure 4: Showing the muscle stylopharyngeus (no petropharyngeus present). The glossopharyngeal nerve was seen along the inferior border of the stylopharyngeus.

All the photographs have been supplemented by a schematic diagram of the structures identified. The abbreviations used are PP for Petropharyngeus, GPN for Glossopharyngeal Nerve and SP for Stylopharyngeus.

Discussion

The present study elucidates upon the muscle petropharyngeus which was observed in 3 cadavers out of 44 cases, 2 were muscular whereas one was a fibromuscular entity. All these supernumerary petropharyngeal muscle bundles were inserted on the superior constrictor. Shimada has referred to Rouviere and mentioned that this muscle inserted into the middle constrictor. Furthermore, Shimada cites Testut describing well developed petropharyngeus inserting to the inferior constrictor. All cases in Shimada's study had the petropharyngeus inserting on the middle constrictor [18].

The posterior pharyngeal wall has chagrined the interventionists for long. Various workers have worked upon the area. Tsumori et al, in a study on 37 cadavers described various aspects of the superior constrictor muscle and suggested that it enables a smooth transition from the lingual stage to the pharyngeal stage during ingestion [10]. Bosma and Leaper have conducted anatomical studies on the constrictor muscles to ascertain their morphologic properties [11,12]. Sakamoto attempted to classify the pharyngeal muscles based on the nerve supply by glossopharyngeal and vagus nerves. Out of the 22 cadavers, one case presented with three anomalous bundles resembling the petropharyngeus. These bundles were supplied by the pharyngeal plexus from their ventral surface, indicating closer relation to the constrictors than the stylopharyngeus. Sakamoto further mentioned that the occurrence of the anomalous bundles was due to the variable morphogenetic process of the pharynx and may influence the pharyngeal functions [15].

The stylopharyngeus is said to be an elevator of the pharynx and larynx. The glossopharyngeal nerve curves around the posterior border and lateral side of the stylopharyngeus and passes between the superior constrictor and middle constrictor to reach the tongue [1]. There is a gap laterally between superior constrictor and middle constrictor, through which stylopharyngeus passes down into the pharynx and gets inserted into the posterior border of the thyroid lamina [8]. Meng et al. in a study on 78 sides of 55 cadavers mentioned that, of all the 3 longitudinal muscles, the stylopharyngeal contractions seems to be the most effective for pharyngeal clearance. They also have described that, out of the three longitudinal muscles of the pharynx, the stylopharyngeus is the only muscle with an origin outside the pharyngeal wall (i.e. the styloid bony process). They hypothesized that,

inter-individual anatomic variations in stylopharyngeal insertion, if present, are committed to the pharyngeal clearance function and play a critical role in the clearance of the piriform recess [16].

The present paper provides an insight into the supernumerary muscle petropharyngeus, which lies in close proximity to the stylopharyngeus and probably has an undetermined role in the functionality of the pharynx. There have been published reports of newly identified structures in the region [17]. But on reviewing the literature available, as regards the incidence of the supernumerary petropharyngeus muscle, it was seen that not many reports are available for the muscle in discussion. Shimada et al reported this muscle in 1.4% of the cases undertaken for the study. They have stated that petropharyngeus muscle might have come into existence by the separation of the fibers from stylopharyngeus (while its derivation from the mesenchymal cells of the third branchial arch [18].

The findings of the present study compel us to rethink about the occurrence of the supernumerary muscles and their probable contributions in pharyngeal function. This might have a role in obstructive sleep apnoea, abnormal swallowing, pharyngeal clearance, speech, respiratory modulation, dysphagia, cancer, pharyngeal reconstruction, pharyngoplasty etc. [2,4,7,10,20-23]. Understanding the normal/abnormal anatomy and physiology of eating and swallowing is the fundamental keystone in evaluating and treating disorders, pertinent to the region and in developing programs for dysphagia rehabilitation.

The morphological parameters presented in this paper supplement the existing knowledge and information regarding the petropharyngeus muscle. This could be helpful for the interventionists for accuracy of diagnosing the disorders encountered in the region. This anatomical data can be further explored by planning corroborative functional studies and utilizing it for clinical benefits.

Acknowledgements

We are very grateful to the following Professors who were of immense help to us in acquiring some of the references which were not available to us

Dr Ikuo Kagayama, Nippon Dental University, Japan

Dr Kojiro Takezawa, Nippon Dental University, Japan

Dr Suzuki Daisuke, Sapporo Medical University, Japan

Dr Jatin Shah, MSK Cancer Center, New York, USA

Dr Koichiro Matsuo, Fujita Health University, Japan

Dr Yujiro Sakamoto, Tokyo Medical Dental University, Japan

References

1. McHanwell S. Head and Neck.(2016) In: Standring S, Gleeson M, eds. *Gray's Anatomy: The Anatomical Basis of Clinical Practice*. 41st ed. Elsevier :571-581
2. Fogel RB, Malhotra A, White DP (2004) Sleep. 2: Pathophysiology of obstructive sleep apnoea/hypopnoea syndrome. *Thorax* 59: 159-163.
3. Donner MW, Bosma JF, Robertson DL (1985) Anatomy and physiology of the pharynx. *Gastrointest Radiol* 10: 196-212.
4. Bosma JF, Donner MW, Tanaka E, Robertson D (1986) Anatomy of the pharynx, pertinent to swallowing. *Dysphagia* 1: 23-33.
5. Lunteren E (1993) Muscles of the pharynx: structural and contractile properties. *Ear Nose Throat J* 72: 27-29.
6. Kahrilas PJ (1993) Pharyngeal structure and function. *Dysphagia* 8: 303-307.
7. Edwards BA, White DP (2011) Control of the pharyngeal musculature during wakefulness and sleep: implications in normal controls and sleep apnea. *Head Neck* 33: S37-S45.
8. Sinнатamby CS (2011) *Last's Anatomy Regional and Applied*. Elsevier Health Sciences.
9. Bergman RA, Thompson SA, Afifi AK, Saadeh FA (1998) *Compendium of Human Anatomic Variation: Catalog, Atlas and World Literature*. Baltimore and Munich: Urban & Schwarzenberg.
10. Tsumori N, Abe S, Agematsu H, Hashimoto M, Ide Y (2007) Morphologic characteristics of the superior pharyngeal constrictor muscle in relation to the function during swallowing. *Dysphagia* 22: 122-129.
11. Bosma JF, Bartner H (1993) Ligaments of the larynx and the adjacent pharynx and esophagus. *Dysphagia* 8: 23-28.
12. Leaper M, Zhang M, Dawes PJD (2005) An anatomical protrusion exists on the posterior hypopharyngeal wall in some elderly cadavers. *Dysphagia*. 20: 8-14.
13. Sakamoto Y (2014) Gross anatomical observations of attachments of the middle pharyngeal constrictor. *Clin Anat* 27: 603-609.
14. Murakami K, Kuroda M, Kishi K (1996) Variations of the constrictor pharyngeal muscles in humans Kaibogaku Zasshi. *Journal of anatomy* 71: 638-649.
15. Sakamoto Y (2009) Classification of pharyngeal muscles based on innervations from glossopharyngeal and vagus nerves in human. *Surg Radiol Anat* 31: 755-761.
16. Meng H, Murakami G, Suzuki D, Miyamoto S (2008) Anatomical variations in stylopharyngeus muscle insertions suggest interindividual and left/right differences in pharyngeal clearance function of elderly patients: a cadaveric study. *Dysphagia* 23: 251-257.
17. Takezawa K, Kageyama I (2012) Newly identified thin membranous tissue in the deep infratemporal region. *Anat Sci Int* 87: 136-140.
18. Shimada K, Yokoi A, Ozawa H, Kitagawa T, Tezuka M (1991) Observation of the petropharyngeal muscle in Japanese. *Anat Anz* 173: 193-198.
19. Tank PW (2013) *Grant's Dissector*. New Delhi: Lippincott. Williams and Wilkins 254-257.
20. Daniel MM, Lorenzi MC, Leite CD, Filho LG (2007) Pharyngeal dimensions in healthy men and women. *Clin* 62: 5-10.
21. Stokely SL, Pigeon M, Leigh C, Molfenter SM, Steele CM (2015) The relationship between pharyngeal constriction and post-swallow residue. *Dysphagia* 30: 349-356.
22. Shah JP, Shemen L, Spiro RH, Strong EW (1984) Selecting variants in pharyngeal reconstruction. *Ann Otol Rhinol Laryngol* 93: 318-321.
23. Mesti J, Cahali MB (2012) Evolution of swallowing in lateral pharyngoplasty with stylopharyngeal muscle preservation. *Braz J Otorhinolaryngol* 78: 51-55.

This article was originally published in a special issue, entitled: "**Muscle Research**", Edited by Sawant SP