

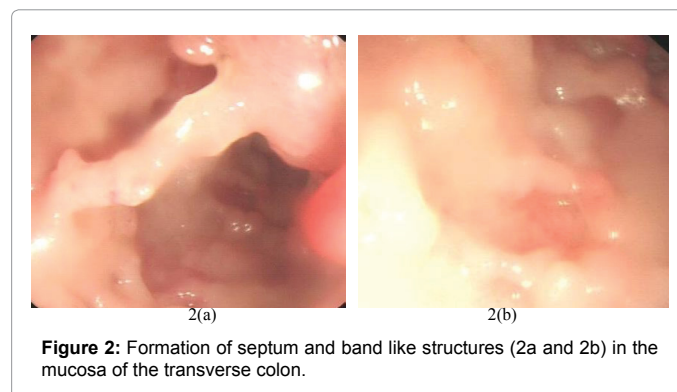
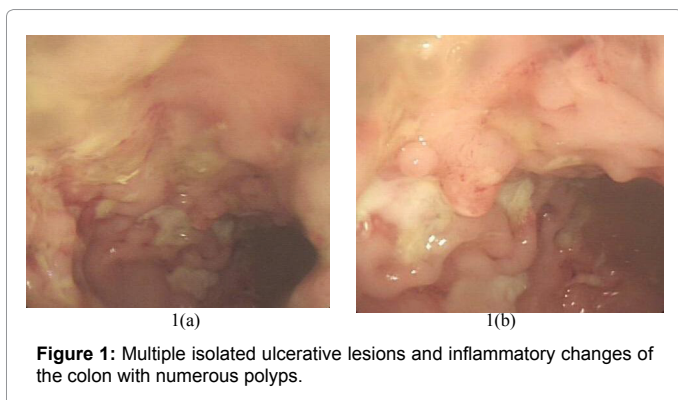
An Unusual Presentation of Ulcerative Colitis with Numerous Colon Polyps and Formation of Multiple Band and Septum Like Structures in the Colonic Lumen

Abu Taiub Mohammed Mohiuddin Chowdhury* and Cuiying

Department of Digestive Disease-II, The first affiliated Hospital of Jiamusi University, Jiamusi, China

Clinical Image

An unusual presentation of ulcerative colitis with numerous colon polyps and formation of multiple band and septum like structures in the colonic lumen (Figures 1 and 2).



***Corresponding author:** Abu Taiub Mohammed Mohiuddin Chowdhury, Department of Digestive Disease-II, The first affiliated Hospital of Jiamusi University, Jiamusi, China, E-mail: dr_mohiuddinchy@yahoo.com

Received November 12, 2014; **Accepted** November 20, 2015; **Published** November 27, 2015

Citation: Chowdhury ATMM, Cuiying (2015) An Unusual Presentation of Ulcerative Colitis with Numerous Colon Polyps and Formation of Multiple Band and Septum Like Structures in the Colonic Lumen. J Hepatol Gastroint Dis 1: i101. doi: [10.4172/2475-3181.1000i101](https://doi.org/10.4172/2475-3181.1000i101)

Copyright: © 2015 Chowdhury ATMM, et al. This is an open-access article distributed under the terms of the Creative Commons Attribution License, which permits unrestricted use, distribution, and reproduction in any medium, provided the original author and source are credited.