

An Ultra-Conservative Approach of Treating Coronal Tooth Fragment: Re-attachment Case Reports

M Jayadev, Karunakar P, Raji Viola Solomon, Raji Viola Solomon, G Sushma Shravani

Department of Conservative Dentistry & Endodontics, Panineeya Institute of Dental Sciences & Research Institute, Hyderabad, India

Abstract

Dental traumatic fractures are the common reason for seeking dental care and coronal fractures being the frequent type of dental trauma encountered in the permanent dentition. The acid etch adhesive technique may be used to restore function and esthetics of fractured anterior teeth. But whenever the fractured fragment is available, re-attachment will be a viable option as it offers certain advantages over the composite restorations. Reported here are the two case reports describing the treatment modalities of patients who sustained fractures of maxillary teeth due to trauma. At one year follow up, no marginal discoloration, no fracture segment debonding or recurrent decay were found and the resultant appearance was acceptable to the patient.

Key words: Re-attachment, Fiber-reinforced post

Introduction

The majority of dental traumatic injuries involve the anterior teeth, especially the maxillary incisors nearly up to 80% of all traumatic injuries and this high incidence is due to their anatomical position and protrusion caused by eruptive process [1]. A dental trauma with the resulting fracture of the anterior teeth is an agonizing experience for a young individual who requires immediate attention, not only because of the physical impairment but also because of the psychological impact on the patient [2].

When the fractured fragment is available, with advances in adhesive dentistry and growing interest towards minimal invasive procedures, reattachment of the tooth fragment is the choice of treatment [3].

Depending on different clinical situations, various techniques and materials were advocated to restore fracture teeth [4]. Tennery was the first person to report the reattachment of a fractured fragment using the concept of adhesive dentistry [1].

The advantages of this procedure over conventional composite restoration are: esthetics, economical approach, psychological comfort to the patient, exact reconstruction of tooth morphology and increased wear steadiness [5-6].

The present case reports discuss the reattachment of the coronal tooth fragment with the fracture involving enamel, dentin and pulp using fiber post with a follow up period of one year.

Case Report 1

An 18-year-old boy reported to the department of Conservative dentistry & Endodontics, Panineeya Mahavidhyalaya Institute of Dental Sciences, Hyderabad following fracture of the crown in the left maxillary lateral incisor (Figure 1). The trauma had occurred due to a bicycle accident about 8 hours ago. The patient's medical history was noncontributory. No mobility of the injured tooth was recorded and there was no apparent trauma to the soft tissues in the extra oral and intra oral examination. Clinical and radiographic examination revealed that there was a horizontal

fracture in the cervical third region of the left maxillary incisor involving enamel and dentin with exposure of the pulp and the fractured fragment was loosely attached to the tooth (Figure 2,3). A detailed explanation about the treatment plan was given to the patient, which included endodontic treatment, then reattachment of the tooth fragment using a fiber post and the treatment plan was accepted by the patient.

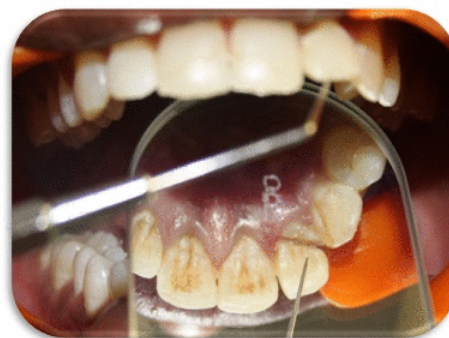

Figure 1. Pre-operative clinical picture wrt 22.

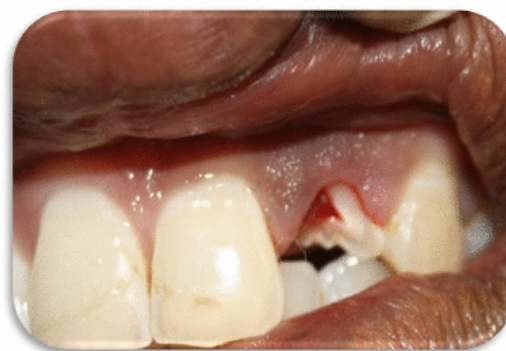

Figure 2. After fragment removal.

Corresponding author: G.Sushma Shravani, Department of Conservative Dentistry & Endodontics, Panineeya Institute of Dental Sciences & Research Institute, Hyderabad, India; e-mail: sushma.shravanig@gmail.com

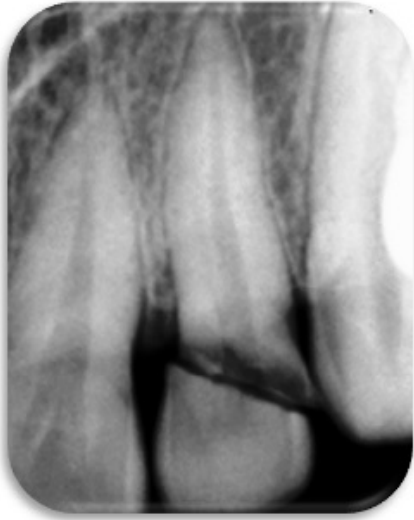

Figure 3. Pre-operative radiograph.

Local anesthetic was administered and the segment was removed and stored in normal saline to prevent discoloration and dehydration. Following a detailed examination, the adaptation of the fragment was checked. The working length was determined with radiography. The root canal was enlarged to ISO size 40 using step back technique. 2.5% Sodium hypochlorite and saline were used during the preparation. The root canal was dried with paper points and obturated using lateral condensation technique with gutta-percha (Dentply Maillefer, Ballaigues, Switzerland) and AH-plus sealer (Maillefer, Dentply, Konstanz, Germany). The root canal was prepared for the post placement by removing the gutta-percha from the coronal two third of the canal with paeso reamers (Drill size no 2) (Figure 4). The fiber post (Dentply Tulsa, Johnson City, US) was tried in the canal and adjusted to the desired length (Figure 5). Space was also prepared in the pulp chamber of the fractured crown fragments for receiving the coronal portion of the post and also the core. The root canal was then etched with 37% ortho phosphoric acid (Ivoclar Vivadent), rinsed, blot dried with paper points, and bonding agent (Prime & Bond NT, fifth generation) was applied. The post was then luted in the canal using dual cured resin luting cement (Ivoclar Vivadent). The inner portion of the coronal fragment was similarly etched and bonded to the tooth using flowable composite resin (Ivoclar Vivadent) after proper shade matching (Figure 6,7). Occlusion was checked and postoperative instructions to the patient were given to deter from loading the anterior teeth. Clinical and radiographic examinations were carried out after one month, three months, six months and one year (Figure 8) and the tooth responded favorably both esthetically and functionally.

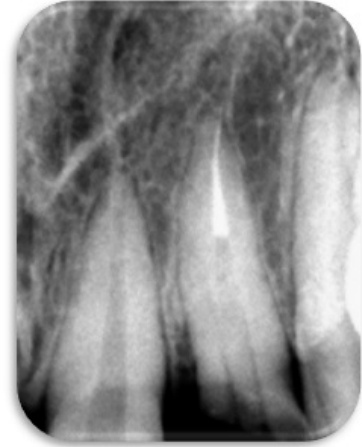

Figure 4. Post space preparation.

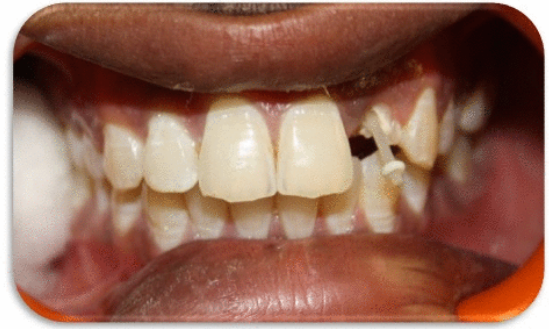

Figure 5. Clinical picture of post cementation.

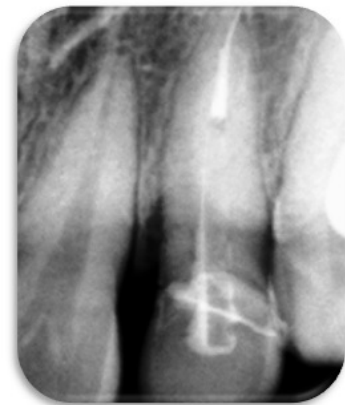

Figure 6. Fiber post cementation.

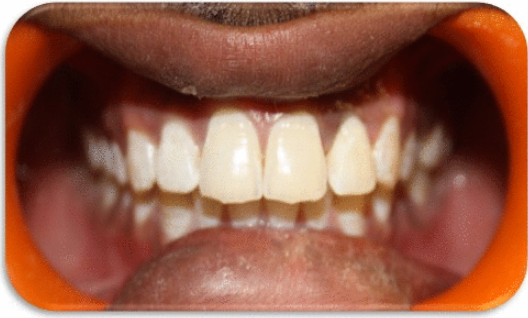

Figure 7. After fragment reattachment.

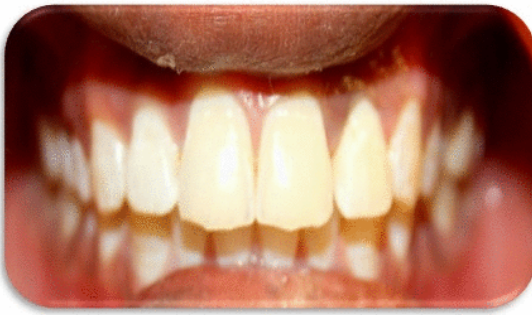

Figure 8. After one year follow up.

Case Report 2

A 23-years-old male patient reported to the Department of Conservative Dentistry and Endodontics, Panineeya Mahavidhyalaya Institute of Dental Sciences, Hyderabad following trauma to maxillary right lateral incisor due to fall from stair case one day back (Figure 9). The patient's medical history was noncontributory. No mobility and soft tissue trauma in the extra oral and intra oral examination. On clinical and radiological examination an oblique fracture was seen with crown portion of right maxillary lateral incisor, which extended from cervical third of crown on labial side to 1 mm subgingivally on the lingual aspect (Figure 10-12). A detailed explanation about the treatment plan was given to the patient, which included endodontic treatment, then reattachment of the tooth fragment using a fiber post and the treatment plan was accepted by the patient.

After local anesthesia, the fracture fragment was removed atraumatically and stored in normal saline. Single visit endodontic therapy was performed (Figure 13). The day after completion of the endodontic treatment, the root canal was prepared for the post placement by removing the gutta- percha from the coronal two third of the canal with paeso reamers (drill size 2) (Figure 14).

As there was a perfect approximation of the fractured fragment there was no need for the elevation of the flap. Then the desired length fiber post (Dentply Tulsa, Johnson city, US) was luted with dual cure resin composite (Ivoclar Vivadent) after etching with 37% phosphoric acid (Ivoclar Vivadent) and bonding agent applicaton (Prime & Bond NT, fifth generation) (Figure 15).

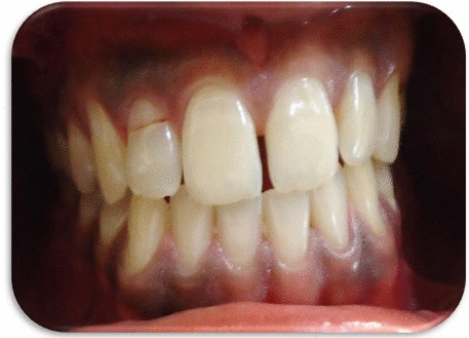

Figure 9. Pre-operative clinical picture.

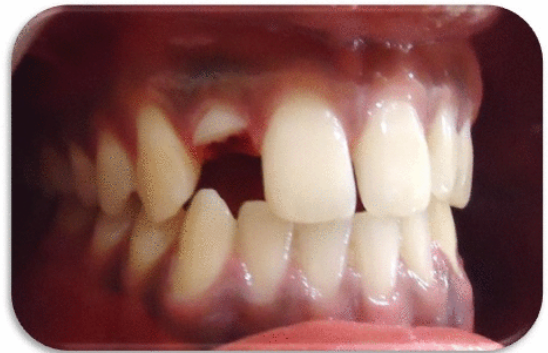

Figure 10. After fragment removal.

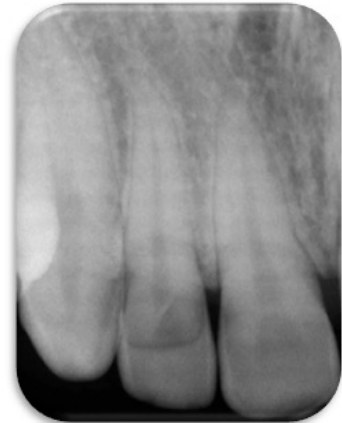

Figure 11. Pre-operative radiograph.

The inner portion of the coronal fragment was similarly etched and bonded to the tooth using flowable composite resin (Ivoclar Vivadent) after proper shade matching (Figure 16). Finishing and polishing was performed for the teeth and the patient was kept on recall after one month, three months and one year (Figure 17). The restored teeth were found to be in good condition, both esthetically and functionally.

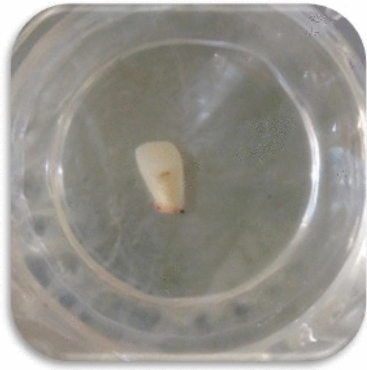

Figure 12. After fragment removal.

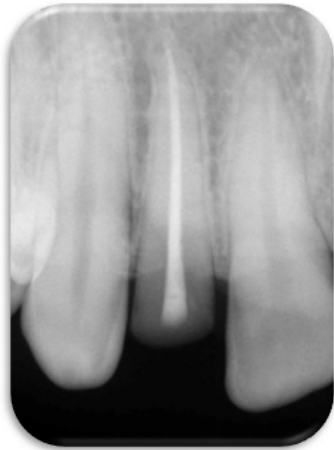


Figure 13. Obturation.

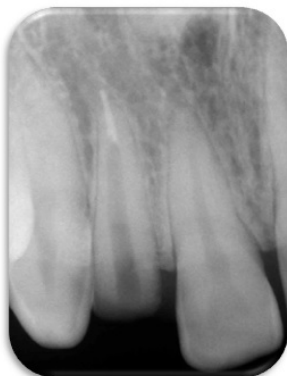

Figure 14. Post space preparation.

Discussion

Function, aesthetics and biologic restoration of fractured incisor often presents a de-vasting clinical challenge. Development of adhesive material creates new perspectives in reconstruction of fracture teeth. Re-attachment of the fractured fragment would be an alternate treatment option whenever fracture segment is available [7].

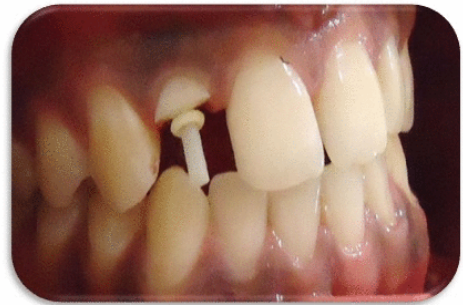

Figure 15. Fiber post cementation.

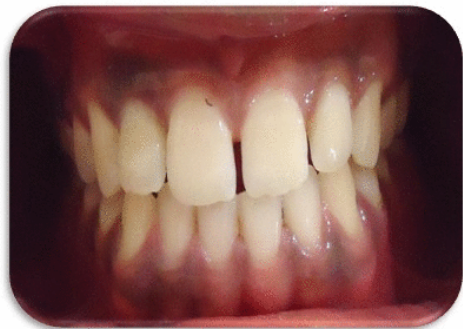

Figure 16. After fragment re-attachment.

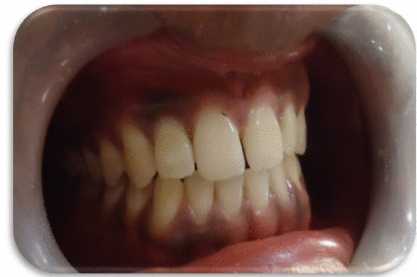

Figure 17. After one year follow up.

In literature based on the location of fracture line, there are various treatment modalities, which include orthodontic extrusion and surgical extrusion when the fracture line is below the crest of bone [8-9], placing a chamfer at the fracture line, using V-shaped enamel notch, placing an internal groove when the fracture line is above the crest of bone height and above marginal gingiva [9].

In the present case the fracture line is below the gingival contour and marginal alveolar crest without violating biologic width. Therefore, application of extrusion is not done.

Clinical evidence so far suggests that properly cured and finished composite resin may also be used in sub-gingival location [10-11].

In the present case reports fractured segment is reinforced using fiber post. The post interlocks two separated fragments and minimizes the stress on the remaining tooth structure. The fiber posts have a modulus of elasticity similar to dentin, that allows more even distribution of occlusal stress in the root dentin and they provide significantly less resistance to failure than cemented custom cast posts and core [12].

A quote by Liew is very appropriate in describing the prognosis for this procedure. He believes this restoration to act as “a short to medium term temporary restoration which has a potential for indefinite success” [13].

The longevity of a tooth fragment reattachment is not foreseeable, but the real merit of reattachment lies in the fact that all other restorative options, such as direct adhesive techniques, veneers, and crowns will always be open. With the advancement in dental bonding technology, now it is possible to achieve excellent results with reattachment of dislocated tooth fragments, provided that the biologic factors and selection of materials are logically assessed and managed.

The success of reattachment procedure depends on the cumulative effects of, proper use of bonding protocols, bonding materials, preparation techniques and patient education.

Conclusion

Now in the era of concern with minimal invasive techniques and esthetic considerations, re-attachment is one such procedure which offers with an ultraconservative, safe, fast, esthetically and functionally pleasing results whenever the fractured fragment is available.

References

1. Tennery TN. The fractured tooth reunified using the acidetch bonding technique. *Texas Dental Journal*. 1978; **96**:16-17.
2. Ece Eden, Saniye Çiçek Yanar, Şule Sönmez. Reattachment of subgingivally fractured central incisor with open apex. *Dental Traumatology*. 2007; **23**: 184-189.
3. RJ Simonsen. Traumatic fracture restoration: an alternative use of the acid etch technique. *Quintessence International*. 1979; **10**: 15-22.
4. Baklava P, Anup N. Risk factors for traumatic dental injuries in an adolescent male population in India. *The Journal of Contemporary Dental Practice*. 2007; **8**: 35-42
5. RD Trushkowsky. Esthetic, biologic, and restorative considerations in coronal segment reattachment for a fractured tooth: a clinical report. *The Journal of Prosthetic Dentistry*. 1998; **79**: 115-119.
6. K Arapostathis, A Arhakis, and S Kalfas. A modified technique on the reattachment of permanent tooth fragments following dental trauma. Case report. *Journal of Clinical Pediatric Dentistry*. 2005; **30**: 29-34, 2005.
7. Yucel Yilmaz, Cigdem Zehir, Ozge Eyuboglu, Nihal Belduz. Evaluation of success in reattachment of coronal fracture. *Dental Traumatology*. 2008; **24**:151-158.
8. Holan G, Shmueli Y. Knowledge of physicians in hospital emergency rooms in Israel on their role in cases of avulsion of permanent incisors. *International Journal of Paediatric Dentistry*. 2003; **13**: 13-19
9. Villat C, Machtou P, Naulin-lfi C. Multidisciplinary approach to the immediate esthetic repair and long term treatment of an oblique crown – root fracture . *Dental Traumatology*. 2004; **20**: 56-60.
10. Maia EA, Baratieri LN, de Andrada MA, Monteiro S Jr, de Araújo EM Jr. Tooth fragment reattachment: fundamentals of the technique and two case reports. *Quintessence International*. 2003; **34**: 99-107
11. LN Baratieri, SM J'uniór, AC Cardoso, JCD Filho. Coronal fracture with invasion of the biologic width: a case report. *Quintessence International*. 1993; **24**: 85-91.
12. Greenfeld RS, Roydhouse RH, Marshall FJ, Schoner BA. Comparison of two post systems under applied compressive-shear loads. *Journal of Prosthetic Dentistry*. 1989; **61**:17-24.
13. Liew VP . Reattachment of original tooth fragment to a fractured crown: Case report. *Australian Dental Journal*. 1988; **33**: 47-50.