

Ameliorative Potential of Tamoxifen/Thymoquinone Combination in Patients with Breast Cancer: A Biochemical and Immunohistochemical

Ahmed M Kabel^{1,2*}, Mohamed A El-Rashidy³ and Mohamed S Omar^{4,5}

School of Chemical Sciences, Central University of Gujarat, Gandhinagar- 382030, India

¹Pharmacology Department, Faculty of Medicine, Tanta University, Tanta, Egypt

²Department of Clinical pharmacy, College of Pharmacy, Taif University, Taif, Saudi Arabia

³Pathology Department, Faculty of Medicine, Tanta University, Tanta, Egypt

⁴Chemistry Department, Faculty of Science, Benha University, Benha, Egypt

⁵Division of Biochemistry, Pharmacology and Toxicology Department, College of Pharmacy, Taif University, Taif, Saudi Arabia

*Corresponding author: Ahmed M. Kabel, El-Geish street, Faculty of Medicine, Tanta University, Department of Pharmacology, Tanta, Egypt, Tel: 00201009041488; E-mail: drakabel@gmail.com

Received date: October 04, 2015; Accepted date: December 11, 2015; Published date: January 05, 2016

Copyright: © 2016 Kabel AM, et al. This is an open-access article distributed under the terms of the Creative Commons Attribution License, which permits unrestricted use, distribution, and reproduction in any medium, provided the original author and source are credited.

Abstract

Background: Breast cancer is one of the most common types of malignancies in females worldwide. Targeting the estrogen receptors alone with tamoxifen, reduces the incidence of estrogen receptor positive tumors but the possibility of development of tamoxifen resistance remains the most important adverse effect. Thymoquinone is an important constituent of the *Nigella sativa* plant (Black seed). It was found to be cytotoxic in several types of multi-drug resistant human tumor cell lines.

Objective: To detect the effects of the combination between tamoxifen and thymoquinone in patients with breast cancer.

Methods: Eighty female patients with breast cancer were divided into four equal groups: control untreated group, tamoxifen treated group, thymoquinone treated group and tamoxifen + thymoquinone treated group. Tissue malondialdehyde (MDA), catalase (CAT), superoxide dismutase (SOD), tumor necrosis factor-alpha (TNF- α), interleukin 6 (IL-6) and transforming growth factor beta1 (TGF- β 1) were determined in the tumor tissues. Parts of the tumor were subjected to immunohistochemical examination. The survival rate and the relapse rate were measured every year for five years.

Results: Tamoxifen or thymoquinone alone or in combination induced significant increase in the 5-years survival rate, tumor CAT and SOD with significant decrease in the relapse rate, tumor tissue MDA, TNF- α , IL-6 and TGF- β 1 and alleviated the immunohistochemical changes with significant increase in tissue caspase-3 expression and significant decrease in tissue bcl2 compared to the control untreated group.

Conclusion: Tamoxifen/ thymoquinone combination had a better effect than each of these drugs alone on patients with breast cancer. So, the addition of thymoquinone to tamoxifen may represent a new therapeutic modality for management of breast cancer.

Keywords: Cisplatin; Anticancer; Breast cancer; SAR; DBA; Binding constant; Antioxidant

Introduction

Breast cancer includes various types of cancers that originate from the breast tissue. It is the most common invasive cancer in women worldwide [1]. Signs of breast cancer include a lump in the breast, a change in breast shape, nipple discharge or a red scaly patch of skin. Risk factors for developing breast cancer include female sex, obesity, lack of physical exercise, drinking alcohol, hormone replacement therapy during menopause, ionizing radiation, early age at first menstruation, older age and genetic factors [2,3]. Diagnosis of breast cancer is confirmed by taking a biopsy of the concerning lump. Once

the diagnosis is made, further tests are done to determine the stage of breast cancer and which treatments it may respond to [3].

There are various lines of treatment of breast cancer depending on the stage of the tumor. They include hormone blocking therapy, chemotherapy, monoclonal antibodies and radiotherapy [4]. Antiestrogens such as tamoxifen (TAM) are commonly used as a first-line endocrine therapy for premenopausal women with breast cancer. However, TAM use was associated with some side effects such as increased risk for endometrial cancer, deep vein thrombosis and pulmonary embolism and development of resistance [5,6]. Mechanisms of resistance may include pharmacologic mechanisms, loss or modification in estrogen receptor expression, alterations in the regulatory proteins that participate in different cellular processes, inhibition of apoptosis regulated by the Bcl-2 famil and altered mRNA

expression [7]. These adverse effects resulted in the use of alternative treatments such as complementary and alternative medicine [8].

Nigella sativa appears as one of the important herbs among various medicinal plants. The majority of the biological activities of *Nigella sativa* are associated with the presence of thymoquinone (TQ), the major bioactive compound found in the seeds of the plant [9]. A number of pharmacological actions of TQ have been investigated including anti-oxidant, anti-inflammatory, immunomodulatory, anti-histaminic, anti-microbial and anti-tumor effects. It has also gastroprotective, hepatoprotective, cardioprotective, nephroprotective and neuroprotective activities. In addition, a large body of data show that TQ has very low adverse effects and no serious toxicity [10]. TQ exhibited strong cytotoxic activities against several cancer cell lines including human cervical adenocarcinoma, human squamous carcinoma, human oestrogen receptor negative breast adenocarcinoma, and human oestrogen receptor positive breast adenocarcinoma [11,12]. So, studying the effect of TQ on breast cancer alone and in combination with antiestrogens is of particular interest.

Materials and Methods

Chemicals and drugs

Tamoxifen citrate (TAM, Nolvadex) was purchased from AstraZeneca UK Limited (Macclesfield, Cheshire, UK). Thymoquinone (TQ) was obtained from Frinton laboratories, USA, as a yellow crystalline powder. The drug was then prepared as 100 mg, 200 mg and 400 mg capsules at Taif University laboratory, Taif. All other chemicals and reagents used were purchased from Sigma Chemical company (St. Louis MO, USA).

Eligibility criteria

Patients ≥ 18 years of age, with histologically confirmed advanced malignant disease for which there were no standard curative or palliative measures were included in this study. Eligible patients were required to have an Eastern oncology cooperative group (ECOG) performance status score of ≤ 2 . The patients were required to have an adequate liver function tests and renal function tests (Bilirubin $\leq 1.5 \times$ upper limit of normal [ULN], ALT and AST $\leq 3 \times$ ULN, Creatinine $1.5 \times$ ULN, and BUN $2 \times$ ULN). The complete blood count requirement included an absolute granulocyte count of $\geq 1500/\mu\text{l}$, platelet count $\geq 100,000/\mu\text{l}$ and hemoglobin ≥ 9 gm/dl. Patients were excluded if they had brain metastasis, had suffered from myocardial infarction in the last 4 months, had a congestive heart failure functional status \geq II, or had coagulopathy disorder. The study protocol was approved by the local ethics committee of Taif university. After explaining the possible side effects and outcomes of TAM and TQ, a written consent was obtained from each patient who participated in the study. In this study, eighty female patients were randomly divided into four equal groups as follows:

Group (1): is the control untreated group.

Group (2): TAM was given in a dose of 10 mg twice daily orally for 6 months [13].

Group (3): TQ was given orally in a dose of 10 mg/kg daily for 6 months [14].

Group (4): TAM was given concomitantly with TQ orally in the above doses for 6 months.

At the end of the study, a biopsy was taken from the tumor and divided into two portions; one for homogenization and the other for immunohistochemical examination. Parts of the tumor biopsy were homogenized for determination of tissue catalase (CAT) according to the method described by Higgins et al. [15], tissue malondialdehyde (MDA) according to Uchiyama and Mihara [16], tissue superoxide dismutase (SOD) according to the method described by Marklund and Marklund [17], tissue interleukin-6 (IL-6) using ELISA kits purchased from Sigma Chemical Co. according to the instructions of the manufacturer, tissue tumor necrosis factor alpha (TNF- α) using TNF- α ELISA kits supplied by RayBiotech, Inc. according to the instructions of the manufacturer and tissue TGF- $\beta 1$ using ELISA kits purchased from Uscn Life Science Inc. Wuhan, according to the instructions of the manufacturer. The survival rate of the patients and the relapse rate were measured every year after the end of the study for five years.

Immunohistochemical examination

Assessment of tumor tissue bcl-2 was carried out in formalin-fixed, paraffin embedded tumor sections using monoclonal antibodies against bcl-2 that were purchased from Zymed Laboratories Inc., USA. Bcl-2 was considered positive if the tumor cells showed cytoplasmic or perinuclear localization of immunoreactivity. This was expressed as follows: (++++): the largest number of cells showing positive staining for bcl2; (+++): intermediate number of bcl2-positive cells; (++): indicates lower number of cells showing positive staining for bcl2 [18].

Immunohistochemistry for caspase-3 was performed in sections prepared from formalin-fixed, paraffin-embedded tissue using the avidin-biotin immunodetection complex method according to manufacturer's instruction (Labvision, USA). Interpretation of results was done semiquantitatively by evaluating both intensity and distribution of positive cells. Cytoplasmic staining for caspase-3 was carried in tumor cells. The intensity of caspase-3 immunostaining was assessed as follows: none = 0, mild = 1, moderate = 2 and strong = 3. The immunohistochemical histological score (H-score) was then calculated by multiplying the intensity by the percentage of tumor cells showing positive staining for caspase-3, creating a range of possible scores of 0–300 [19]. All the immunohistochemical investigations were performed by two independent pathologists to minimize the observer bias.

Statistical analysis

The data obtained were subjected to one way ANOVA and Tukey's multiple comparison test. Data were presented as mean \pm S.E.M. Differences between the means of different groups were considered significant at a level of p-value less than 0.05.

Results

Effect of different treatments on tissue antioxidant status

Administration of TAM and/or TQ resulted in significant increase in tissue CAT and SOD with significant decrease in tissue MDA compared to the control untreated group. The increase in tissue CAT and SOD with the decrease in tissue MDA were significant in the group that received TAM/TQ combination compared to the groups that received either TAM or TQ alone (Table 1).

	Control	Tamoxifen	Thymoquinone	Tamoxifen + Thymoquinone
Tissue CAT U/mg tissue	13.5 ± 0.41	24.1 ± 0.69a	18.71 ± 0.6a	29.82 ± 0.6abc
Tissue SOD U/g/min	117.4 ± 6.3	243.4 ± 6.3a	178.2 ± 5.1 a	282.5 ± 8.2abc
Tissue MDA μmol/g tissue	255.5 ± 5.34	167.4 ± 3.06a	190.5 ± 4.05a	142.5 ± 3.7abc
Tissue TNF-α pg/g tissue	884.2 ± 10.24	546.8 ± 7.2a	626.12 ± 7.8a	418.6 ± 6.47abc
Tissue IL-6 pg/g tissue	1221.5 ± 16.5	831.6 ± 9.4a	972.6 ± 12.1a	541.7 ± 8.8abc
Tissue TGF-β1 pg/μg protein	12.8 ± 0.15	7.68 ± 0.09a	9.11 ± 0.1a	5.61 ± 0.07abc
^a Significant compared to the control untreated group				
^b Significant compared to tamoxifen group				
^c Significant compared to thymoquinone group				

Table 1: Effect of different treatments on tumor tissue CAT, SOD, MDA, TNF-α, IL-6 and TGF-β1 in the studied groups.

Effect of different treatments on tissue TNF-α and IL-6

Administration of TAM and/or TQ resulted in significant decrease in tissue TNF-α and IL-6 compared to the control untreated group. The decrease in both tissue TNF-α and IL-6 was significant in the group that received TAM/TQ combination compared to the groups that received either TAM or TQ alone (Table 1).

Effect of different treatments on tissue TGF-β1

Administration of TAM and/or TQ resulted in significant decrease in tissue TGF-β1 compared to the control untreated group. The decrease in tissue TGF-β1 was significant in the group that received TAM/TQ combination compared to the groups that received either TAM or TQ alone (Table 1).

Immunohistochemical findings

Examination of the tumor tissues showed negative staining for caspase-3 (Figure 1a) and strongly positive staining for bcl-2 (Figure 2a). This was significantly improved in patients given TAM and/or TQ as evidenced by increased expression of caspase-3 (Figure 1b-d) and decreased bcl-2 expression (Figure 2b-d).

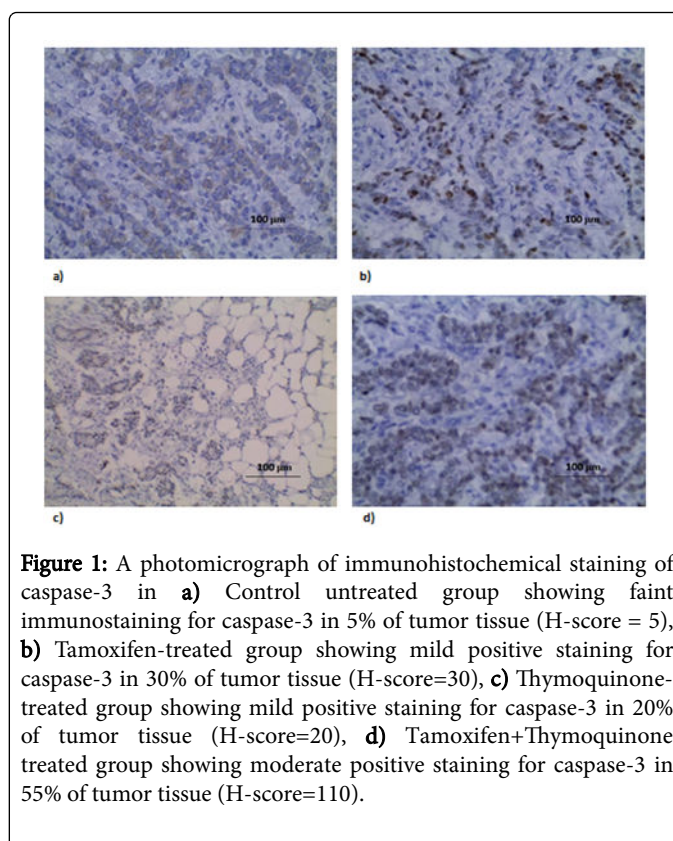


Figure 1: A photomicrograph of immunohistochemical staining of caspase-3 in **a)** Control untreated group showing faint immunostaining for caspase-3 in 5% of tumor tissue (H-score = 5), **b)** Tamoxifen-treated group showing mild positive staining for caspase-3 in 30% of tumor tissue (H-score=30), **c)** Thymoquinone-treated group showing mild positive staining for caspase-3 in 20% of tumor tissue (H-score=20), **d)** Tamoxifen+Thymoquinone treated group showing moderate positive staining for caspase-3 in 55% of tumor tissue (H-score=110).

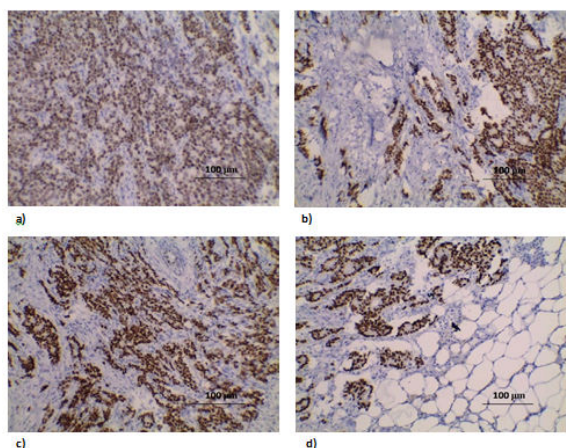


Figure 2: A photomicrograph of immunohistochemical staining of bcl-2 in **a)** Control untreated group showing strong positive staining (++++) for bcl2, **b)** Tamoxifen-treated group showing positive staining (++) for bcl-2, **c)** Thymoquinone-treated group showing positive staining (+++) for bcl-2, Tamoxifen + Thymoquinone treated group showing mild positive staining (+) for bcl2 (anti-bcl2 ×200).

Effect of different treatments on the 5-years survival rate and the relapse rate

Administration of TAM and/or TQ resulted in significant increase in the 5-years survival rate and significant decrease in the relapse rate compared to the control untreated group. This was more significant in the group that received TAM/TQ combination compared to the groups that received either TAM or TQ alone (Figures 3 and 4).

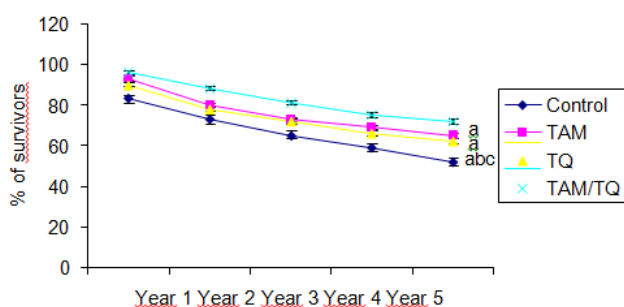


Figure 3: Effect of different treatments on the 5-years survival rate (%) [^aSignificant compared to the control untreated group, ^bSignificant compared to TAM group, ^cSignificant compared to TQ group].

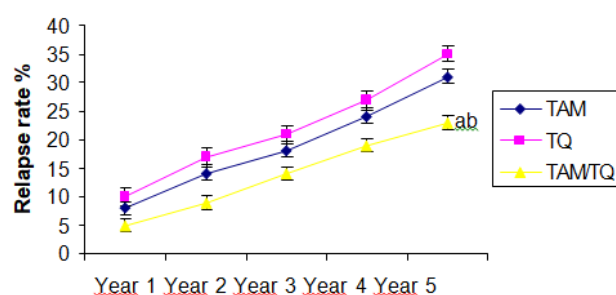


Figure 4: Effect of different treatments on the relapse rate (%) [^aSignificant compared to TAM group, ^bSignificant compared to TQ group].

Discussion

Tamoxifen (TAM) is an anti-estrogen that is considered as the first line endocrine therapy for prevention and treatment of breast cancer [20]. Its use is limited by its side effects and the development of resistance. So, recent studies have focused on finding complementary substances that can synergize the effect and decrease the side effects of TAM [21,22].

Oxidative stress is reported to play a major role in the pathogenesis of breast cancer. Oxidative stress leads to induction of nuclear DNA damage with mutations of tumor suppressor genes such as p53 that are considered as the most potent factors in carcinogenesis [23]. The mitochondrial genome also may be susceptible to oxidative damage leading to mitochondrial dysfunction which may contribute to the etiology of breast cancer [24]. These studies were in the same line with the present study where the oxidative stress that was found in the tissues of breast cancer patients was significantly improved with administration of TAM. This was in accordance with Perumal et al. [25] who attributed this improvement to that TAM has an antioxidant effect through increasing the activities of the antioxidant enzymes and decreasing lipid peroxidation products.

In the present study, administration of TQ resulted in significant improvement in the antioxidant status compared to the control untreated group. This was in agreement with Abdel-Wahab [26]. This effect was attributed to that TQ induces reduction in free oxygen radicals generated in chemical systems. Oral administration of TQ is capable of protecting several organs against oxidative damage induced by free radical-generating agents including doxorubicin-induced cardiotoxicity and carbon tetrachloride-evoked hepatotoxicity. TQ acts as scavenger of superoxide, hydroxyl radical and singlet molecular oxygen [27].

Pro-inflammatory cytokines such as TNF- α and IL-6 were thought to play a major role in the development of breast cancer. Tripsianis et al. [28] reported that IL-6 may act as an autocrine or paracrine cancer cell growth factor which contribute to recurrence and metastasis of breast cancer. TNF- α is another cytokine that is produced by tumor cells and can act as an endogenous tumor promoter [29]. Tripsianis et al. [30] suggested that the coexpression pattern of HER-2, IL-6, TNF- α and TGF- β 1 may be a useful marker for tumor extension and outcome of breast cancer. These studies were in the same line with the present study where the significant increase in tissue TNF- α and IL-6 seen in

the control untreated group was ameliorated with administration of TAM which was in accordance with Premkumar et al. [31] who reported that TAM can decrease levels of IL-1beta, IL-6, IL-8, TNF- α and vascular endothelial growth factor in breast cancer which may offer good prognosis and high efficacy of treatment.

TQ was reported to suppress the production of IFN gamma, IL-1 beta, IL-6, TNF- α and nuclear factor kappa-B activity in a dose-dependent manner [32,33]. These studies were in agreement with the present study where TQ induced significant decrease in tissue TNF- α and IL-6 compared with the control untreated group which supports the anti-inflammatory mechanism of TQ in prevention and treatment of breast cancer.

TGF- β 1 is a cytokine which plays an important role in modulation of cellular growth, differentiation, extracellular matrix formation, regulation of the immune response, apoptosis, angiogenesis and cancer progression [34]. Barcellos-Hoff and Akhurst [35] suggested that overexpression of TGF- β 1 leads to DNA damage which predisposes to breast cancer. Woods et al. [36] reported that TGF- β 1 induces IL-6 production which may have an impact on the pathogenesis of breast cancer. These studies were in agreement with the present study where the control untreated group showed significant increase in tissue TGF- β 1 which supports the important role that is played by TGF- β 1 in the progression of breast cancer.

On the other hand, Zarzynska [34] reported that TGF- β 1 has two diverse effects on breast cancer. In the early stages of breast cancer, TGF- β 1 inhibits cell cycle progression and promotes apoptosis leading to inhibition of tumor growth. Later in the disease, TGF- β 1 expression increases tumor progression and causes distant metastasis. Moreover, Lv et al. [37] found that TGF- β 1 affects Smad2 signaling which leads to epithelial-to-mesenchymal transition, increases cell invasiveness and promotes distant metastasis.

In the present study, administration of TAM resulted in significant decrease in tissue TGF- β 1 compared to the control untreated group which was in the same line with Dellè et al. [38] and Karaca et al. [39]. They reported that TAM inhibited the expression of extracellular matrix components and decreased the production of TGF- β 1 which may prevent epithelial-to-mesenchymal transition, decrease cell invasiveness and slow the progression of breast cancer.

Although multiple genes are involved in apoptosis, the key mediators of this process are the caspases. Caspase-3 plays a key role in both the death receptor pathway, initiated by caspase-8, and the mitochondrial pathway mediated by caspase-9. In addition, caspase-3 is required for apoptosis induction in response to chemotherapeutic agents [40]. Blázquez et al. [41] and Hammoud et al. [42] reported that there is decreased expression of caspase-3 in ductal breast carcinoma and that caspase-3 expression can be used as a predictive factor of response of locally advanced and metastatic breast carcinoma. This was in agreement with the present study where caspase-3 expression was markedly reduced in the control untreated group and was significantly improved after administration of either TAM or TQ.

Dias et al. [17] reported significant increase in caspase-3 expression following administration of TAM in breast cancer. This was attributed to that TAM displayed anti-proliferative properties associated with induction of apoptosis. It was reported that TQ increases caspase-3 activity in cancer cells through activation of nuclear factor-kappa B [43]. Enhanced expression of bcl-2 was identified in breast cancer where its functions are not yet well understood. Although bcl-2 has prognostic significance, its role as a predictive marker or therapeutic

target is not well defined in breast cancer. Bcl-2 has undoubtful role in restricting apoptosis and its widespread expression in breast cancer has attracted interest as a therapeutic target for many years [44]. In the present study, administration of either TAM or TQ significantly reduced the expression of bcl-2 compared to the control untreated group, hence slowed the progression and decreased invasiveness of breast cancer. Zhang et al. [45] reported that tamoxifen -induced apoptosis in breast cancer cells is related to down-regulation of bcl-2. Arafa et al. [46] found that TQ induced an increase in mitochondrial Bax protein, decrease in cytosolic bcl-2 levels and up-regulation of p53 which supports the hypothesis that TQ is a potent inducer of apoptosis in cancer cells.

In the present study, TAM/TQ combination induced significant improvement in the 5-years survival rate and the tumor antioxidant status with significant decrease in the relapse rate, tumor TNF- α , IL-6 and TGF- β 1 and alleviated the histopathological changes with significant increase in tissue caspase-3 expression and significant decrease in tissue bcl-2 compared to the control untreated group. This synergistic effect might be due to the combined antioxidant and anti-inflammatory properties of TAM and TQ together with their ability to slow the growth of tumor cells with induction of apoptosis. Wang et al. [47] reported that IL-6 production may be responsible for cancer cell resistance to TAM. In the present study, TAM/TQ combination resulted in significant decrease in tissue IL-6 compared with the use of TAM alone. So, this combination may give a hope to decrease the incidence of TAM resistance.

Conclusion

TAM/TQ combination had a better effect than each of these drugs alone in patients with breast cancer. So, this combination may represent a new therapeutic modality for management of breast cancer. Further studies are needed to explore the exact molecular mechanisms by which this combination mediates its effects.

Acknowledgement

Many thanks to the staff members of the oncology department, Al Hada Military Hospital, Taif, Saudi Arabia for their kind help for completion of this study.

References

1. Kabel AM, Baali FH (2015) Breast Cancer: Insights into Risk Factors, Pathogenesis, Diagnosis and Management. *JCRT* 3: 28-33.
2. Brody JG, Rudel RA, Michels KB, Moysich KB, Bernstein L, et al. (2007) Environmental pollutants, diet, physical activity, body size, and breast cancer: where do we stand in research to identify opportunities for prevention?. *Cancer* 109: 2627-2634.
3. Zhang Y, Lv F, Yang Y, Qian X, Lang R, et al. (2015) Clinicopathological Features and Prognosis of Metaplastic Breast Carcinoma: Experience of a Major Chinese Cancer Center. *PLoS One* 10: e0131409.
4. Santana-Davila R, Perez EA (2010) Treatment options for patients with triple-negative breast cancer. *J Hematol Oncol* 3: 42.
5. Brown K (2009) Is tamoxifen a genotoxic carcinogen in women?. *Mutagenesis* 24: 391-404.
6. Jiang Q, Zheng S, Wang G (2013) Development of new estrogen receptor-targeting therapeutic agents for tamoxifen-resistant breast cancer. *Future Med Chem* 5: 1023-1035.
7. Viedma-Rodríguez R, Baiza-Gutman L, Salamanca-Gómez F, Diaz-Zaragoza M, Martínez-Hernández G, et al. (2014) Mechanisms associated

- with resistance to tamoxifen in estrogen receptor-positive breast cancer (Review). *Oncology Reports* 32: 3-15.
8. Digianni LM, Garber JE, Winer EP (2002) Complementary and alternative medicine use among women with breast cancer. *J Clin Oncol* 20: 34S-38S.
 9. Ahmad A, Husain A, Mujeeb M, Shah Alam Khan, Abul Kalam Najimi, et al. (2013) A review on therapeutic potential of *Nigella sativa*: a miracle herb. *Asian Pacific Journal of Tropical Biomedicine* 3: 337-352.
 10. Gali-Muhtasib H, El-Najjar N, Schneider-Stock R (2006) The medicinal potential of black seed (*Nigella sativa*) and its components. *Adv Phytomed* 2: 133-153.
 11. Ng WK, Yazan LS, Ismail M (2011) Thymoquinone from *Nigella sativa* was more potent than cisplatin in eliminating of SiHa cells via apoptosis with down-regulation of Bcl-2 protein. *Toxicology In Vitro* 25: 1392-1398.
 12. Motaghd M, Al-Hassan FM, Hamid SS (2013) Cellular responses with thymoquinone treatment in human breast cancer cell line MCF-7. *Pharmacognosy Research* 5: 200-206.
 13. Buchanan CM, Buchanan NL, Edgar KJ, Little JL, Malcolm MO, et al. (2007) Pharmacokinetics of tamoxifen after intravenous and oral dosing of tamoxifen-hydroxybutenyl-B-cyclodextrin formulations. *J Pharmaceut Sci* 96: 644-660.
 14. Al-Amri AM, Bamosa AO (2009) Phase I Safety and Clinical Activity Study of Thymoquinone in Patients with Advanced Refractory Malignant Disease. *Shiraz E Med J* 10: 107-111.
 15. Higgins CP, Bachner RL, McCallister J, Boxer LA (1978) Polymorphonuclear leukocyte species differences in the disposal of hydrogen peroxide (H₂O₂). *Proc Soc Exp Biol Med* 158: 478-481.
 16. Uchiyama M, Mihara M (1978) Determination of malonaldehyde precursor in tissues by thiobarbituric acid test. *Anal Biochem* 34: 271-278.
 17. Marklund S, Marklund G (1974) Involvement of the superoxide anion radical in the autooxidation of pyrogallol and convenient assay for superoxide dismutase. *Eur J Biochem* 47: 469-474.
 18. Rao S, Krishna M, Woda B, Savas I, Fraire A (1996) Immunohistochemical detection of bcl-2 protein in adenocarcinomas and nonneoplastic cellular compartments of the lung. *Mod Pathol* 9: 555-559.
 19. Faye AM, Awad AS, El-Naa MM, Kenawy SA, El-Sayed ME (2014) Beneficial effects of thymoquinone and omega-3 in intestinal ischemia/R-induced renal dysfunction in rats. *BFOP-CU* 52: 171-177.
 20. Christinat A, Di Lascio S, Pagani O (2013) Hormonal therapies in young breast cancer patients: when, what and for how long?. *Journal of Thoracic Disease* 5: S36-46.
 21. Dias MC, Furtado KS, Rodrigues MAM, Barbisan LF (2013) Effects of Ginkgo biloba on chemically-induced mammary tumors in rats receiving tamoxifen. *BMC Complementary and Alternative Medicine* 13: 93.
 22. Yaacob NS, Kamal NN, Norazmi MN (2014) Synergistic anticancer effects of a bioactive subfraction of *Strobilanthes crispus* and tamoxifen on MCF-7 and MDA-MB-231 human breast cancer cell lines. *BMC Complementary and Alternative Medicine* 14: 252.
 23. Hakkak R, Korourian S, Melnyk S (2013) Obesity, Oxidative Stress and Breast Cancer Risk. *J Cancer Sci Ther* 5: e129.
 24. Rohan TE, Wong LJ, Wang T, Haines J, Kabat GC (2010) Do alterations in mitochondrial DNA play a role in breast carcinogenesis? *J Oncol* 2010: 604304.
 25. Perumal SS, Shanthy P, Sachdanandam P (2005) Combined efficacy of tamoxifen and coenzyme Q10 on the status of lipid peroxidation and antioxidants in DMBA induced breast cancer. *Mol Cell Biochem* 273: 151-160.
 26. Abdel-Wahab WM (2013) Protective effect of thymoquinone on sodium fluoride-induced hepatotoxicity and oxidative stress in rats. *The Journal of Basic & Applied Zoology* 66: 263-270.
 27. Nagi MN, Almakki HA (2009) Thymoquinone supplementation induces quinone reductase and glutathione transferase in mice liver: possible role in protection against chemical carcinogenesis and toxicity. *Phytother Res* 23: 1295-1298.
 28. Tripsianis G, Papadopoulou E, Anagnostopoulos K, Botaitis S, Katotomichelakis M, et al. (2014) Coexpression of IL-6 and TNF- α : prognostic significance on breast cancer outcome. *Neoplasma* 61: 205-212.
 29. Wang X, Lin Y (2008) Tumor necrosis factor and cancer, buddies or foes? *Acta Pharmacologica Sinica* 29: 1275-1288.
 30. Tripsianis G, Papadopoulou E, Romanidis K, Katotomichelakis M, Anagnostopoulos K, et al. (2013) Overall survival and clinicopathological characteristics of patients with breast cancer in relation to the expression pattern of HER-2, IL-6, TNF- α and TGF- β 1. *Asian Pac J Cancer Prev* 14: 6813-6820.
 31. Premkumar VG, Yuvaraj S, Vijayarathy K, Gangadaran SG, Sachdanandam P (2007) Serum cytokine levels of interleukin-1 β , -6, -8, tumor necrosis factor- α and vascular endothelial growth factor in breast cancer patients treated with tamoxifen and supplemented with co-enzyme Q(10), riboflavin and niacin. *Basic Clin Pharmacol Toxicol* 100: 387-391.
 32. Sá RCS, Andrade LN, de Sousa DP (2013) A Review on Anti-Inflammatory Activity of Monoterpenes. *Molecules* 18: 1227-1254.
 33. El Gazzar M, El Mezayen R, Marecki JC, Nicolls MR, Canastar A, et al. (2006) Anti-inflammatory effect of thymoquinone in a mouse model of allergic lung inflammation. *Int Immunopharmacol* 6: 1135-1142.
 34. Zarzynska JM (2014) Two Faces of TGF- β 1 in Breast Cancer. *Mediators of Inflammation* 2014: 141747.
 35. Barcellos-Hoff MH, Akhurst RJ (2009) Transforming growth factor- β in breast cancer: too much, too late. *Breast Cancer Research* 11: 202.
 36. Woods PS, Tazi MF, Chesarino NM, Amer AO, Davis IC (2015) TGF- β -induced IL-6 prevents development of acute lung injury in influenza A virus-infected CFTR-heterozygous mice. *Am J Physiol Lung Cell Mol Physiol* 308: L1136-L1144.
 37. Lv ZD, Kong B, Li JG, Qu HL, Wang XG, et al. (2013) Transforming growth factor- β 1 enhances the invasiveness of breast cancer cells by inducing a Smad2-dependent epithelial-to-mesenchymal transition. *Oncology Reports* 29: 219-225.
 38. Dellè H, Rocha JRC, Cavaglieri RC, Jr JMV, Malheiros DMAC, et al. (2012) Antifibrotic Effect of Tamoxifen in a Model of Progressive Renal Disease. *J Am Soc Nephrol* 23: 37-48.
 39. Karaca T, Gözalan AU, Yoldas Ö, Bilgin BC, Tezer A (2013) Effects of tamoxifen citrate on postoperative intra-abdominal adhesion in a rat model. *International Journal of Surgery* 11: 68-72.
 40. Chen K, Zhao H, Hu Z, Wang LE, Zhang W, et al. (2008) CASP3 polymorphisms and risk of squamous cell carcinoma of the head and neck. *Clin Cancer Res* 14: 6343-6349.
 41. Blázquez S, Sirvent JJ, Olona M, Aguilar C, Pelegri A, et al. (2006) Caspase-3 and caspase-6 in ductal breast carcinoma: a descriptive study. *Histol Histopathol* 21: 1321-1329.
 42. Hammoud H, Saleh J, Bachour M, Salmoon M, 2014. Serum Caspase-3 and Caspase-7 as Predictive Factors of Response in Locally Advanced and Metastatic Breast Carcinoma. *Journal of Cancer Therapy* 5: 584-590.
 43. Wilson AJ, Saskowski J, Barham W, Yull F, Khabele D (2015) Thymoquinone enhances cisplatin-response through direct tumor effects in a syngeneic mouse model of ovarian cancer. *Journal of Ovarian Research* 8: 46.
 44. Deng J, Letai A (2013) Priming BCL-2 to kill: the combination therapy of tamoxifen and ABT-199 in ER+ breast cancer. *Breast Cancer Research* 15: 317.
 45. Zhang GJ, Kimijima I, Onda M, Kanno M, Sato H, et al. (1999) Tamoxifen-induced Apoptosis in Breast Cancer Cells Relates to Down-Regulation of bcl-2, but not bax and bcl-XL, without Alteration of p53 Protein Levels. *Clinical Cancer Research* 5: 2971-2977.
 46. Arafa E-SA, Zhu Q, Shah ZI, Wani G, Barakat BM, et al. (2011) Thymoquinone up-regulates PTEN expression and induces apoptosis in

-
- doxorubicin-resistant human breast cancer cells. Mutation Research 706(1-2): 28-35.
47. Wang Y, Qu Y, Zhang XL, Xing J, Niu XL, et al. (2014) Autocrine production of interleukin-6 confers ovarian cancer cells resistance to tamoxifen via ER isoforms and SRC-1. Molecular and Cellular Endocrinology 382: 791-803.