

Advantages of ProRoot MTA in treating periapical lesions. Clinical cases

Marta Girdea¹, Gabriela Ciobanu², Corneliu Amariei³,
Raluca Florentina Simileanu⁴

Constanta, Romania

Summary

Clinic success in endodontic treatment, rarely exhibits 66%, if debridation is the only criterion of evaluation. Contamination of the pulpal and periradicular tissues with microorganisms generates infections. In order to preserve the vitality of the pulpal tissue or to prevent periradicular pathology, contamination gaps should be sealed to block bacterial infiltration.

Objective. The purpose of this work was to evaluate the success rate of chronic periradicular peri-odontitis, apexification and root perforation repair using MTA.

Material and method. In all cases the canals were prepared and then sterilized with calcium hydroxide for a week. At the second appointment we placed mineral trioxide aggregate (MTA) PROROOT MTA (DENTSPLY DE TREY), in the apical section of the canal system and, if the case permitted, we obturated the radicular canal.

Results. Patients were evaluated with radiographs in the first appointment, at 3 and 6 months after MTA was placed in the canal.

Conclusion. MTA allows apical bone healing and furcal perforation healing with no evident objective or subjective symptoms and signs, and it seems to be the adequate material to treat teeth reckoned as untreatable.

Key words: MTA, endodontic treatment, periradicular lesions, endodontic re-treatment.

Introduction

Clinic success in endodontic treatment rarely exhibits 66%, if debridation is the only criterion of evaluation. The importance of tridimensional obturation of root canal space and the final filling of the coronary space are two significant parts of the endodontic treatment and there is no doubt that they are a part of the clinic success [1].

Endodontic failure must quite often be retreated using different materials and methods conditioned by each case.

Contamination of the pulpal and periradicular tissues with microorganisms generates infections. In order to preserve the vitality of the pulpal tissue or to prevent periradicular pathology, contamination gaps should be sealed to block bacterial infiltration [2]. These materials exhibit direct contact with vital tissues and they must be biocompatible [3,4]. Many materials have been used to seal the gaps between the endodontic canal system and the periradicular tissues or the oral cavity. These include: the amalgam, the Super EBA, the IRM, composite

¹ Lecturer, DMD, PhD, Discipline of Endodontics, Faculty of Dental Medicine, "Ovidius" University of Constanta

² Assistant Professor, DMD, Discipline of Endodontics, Faculty of Dental Medicine, "Ovidius" University of Constanta

³ Professor, DMD, PhD, Department of Oral Health and Dental Management, Faculty of Dental Medicine, "Ovidius" University of Constanta

⁴ DMD, Constanta

resins and glass ionomer cements [5]. Major disadvantages of these materials are marginal percolation, different degrees of cytotoxicity and sensitivity to moisture [6].

This article presents 4 of 8 clinical cases treated with PROROOT MTA, one of the newest efficient materials used in certain clinical situations in endodontics, monitored within the Discipline of Endodontics, Faculty of Dental Medicine and Pharmacy, Constanta.

Recently a new endodontic material was investigated, through many types of tests concerning marginal percolation in the presence or absence of sanguine contamination, electronic microscope study concerning marginal percolation, solubility, antibacterial properties, cytotoxicity, cementum overgrowth and apical hard tissue formation.

Based on the results of such studies, mineral trioxide aggregate (MTA) appears to display a greater sealing capacity over other materials, being more biocompatible. MTA can be used as a pulp capping and pulpotomy material, to seal off root perforations. It produces apical hard tissue formation in immature teeth, as a root-end filing material in periapical surgery [7,8,9,10,11].

MTA was developed by Dr. Mahmoud Torabinejad at Loma Linda University in 1993. It is a white or gray powder of calcium trioxide, calcium aluminate, hydrophilic tricalcium silicate and some other oxides. MTA is similar to commercial Portland cement, apart from the bismuth oxide addition [12]. Ph of MTA is 12.5, which, biologically and histologically, make it similar to calcium hydroxide. Unlike other cements, which demand a completely dry field, MTA is indicated when moisture control is inadequate, without loss of its properties and it is not resorbable. In compression tests MTA is similar to Super EBA and IRM, but lesser than amalgam [13].

An ideal material for radicular repair should have non-resorbable and non-toxic bacteriostatic properties, "to heal and to offer a good apical seal" [14]. MTA is less toxic and has a powerful bacteriostatic effect with lower marginal percolation [15].

Histological exams evidenced stimulation of cementum overgrowth and hard tissue formation with minimal or absent inflammatory response [16,17].

Because of its hydrophilic properties and setting in a moisture environment, perfect isolation is counterindicated. Sometimes it is necessary to let a moisture cotton ball in the pulp chamber so that the MTA can be set in ideal conditions (4 hours are necessary).

Endodontic repair material is a hydrophilic fine powder, which sets in the presence of sterilized water. Hydration of the powder creates a colloidal gel, which solidifies to form a waterproof barrier. Its firmness is similar to hard cement.

MTA is now the ideal material used for nonsurgical treatment of radicular furcation and perforation. The chemical composition of MTA is: calcium oxide 65%, calcium silicate 21%, ferric oxide 5%, calcium aluminate 4%, calcium sulfates 2.5%, magnesium oxide 2%, sodium and potassium oxide 0.5%.

This material has no counterindication, but there are some precautions such as: the powder socket must be kept in a dry place, and after mixing the powder with liquid immediately put MTA in the canal to avoid dehydration [18,19].

Objective

The purpose of this work was to evaluate the success rate of chronic periradicular periodontitis, apexification and root perforation repair using MTA.

Material and method

We chose to use PROROOT MTA (DENTSPLY DE TREY), (*Figure 1*) observing the producer's indication. In all cases the canals were prepared and then sterilized with calcium hydroxide for a week. At the second appointment we placed MTA in the apical section of the canal system and, if the case permitted, we obturated the radicular canal.



Figure 1. PRO ROOT MTA (DENTSPLY DE TREY)

Patients were evaluated with radiographs at the first appointment, at 3 and 6 months after MTA was placed into the canal.

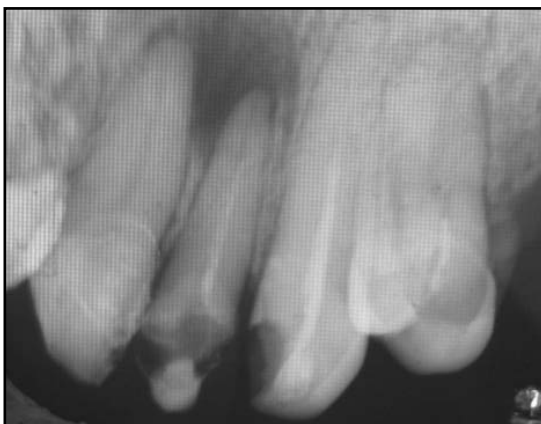

Figure 2. Incomplete root canal filling and periapical lesion in 22

Results

Clinical case no. 1

Patient C.A., 35 years old, Constanta resident, reported to the Endodontic Clinic with spontaneous and induced pain in 22 and a fluctuant palatal swelling. At clinical examination the palatal swelling measures 2 cm, but does not pass the median. Palatal mucosa was red and spread. Initial radiological exam evidences incomplete radicular obturation and a chronic periapical lesion in 22 (*Figure 2*).

At first the anesthesia was performed, the phlegmon was opened and drained with antiseptics. General oral treatment was indicated with antibiotics and analgetics. At the second appointment we continued the mechanic canal treatment, used antiseptics lavages with sodium hypochlorite 2.5% and then we placed calcium hydroxide in the canal for a week. At the next appointment the calcium hydroxide was removed with H₂O₂, and in the moisturized canals we placed MTA with Lentullo, and we placed a moisture cotton ball in the pulp chamber. After 4 hours we checked if the MTA set and we placed a temporary filling. The evolution of the periapical lesion was radiographically assessed at 1 month (*Figure 3*), 3 months (*Figure 4*) and 6 months (*Figure 5*). After 6 months with MTA treatment there was an important improvement of the periapical lesion.

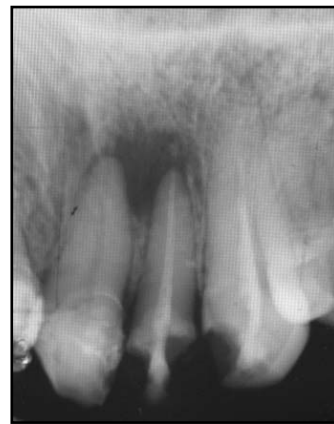

Figure 3. Radiographic image of 22 one month after MTA treatment

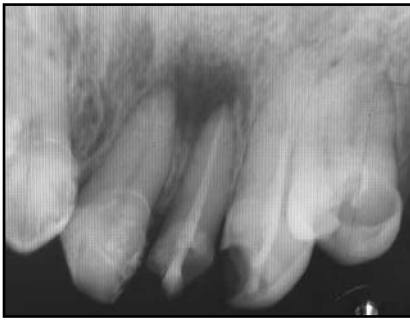

Figure 4. Radiographic image of 22, 3 months after MTA treatment

Clinical case no. 2

Patient H.P., 25 years old, Constanta resident, reported to the Endodontic Clinic for an older amalgam filling replacement in 36. Initial radiological exam displayed a radiotransparent interradicular area that spread in the whole furcal area (*Figure 6*). The objective inspection showed 36 with gray color modification, no response to thermic vitality tests and a frosted percussion sound.

Based on the radiographic aspect and the clinical exam we established the diagnosis of chronic periradicular periodontitis. The treatment consisted in removing the filling and opening the pulp chamber, debridation of the canal system, antiseptics lavages

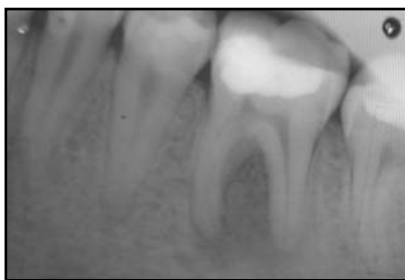

Figure 6. Furcal radiolucency in 36

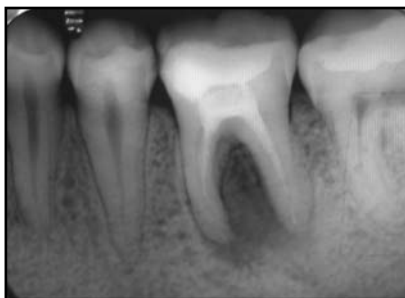

Figure 7. 36 with calcium hydroxide after one week

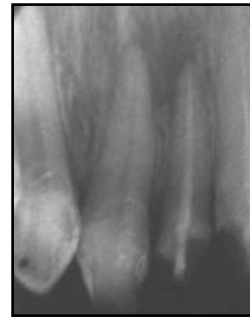

Figure 5. Radiographic image of 22, 6 months after MTA treatment

with sodium hypochlorite 2.5% and then we placed calcium hydroxide in the canal for a week (*Figure 7*). A new radiological exam was indicated. At the next appointment the calcium hydroxide was removed with H₂O₂, and placed again in the canals, then we placed MTA on the pulp chamber floor and then a moisture cotton ball in the pulp chamber. After 4 hours we checked if the MTA set and we placed a temporary filling. The third appointment: radiographic evaluation after 1 month showed an important improvement of the periradicular lesion (*Figure 8*). The next radiographic evaluation at 6 months showed almost complete healing of the periradicular bone (*Figure 9*).

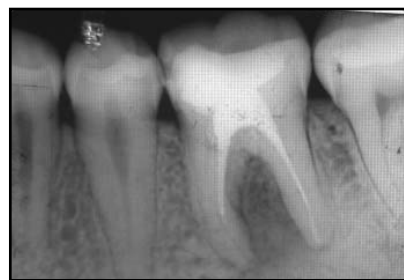

Figure 8. Important decrease of furcal radiolucency in 36 after one month with MTA treatment

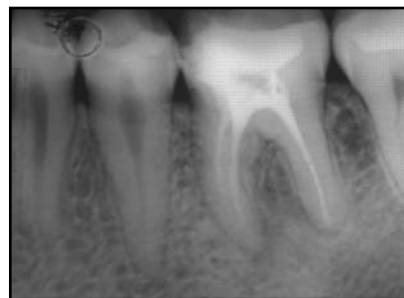

Figure 9. Almost complete healing in the furcal area of 36 after 6 months with MTA treatment

Clinical case no. 3

Patient A.C., 58 years old, Constanta resident, reported to the Endodontic Clinic for dental decays treatment and replacement of her older prostheses. The clinical and radiographic exams revealed chronic apical periodontitis in 13 (*Figure 10*). Two weeks of conservative treatment with calcium hydroxide did not improve the clinical aspect of the vestibular mucosa and a surgical procedure was indicated. The surgical procedure was performed by an oral and maxillofacial surgeon and the canal was

obtured with MTA during surgery. The initial radiographic image manifested a periapical radiotranslucency in 13 in relation with the periradicular space; the first step of the surgical intervention consisted in lifting a mucoperiosteal flap (*Figure 11*), root resection and granulation-tissue curettage (*Figure 12*), placement of MTA (*Figure 13*) and then flap suture. The radiological evaluation at one month showed bone deposition in the apical region (*Figure 14*), and at 3 months complete bone healing and no clinical symptoms (*Figure 15*).

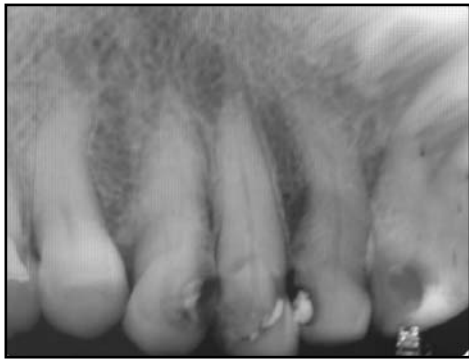

Figure 10. Chronic apical periodontitis in 13

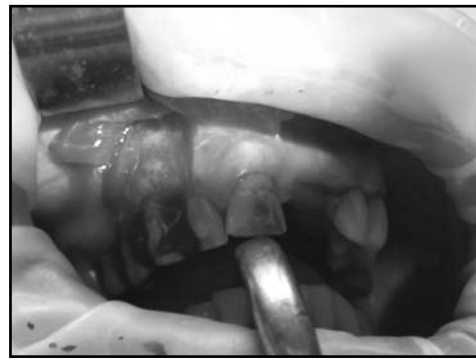


Figure 11. Mucoperiosteal flap retraction

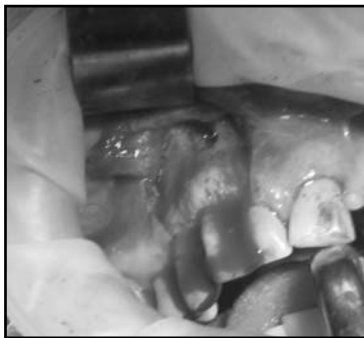

Figure 12. Root-end resection and granulation tissue curettage

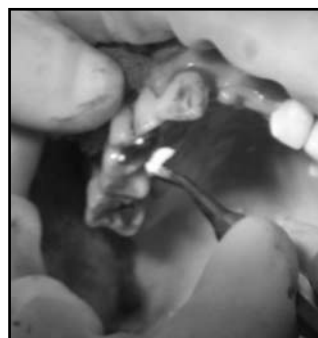

Figure 13. Inserting MTA in the apical cavity

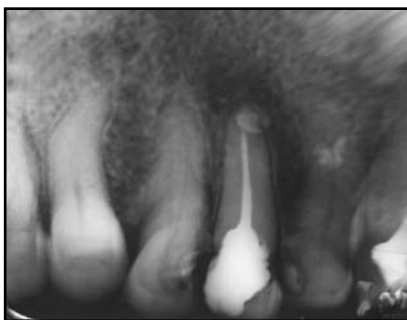

Figure 14. Radiographic image of 13 one month after MTA treatment evidences beginning of bone deposition

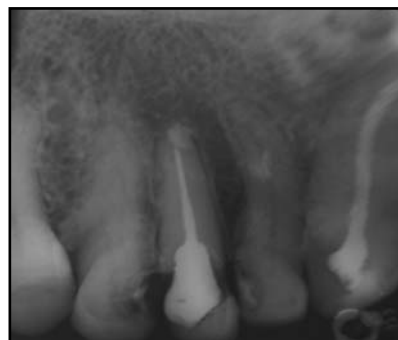

Figure 15. 13 at 3 months after MTA treatment displaying apical bone healing

Clinic case no. 4

Patient T.T., 14 years old, Constanta resident, reported to the Endodontic Clinic to continue the treatment for chronic apical periodontitis. The initial radiographic image showed an open apex and a periapical radiotranslucency in 35 (*Figure 16*). When the clinical symptoms were gone and the canal was dry and clean we obturated the canal with calcium hydroxide - Sealapex. The patient was recalled at 6, 12 and 18 months and we evaluated the evolution by radiography. After 18 months the apex was not perfectly closed, and we removed the calcium hydroxide from the canal and replaced it with MTA. Radiographic evaluation at 1 and 6 months evidenced a favorable evolution with periradicular bone healing and closing of apex; the patient is still monitored (*Figure 17*).

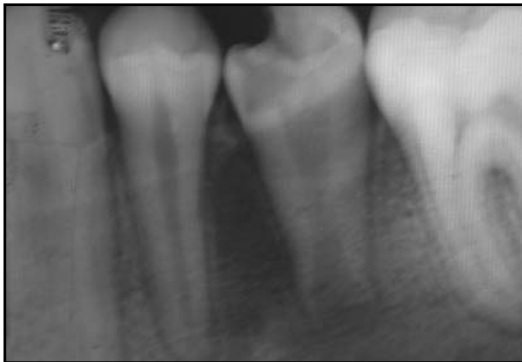

Figure 16. Initial radiographic image showing an open apex and periapical osteitic process in 35

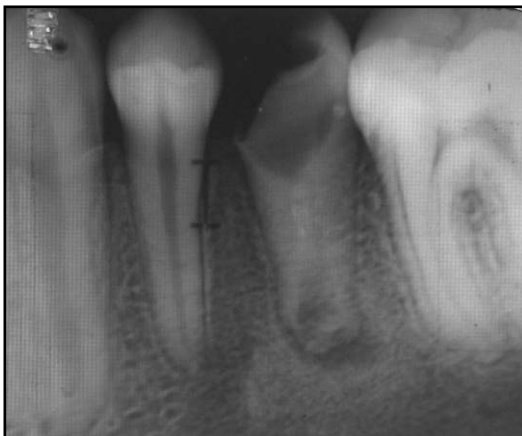

Figure 17. Radiographic image of 35, 6 months after MTA treatment, manifesting a closed apex

Discussion

Although MTA is the most investigated material in dentistry, producing remarkable results, the majority of studies were made in labs or using lab animals [20]. The research must be continued for clinical evaluation in human subjects. The importance of clinical data is compliant with the new dentistry based on evidence [21]. In this paper, we submitted certain cases in which we induced consistent healing using MTA as reparation material in a case of furcal perforation, [22] and as reparation material of defects resulted in endodontic surgery. Availability of MTA makes us reconsider the prognosis of teeth with radicular perforation.

In all cases in which mineral trioxide aggregate (MTA) was used, the patient evidenced no subjective or objective signs, these being in agreement with the studies, which show minimal or absent inflammatory response [23].

Although MTA has no specific indication in chronic periodontitis treatment, it proved to be very efficient in certain clinical cases, complete healing occurring after an important period of time. The patient in our clinical cases are monitored and recalled for clinical and radiological evaluation every 6 months for 2 years.

Based on the results obtained in these cases treated within the Discipline of Endodontics, Faculty of Dental Medicine and Pharmacy Constanta, MTA proves to be is an excellent reparation material for root perforation, apexification and endodontic reparation. Comparing the results of our survey with the results in other studies using different materials in similar cases, we perceive significant improvement in the prognoses of the teeth treated with MTA. Other studies are required to establish the long-term prognoses in consequence of MTA treatment.

Conclusions

1. MTA allows apical bone healing and furcal perforation healing with no evident objective or subjective symptoms and signs.

2. Since it induces cementogenesis, MTA can become the ideal material in treatment of specific situations in endodontics.

3. MTA is an adequate material in repairing root perforation.

4. Although MTA has no specific indication in chronic periodontitis treatment, the results obtained in certain clinical cases make us believe that MTA can be an alternative to radical surgical treatment.

5. MTA may represent the saving solution in cases thought to be untreatable.

6. Although expensive, MTA is worth the cost.

References

- Holland R et al. Mineral trioxide aggregate repair of lateral root perforations. *J Endod* 2001 Apr; **27**(4): 281-284.
- Himel VT, Alhadainy HA. Effect of dentin preparation and acid etching on the sealing ability of glass ionomer and composite resin when used to repair furcation perforations over plaster of Paris barriers. *J Endod* 1995; **21**(3): 142-145.
- Ford TR, Torabinejad M, Abedi HR, Bakland LK, Kariyawasam SP. Using mineral trioxide aggregate as a pulp-capping material. *J Am Dent Assoc* 1996; **127**: 1491.
- Mittal M, Chandra S, Chandra S. An evaluation of plaster of Paris barriers used under various materials to repair furcation perforations (in vitro study). *J Endod* 1999; **25**(5): 385-388.
- Alhadainy HA, Himel VT. An in vitro evaluation of plaster of Paris Barriers used under amalgam and glass ionomer to repair furcation perforations. *J Endod* 1994; **20**(9): 449-452.
- Alhadainy HA, Abdalla AI. Artificial floor technique used for the repair of furcation perforations: a microleakage study. *J Endod* 1998; **24**(1): 33-35.
- Aeinehchi M, Eslami B, Ghanbariha M, Saffar AS. Mineral trioxide aggregate (MTA) and calcium hydroxide as pulp-capping agents in human teeth: a preliminary report. *Int Endod J* 2003; **36**: 225.
- Lee SJ, Monsef M, Torabinejad M. Sealing ability of a mineral trioxide aggregate for repair of lateral root perforations. *J Endod* 1993; **19**(11): 541-544.
- Fischer EJ, Arens DE, Miller CH. Bacterial leakage of mineral trioxide aggregate as compared with zinc-free amalgam, intermediate restorative material, and Super-EBA as a root-end filling material. *J Endod* 1998 Mar; **24**(3): 176-179.
- Brandão CG. Propriedades físico-químicas dos cimentos endodônticos resinosos Sealer 26, e dos experimentais, Sealer plus e MBP, comparadas às do óxido de zinco e eugenol. Bauru; 1999. (Dissertação de Mestrado - Faculdade de Odontologia de Bauru da USP).
- Holland R. et al. Healing process of dog dental pulp after pulpotomy and pulp covering with mineral trioxide aggregate or Portland cement. *Braz Dent J* 2001; **12**(2): 109-113.
- Alhadainy HA. Root perforations - A review of literature. *Oral Surg* 1994; **78**(3): 368-374.
- Lee SJ, Monsef M, Torabinejad M. The sealing ability of a mineral trioxide aggregate for repair of lateral root perforations. *J Endod* 1993; **19**: 541.
- Holland R. et al. Reaction of rat connective tissue to implanted dentin tubes filled with mineral trioxide aggregate or calcium hydroxide. *J Endod* 1999 Mar; **25**(3): 161-166.
- Estrela C et al. Antimicrobial and chemical study of MTA, Portland cement, calcium hydroxide paste, Sealapex and Dycal. *Braz Dent J* 2000; **11**(1): 3-9.
- Kubo CH. Avaliação do selamento de ápices radiculares tratados com diferentes agentes desmineralizantes e retrobturados com ProRoot - MTA, mediante infiltração marginal por corante. São José dos Campos; 2001. (Dissertação de Mestrado — Faculdade de Odontologia de São José dos Campos da UNESP).
- Chau JYM, Hutter JW, Mork TO, Nicoll BK. An in vitro study of furcation perforation repair using calcium phosphate cement. *J Endod* 1997; **23**(9): 588-592.
- Chakmakchi M, Karoni C, Meliou H, Kerezoudis NP. Sealing effectiveness of white Pro-Root MTA in furcation perforations. Abstract R75. *Int Endod J* 2003; **36**: 945.
- Holland R et al. Reaction of dog's teeth to root canal filling with mineral trioxide aggregate or a glass ionomer sealer. *J Endod* 1999 Nov; **25**(11): 728-730.
- Holland R, de Souza V, Murata SS, Nery MJ, Bernabe PF, Otoboni Filho, et al. Healing process of dog dental pulp after pulpotomy and pulp covering with mineral trioxide aggregate or Portland cement. *Braz Dent J* 2001; **12**: 109.
- Faraco IM, Holland R. Response of the pulp of dogs to capping with mineral trioxide aggregate or a calcium hydroxide cement. *Dent Traumatol* 2001; **17**: 163.
- Aqrabawi J. Sealing ability of amalgam, Super-EBA cement, and MTA when used as retrograde filling materials. *Brit. dent. J.* 2000; **188**(5): 266-268.
- Karoni C, Meliou H, Kerezoudis NP, Chakmakchi M. Sealing effectiveness of white Pro-Root MTA as a root-end filling material. Abstract R26. *Int Endod J* 2003; **36**: 929.

Correspondence to: Dr. Marta Girdea, Dr. Cantacuzino Street, no. 25, Eforie Sud, Romania.
E-mail: martagirdea52@yahoo.com