

## Acute Postoperative Negative Pressure Pulmonary Edema as Complication of Acute Airway Obstruction: Case Report

Zhurda T\*, Muzha D, Dautaj B, Kurti B, Marku F, Jaho E and Sula E

Department of Anesthesiology and Intensive Care, University Trauma Hospital, Tirana, Albania

\*Corresponding author: Zhurda T, Department of Anesthesiology and Intensive Care, University Trauma Hospital, Tirana, Albania, Tel: 00355699478689; E-mail: zhurdatefik@gmail.com

Received date: Dec 26, 2015; Accepted date: Feb 10, 2016; Published date: Feb 18, 2016

Copyright: ©2016 Zhurda T, et al. This is an open-access article distributed under the terms of the Creative Commons Attribution License, which permits unrestricted use, distribution, and reproduction in any medium, provided the original author and source are credited.

### Abstract

Acute postoperative negative pressure pulmonary edema (NPPE) is a respiratory complication due to acute airway obstruction (UAO) that occurs shortly after extubation of patients who under general anesthesia (incidence 0.05 to 0.1%) Usually, this complication develops in healthy young patients, capable of generating high negative intrathoracic pressures (NIP), which is the catalyst in the pathophysiological cascade of acute pulmonary edema. Commonly presents as acute respiratory distress that requires immediate intervention. We report a case of postoperative NPPE occurred immediately after tracheal extubation in an adult patient, who underwent a minor elective orthopedic surgery under general anesthesia. After extubation, UAO due to laryngospasm was observed and the patient started desaturating rapidly. Application of positive pressure via face mask ventilation (FiO<sub>2</sub> 100%) was unsuccessful in providing effective ventilation so we decided to reintubate the patient. Soon after reintubation, there were bilateral pulmonary rales and pink frothy secretion inside the tracheal tube, compatible with NPPE. Treatment was rapidly instituted with diuretic, corticosteroid and ventilator support with added PEEP. Pulmonary edema resolved completely after 6 hours later without any complications intensive care unit.

**Keywords:** Upper airway obstruction; Laryngospasm; Negative pressure pulmonary edema

### Introduction

Acute postoperative NPPE is a rare and serious respiratory complication due to acute UAO that occurs shortly after extubation of patients who underwent general anesthesia. The incidence of NPPE has been reported to be 0.05%-0.1% of all anesthetic practices [1-6]. The true incidence may be higher than has been suggested, because of a lack of familiarity with this syndrome by anesthesiologists. It occurs most frequently in patients with laryngospasm, however, all causes of UAO may lead to NPPE [6-9].

It appears to be caused by significant NIP by patient's forced inspiration against a closed upper airway, resulting in increased blood flow into the pulmonary vasculature favoring hydrostatic transudation of fluid into the interstitial and alveolar space [7,10-13].

Clinically, NPPE usually presents with rapid onset of acute respiratory distress, pink frothy pulmonary secretions and rales on chest auscultation [1,3,12-14].

The objective of this report is to describe a case of postoperative NPPE occurred immediately after tracheal extubation, secondary to laryngospasm in an adult patient, who underwent a minor elective orthopedic surgery under general anesthesia and how we managed it.

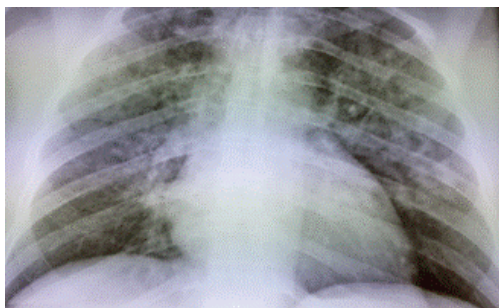
### Case Presentation

A 48 years old man, weighing 74 kg, ASA status class I, was scheduled for an open orthopedic surgery on the forearm. His medical history and preoperative physical examination did not reveal any signs of pathology. Laboratory investigations, chest x-ray and ECG were normal. He had previously undergone appendectomy under general

anesthesia approximately 8 years prior without complications and he had no known drug allergies. The patient was brought to the operating room and monitored with standard electrocardiograph, blood pressure and pulse oximetry. After adequate preoxygenation anesthesia was induced with 150 µg of Fentanyl, 500 mg of sodium Thiopental, 8 mg of Pancuronium intravenously and intubation was performed with cuffed endotracheal tube no. 7.5. Anesthesia was maintained with oxygen-isoflurane and 100 µg of Fentanyl. The tracheal intubation, anesthesia and surgical procedure were uneventful. The surgical procedures lasted 90 minutes and 800 ml of saline solution was infused to the patient. At the end of the surgery, his vital signs were stable and isoflurane was discontinued. Neuromuscular blockade was reversed with neostigmine 2.5 mg and atropine 1 mg. After recovery of motor function the patient was extubated.

Approximately two minutes after extubation, the patient developed severe difficulty breathing, the airway became obstructed, consistent with laryngospasm and pulse oximetry continued to show low SpO<sub>2</sub> level. Immediately, laryngospasm was treated by 80 mg Propofol and manual positive pressure mask ventilation with 100% inspired oxygen for a few minutes. Despite this, peripheral oxygen saturation decreased rapidly and the patient became cyanotic, so we decided to reintubate. Intravenous Propofol 150 mg and 100 mg succinylcholine were administered to facilitate orotracheal intubation. At the time of intubation, there was no evidence of laryngeal edema or gastric contents and we ventilated the patient several times using a bag-valve device. Soon after reintubation, a lot of pink frothy secretion came out of the endotracheal tube. We repeated manual ventilation and tracheal suction. On auscultation of the lungs, there were bilateral crackles in most of the lung zones. Diagnosis of NPPE secondary to post extubation laryngospasm was suspected and we administered 40 mg of Furosemide and 8 mg of Dexamethasone intravenously. The patient was placed on mechanical ventilator on

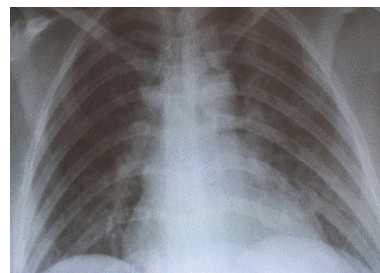
synchronized intermittent mechanical ventilation with tidal volume 540 mL, respiratory rate 14/min, with positive end-expiratory pressure (PEEP) of 5 cm H<sub>2</sub>O and FiO<sub>2</sub> 100%. After PEEP was increased to 8 cm H<sub>2</sub>O, his SpO<sub>2</sub> slowly increased to 92%. After the stabilization of respiratory status and because the patient was haemodynamically stable, we decided to transfer the patient to the intensive care unit, continuing oxygenation with 100% O<sub>2</sub> by manual ventilation. In the ICU, he was connected to ventilator on SIMV mode, with tidal volume 500 ml, respiratory rate -14/min, PEEP of 8 cm of H<sub>2</sub>O, FiO<sub>2</sub> 80% and endotracheal suction was repeated. Arterial blood gas analysis in the ICU showed pH 7.14, PaCO<sub>2</sub> 79 mmHg, PaO<sub>2</sub> 56 mmHg and base excess -6 mmol/l. A portable chest radiograph in the ICU demonstrated bilateral alveolar infiltrates in both lungs consistent with the diagnosis of pulmonary edema figure 1. In this situation, we also started to sedate the patient with Propofol and 20 mg of Furosemide was administered. Approximately 2 hours later, the secretions from the trachea began to decrease and SpO<sub>2</sub> improved to 97%. At this moment, we decided to decrease the PEPP to 5 cm H<sub>2</sub>O and FiO<sub>2</sub> to 40%. About 4 hours later, his arterial blood gas analysis showed pH 7.45, PCO<sub>2</sub> 38 mmHg, PaO<sub>2</sub> 108 mmHg, and base excess -2 mmol/l. Within 6 hours the secretions from the trachea disappeared and the chest auscultation confirmed complete recovery from pulmonary edema. Gradually, he became conscious, the cardiovascular status was stable, the arterial blood gas analysis was normal and urine output was of 2800 ml. In these conditions, we weaned off the ventilator and the patient was extubated, because of intolerance to endotracheal tube. Extubation was uneventful and a chest x-ray film after 2 hour later showed near complete resolution of the pulmonary edema figure 2. He continued to be closely monitored overnight in ICU with a simple facemask at 3-4 L/min of oxygen. In the morning, he was transferred to the orthopedic ward in stable condition.



**Figure 1:** Chest X-ray intensive care unit showed alveolar infiltrates in both lungs.

## Discussion

Acute postoperative NPPE is a rare and serious respiratory complication due to acute UAO that occurs shortly after extubation of patients who underwent general anesthesia [1,6,12,15,13]. The incidence of NPPE is reported to be 0.05 to 0.1% of all anesthetic practices according to different authors [2-5,8]. However, the true incidence is not known and may be higher than has been suggested, since it is often unrecognized or misdiagnosed [7,8]. Tami et al. for example, found the incidence of such edema to be up to 12% in all adult patients who experience acute UAO [4].



**Figure 2:** Chest X-ray 8 hours postoperatively showing near complete resolution of the alveolar opacities.

It has been widely reported that young healthy individuals, who are able to generate significant negative intrathoracic pressure have an increased risk of developing NPPE [4,9,16].

The first clinical description of NPPE associated with UAO was reported in 1977 by Oswalt [1]. In 1990, Lang et al. published a comprehensive review on the subject and concluded that the pathogenesis was multi factorial. Since then, NPPE has been reported mainly by anesthesiologists as a consequence of postoperative UAO [8,10-12,15,17,18].

It is classified in two types in the literature: type I is associated with forceful inspiratory effort in the context of an acute UAO, whereas type II occurs after treatment of a chronic partial airway obstruction [1,4, 14].

It occurs most frequently in patients with laryngospasm, however, all causes of UAO may lead to NPPE [6-9].

Risk factors for developing UAO in the postoperative setting include: male gender, obesity with obstructive sleep apnea, anatomically difficult intubations, presence of airway lesions, oral and maxillofacial surgery, bilateral vocal cord paralysis and premature extubation [4,6,10,12-14].

Other presentations have been described after vigorous suction during bronchoscopy, foreign body aspiration, endotracheal tube or laryngeal mask obstruction and biting of the endotracheal tube in the absence of protection with an oral cannula [7,19,20].

Although the exact pathophysiology of NPPE secondary to UAO is still heavily debated, two different mechanisms have been suggested to explain its pathogenesis.

One theory is that postobstructive NPPE caused by significant fluid transudation due to changes in intrathoracic pressure, which is the catalyst in the pathophysiological cascade. The high NIP is generated in the chest when a patient attempts to inspire against a closed glottis. Normal pleural inspiratory pressures range from -2 to -5 cm of water, whereas during severe episodes of UAO, NIP exceeds a maximum of -140 cm H<sub>2</sub>O [4,5,7,10].

The short-term drop in intrathoracic pressure increases the venous return to the right side of the heart, which in turn increases pulmonary venous pressure. This increase in pressure in the venous circulation creates a hydrostatic transpulmonary gradient with fluid moving from high pressure (pulmonary venous system) to low pressure (pulmonary interstitium and airspaces) and pulmonary edema then develops [1,2,8,11-13,20].

The second theoretical mechanism is that the mechanical stress developed from respiration against an UAO may induce breaks in the alveolar epithelial, resulting in increased pulmonary capillary permeability and edema formation and sometimes alveolar hemorrhage [1,2,7,8,12,19]. Although, other factors as hypoxia, hypercarbia, and hyperadrenergic state may also play an important role in its development [11-13].

Clinical manifestations of NPPE usually present immediately after extubation, although delayed onsets have been reported. It has been seen that 80% of pulmonary edema occur at the time of or following the relief of UAO [2,6,9,11-13].

NPPE usually presents with rapid onset of acute respiratory distress with signs of shortness of breath, agitation, progressive oxygen desaturation, pink frothy pulmonary secretions and rales on chest auscultation [1,3,12,14]. The chest radiograph typically shows bilateral diffuse interstitial and alveolar infiltrates, suggestive of pulmonary edema [1,3,14]. All these signs were observed in the present case.

Differential diagnosis of NPPE secondary to post extubation laryngospasm must also include other causes including: cardiogenic or neurogenic edema, iatrogenic volume overload, aspiration of gastric contents, bronchospasm or anaphylaxis and postoperative resuscitization [6,10,12,19,20].

All these causes were considered in the present case. In our case, pulmonary edema developed a few minutes after relief of UAO at the time of reintubation.

He had no history of cardiac or neurogenic disease in the past, thus our suspicion for cardiogenic or neurogenic edema were excluded. In other hands the patient had no history of drug allergies and there were no other features of anaphylaxis. We also observed no cardiovascular instability as well as no dermatologic signs of allergic origin. So the possibility of hypersensitivity reaction or anaphylaxis were excluded.

The diagnosis of aspiration was excluded because at the time of reintubation, the aspiration of mouth secretions and pulmonary secretions did not contain any visible gastric contents. Fluid overload was unlikely, because he was given only 800 ml of solution during the surgery.

In the presented case, we believe that incomplete neuromuscular recovery or residual effect of pancuronium could have precipitated the UAO and clinical presentation of NPPE.

Treatment of NPPE is directed toward reversing hypoxia and decreasing the fluid volume in the lungs. Some patients may need only supplemental oxygen, continuous positive airway pressure, guided by physical examination and arterial blood gas analysis. In some cases, reintubation and mechanical ventilation are required to maintain airway patency and adequate oxygenation. The addition of PEEP will lead to improve oxygenation and rapid resolution of pulmonary edema [8,9,13,14,17,19].

Some authors suggest the use of intravenous diuretics in an attempt to decrease the intravascular volume and alter Starling's equation in favor of intracapillary filtration and edema resolution despite no conclusive evidence of clinical benefits [9,12,14,19]. In our patient, Furosemide was beneficial with a good symptomatic and radiological resolution.

The use of steroids is controversial but, since there might be physical damage to the alveoli and capillaries caused by HIP, steroid administration might be useful [4,19].

In our anesthesiology department, this is the only documented case of NPPE. The management of our case was on similar lines with oxygenation, sedation, diuretic, steroid and mechanical ventilation that were reported by other authors in the literature [5,9,10,13,14,17,20].

The rapidity of onset of symptoms of pulmonary edema followed by clinical and radiological resolution within 8 hours confirm a diagnosis of PPE in the present patient.

NPPE has a good prognosis because the event is self-limited [8,14]. Many reports suggest that symptoms in NPPE improve gradually even if no aggressive treatment because the patients are usually healthy [4,7,20]. In other hands there have been reports of fatal evolution due to acute respiratory distress syndrome and multiple organ, attributed to a delay in diagnosis [8,21]. The gentle airway manipulation during induction, careful oropharyngeal suctioning and extubation at the right time are very important to prevent and decrease the incidence of NPPE [18-21].

We also think that it is very important to be vigilant in patients who experience postanesthetic laryngospasm and to monitor for longer than the usual in the postoperative period.

In summary, NPPE secondary to UAO is an infrequent event that can complicate low morbidity surgery. Urgent diagnosis and treatment are necessary for a favorable evolution, as it happened in our case. In this context, it is very important that clinicians to keep in mind a high index of suspicion for NPPE as a complication of UAO, when a patient develops respiratory distress and hypoxia, especially in healthy patients after general anesthesia.

## References

1. Oswalt CE, Gates GA, Holmstrom MG (1977) Pulmonary edema as a complication of acute airway obstruction. *JAMA* 238: 1833-1835.
2. Patton WC, Baker CL Jr (2000) Prevalence of negative-pressure pulmonary edema at an orthopaedic hospital. *J South Orthop Assoc* 9: 248-253.
3. Lang SA, Duncan PG, Shephard DA, Ha HC (1990) Pulmonary oedema associated with airway obstruction. *Can J Anaesth* 37: 210-218.
4. Tami TA, Chu F, Wildes TO, Kaplan M (1986) Pulmonary edema and acute upper airway obstruction. *Laryngoscope* 96: 506-509.
5. Gluecker T, Capasso P, Schnyder P, Gudinchet F, Schaller MD, et al. (1999) Clinical and radiologic features of pulmonary edema. *Radiographics* 19: 1507-1531.
6. Udeshi A, Cantie SM, Pierre E (2010) Postobstructive pulmonary edema. *J Crit Care* 25: 508.
7. Krodel DJ, Bittner EA, Abdunour R, Brown R, Eikermann M (2010) Case scenario. Acute postoperative negative pressure pulmonary edema. *Anesthesiology* 113: 200-207.
8. Koh MS, Hsu AA, Eng P (2003) Negative pressure pulmonary oedema in the medical intensive care unit. *Intensive Care Med* 29: 1601-1604.
9. Kallet RH, Daniel BM, Gropper M, Matthay MA (1998) Acute pulmonary edema following upper airway obstruction: Case reports and brief review. *Respir Care* 43: 476-480.
10. Lemyze M, Mallat J (2014) Understanding negative pressure pulmonary edema. *Intensive Care Med* 40: 1140-1143.
11. Bajwa SS, Kulshrestha A (2012) Diagnosis, prevention and management of postoperative pulmonary edema. *Ann Med Health Sci Res* 2: 180-185.
12. Tarrac SE (2003) Negative pressure pulmonary edema a postanesthesia emergency. *J Perianesth Nurs* 18: 317-323.
13. Patel AR, Bersten AD (2006) Pulmonary haemorrhage associated with negative-pressure pulmonary oedema: a case report. *Crit Care Resusc* 8: 115-116.

14. Mamiya H, Ichinohe T, Kaneko Y (2009) Negative pressure pulmonary edema after oral and maxillofacial surgery. *Anesth Prog* 56: 49-52.
15. McConkey PP (2000) Postobstructive pulmonary oedema a case series and review. *Anaesth Intensive Care* 28: 72-76.
16. Jain R, Kumar M, Haq ZA, Banerjee A (2013) Negative pressure pulmonary oedema following use of ProSeal LMA. *Indian J Anaesth* 57: 188-190.
17. Deepika K, Kanaan CA, Barrocas AM, Fonseca JJ, Bikazi GB (1997) Negative pressure pulmonary edema after acute upper airway obstruction. *J Clin Anesth* 9: 403-408.
18. Louis PJ, Fernandes R (2002) Negative pressure pulmonary edema. *Oral Surg Oral Med Oral Pathol Oral Radiol Endod* 93: 4-6.
19. Goli AK, Goli SA, Byrd RP Jr, Roy TM (2003) Spontaneous negative pressure changes: an unusual cause of noncardiogenic pulmonary edema. *J Ky Med Assoc* 101: 317-320.
20. Fremont RD, Kallet RH, Matthay MA, Ware LB (2007) Postobstructive pulmonary edema: a case for hydrostatic mechanisms. *Chest* 131: 1742-1746.
21. Adolph MD, Oliver AM, Dejak T (1994) Death from adult respiratory distress syndrome and multiorgan failure following acute upper airway obstruction. *Ear Nose Throat J* 73: 324-327.