

Aberrometric Outcomes of Intrastromal Corneal Ring Segment (KeraRing 355) Implantation Using PocketMaker Microkeratome in Patients with Keratoconus

Khosrow Jadidi¹, Farhad Nejat², Aliagha Alishiri¹, Leila Janani³, Abdollah Pashaei Abdollah Pashaei⁴ and Seyed Aliasghar Mosavi^{1*}

¹Department of Ophthalmology, Baqiyatallah University of Medical Sciences, Tehran, Iran

²Department of Ophthalmology, Bina Eye Hospital Research Center, Tehran, Iran

³Department of Biostatistics, School of Public Health, Iran University of Medical Sciences, Tehran, Iran

⁴School of Rehabilitation, Shahid Beheshti University of Medical Sciences, Tehran, Iran

*Corresponding author: Seyed Aliasghar Mosavi, Department of Ophthalmology, Baqiyatallah University of Medical Sciences, Tehran, Iran, Tel: 00982122605915; E-mail: a_a_mosavi@hotmail.com

Received date: January 04, 2017; Accepted date: February 25, 2017; Published date: March 01, 2017

Copyright: ©2017 Jadidi K, et al. This is an open-access article distributed under the terms of the Creative Commons Attribution License, which permits unrestricted use, distribution, and reproduction in any medium, provided the original author and source are credited.

Abstract

Objective: To evaluate aberrometric changes in corneas with keratoconus implanted with intrastromal corneal ring segment (Keraring 355) during a 3-months follow-up.

Design: Prospective, consecutive case series

Methods: In this interventional study, 22 eyes of 21 keratoconic patients with mean age of 29 ± 6 years who underwent KeraRing 355 intrastromal corneal ring insertion using a Pocket Maker Microkeratome for channel creation and completed at least three months of follow-up were included. Uncorrected visual acuity (UCVA), best spectacle corrected visual acuity (BSCVA), refractive outcome, Orbscan finding and corneal aberrations were assessed.

Results: Three months postoperatively, Low order aberration (defocus and astigmatism) decreased significantly ($P < 0.001$). No statistically significant changes were detected in total RMS, trefoil, secondary trefoil and coma. Moreover, a statistically significant increase in quadrefoil, secondary coma, spherical aberration and secondary spherical was found. In term of visual outcomes, the mean UCVA (in LogMAR value) improved significantly from 0.75 ± 0.33 to 0.31 ± 0.23 and the mean BSCVA improved (from 0.31 ± 0.16 to 0.19 ± 0.15) ($P < 0.05$). The mean spherical refractive error improved (from -1.37 ± 1.36 to 0.01 ± 2.47) and the mean cylindrical refractive error decreased significantly (from -3.8 ± 1.03 to -2.1 ± 1.27) ($P < 0.001$). Also, the mean keratometry value decreased from 47.61 ± 2.03 to 42.50 ± 2.76 . Conclusion: KeraRing 355 implantation provided significant improvement in low order aberrations but was not effective in high order aberrations (HOA) in low/moderate keratoconus patients. However, UCVA, BCVA, spherical and cylindrical refractive error and keratometry results improved significantly.

Keywords: Keratoconus; KeraRing 355; Aberration

Introduction

Keratoconus, the most common primary corneal ectasia, is a bilateral asymmetric corneal degeneration which accompanies with local corneal thinning and occurs mostly in inferior and central part of the cornea [1]. Initiating in puberty, Keratoconus (KCN) often progresses until fourth decade of life [2]. Affecting all ethnic groups equally, KCN usually causes high myopia and irregular astigmatism which results in poor quality of vision [2,3]. Based on disease severity, many treatment modalities exist including glasses and contact lenses for mild to moderate disease [2-4] while corneal graft preserved for more advanced disease [5]. High costs, need to long follow-ups, long periods for visual rehabilitation, risks of graft rejection or infection, wound dehiscence and suture-related problems make corneal grafts preserved for the last therapeutic choice by many ophthalmologists [6].

In advent of alternative treatments, intrastromal ring implantation have been introduced which improves visual acuity and optical

aberrations and also corrects refractive errors and mean keratometric data [7-14].

Initially, intracornial ring has been used to treat high myopia [15], but incision-related complication resulted in arrival of intrastromal segments to treat KCN in 2000 which achieved FDA approval in 2004 [14-18]. Different types of intrastromal segments include Intacs, Ferrara and Keraring [19]. Intacs segment consist of two semicircle PMMA-made parts with the arcuate length of 150 degrees and an axial hexagonal shape [20]. Ferrara segment shapes triangularly which helps to reduce stare and is made of PMMA and CQ acrylic [21]. Lack of variability in Ferrara and Intacs designs are of their disadvantages which resulted to the arrival of new generation of intrastromal segments named Keraring.

Considering design, material and thickness, Keraring mostly looks similar to Ferrara consisting of 4 arcute length 90, 120, 160 and 210 degrees. Arcuate length variability results in better correction of astigmatism in keratoconus patients [22]. Recently, Mediphaco Company introduced their new products with its distinguishing feature of 355 degree arcuate length named Keraring 355 [23]. Based on segment thickness, intrastromal segments separates bands of

corneal tissue resulting in shortening of central arcuate length. Shortening effect leads to later need for corneal graft, conservation of central visual field, safety, reversibility and stability [23-25].

To our knowledge, there are limited studies investigating Keraring 355 with high attention in KCN treatment. On the other hand, most studies measuring corneal aberration used topography [26-33]. In the present study, we investigated Keraring intrastromal segment effect on optical aberrations in KCN treatment using wave front analyzer which evaluates 80,000 points compared to topography evaluating 6,144 points [34].

Methods

In this prospective interventional case series 22 eyes were included. All patients had mild to moderate Keratoconus. They underwent intrastromal Keraring 355 implantation at Bina eye hospital located in Teheran from October 2014 until October 2015. The study followed the tenets of the Declaration of Helsinki. Written informed consent was obtained in all cases. Keratoconus diagnosis was established by the corneal pachymetry readings and combination of computerized video keratography of the anterior and posterior corneal surfaces (Orbscan IIz) [34,35]. Patients with mild and moderate KCN based on the Amsler-Krumiech classification [36]. with visual acuity (UCVA) not better than 20/50, mean keratometry between 45 and 52 D, maintaining minimum central corneal thickness of 360 microns, nipple type keratoconic eyes with clear central cornea, age between 21 and 49 years with no other ocular and systemic disease other than keratoconus and contact lens intolerance were included in our study. Contact lens wear was discontinued three weeks prior to the exams. Exclusion criteria were history of vernal and atopic keratoconjunctivitis, positive pregnancy test, breast-feeding, history of keratorefractive surgery on the operative eye, history of corneal stromal disorders, patients with dry eye, immunosuppressive drugs users, advanced keratoconus with inferior corneal thinning less than 360 m, hyperopia, and patients with severe ocular and systemic pathologies. To prevent potential biases, surgery was done by just one surgeon (Kh.J). Data measurement was done by the same person and the same calibrated device before and after surgery. Surgery method remained the same for all patients. Patients were fully explained about the research purpose and steps. Informed written consent was taken from the patients. They were able to quit the study whenever they wanted.

In all eyes, we measured corneal derived wavefront analyses (Keratron-Scout, OPTIKON2000, Rome, Italy) and ocular aberrometry (Ocular Wavefront Analyzer, SCHWIND eye-tech-solutions GmbH & Co.KG), manifest refraction and visual acuity (UCVA and BSCVA respectively). Uncorrected visual acuity and best spectacle corrected visual acuity were measured using Snellen charts and transformed into logMAR units for statistical analysis. To evaluate the changes in corneal aberrations, High order optical aberrations including defocus error, astigmatism, comma error, Trefoil error, spherical error and quatrefoil error, secondary comma error, secondary Trefoil error, secondary astigmatism error and secondary spherical error were measured using Schwind Amaris aberrometer. All the measurements were repeated three months after surgery.

Surgical technique

Keeping a complete sterilized situation, the intervention was done by an expert surgeon (KH.J) under local anesthesia using propracaine

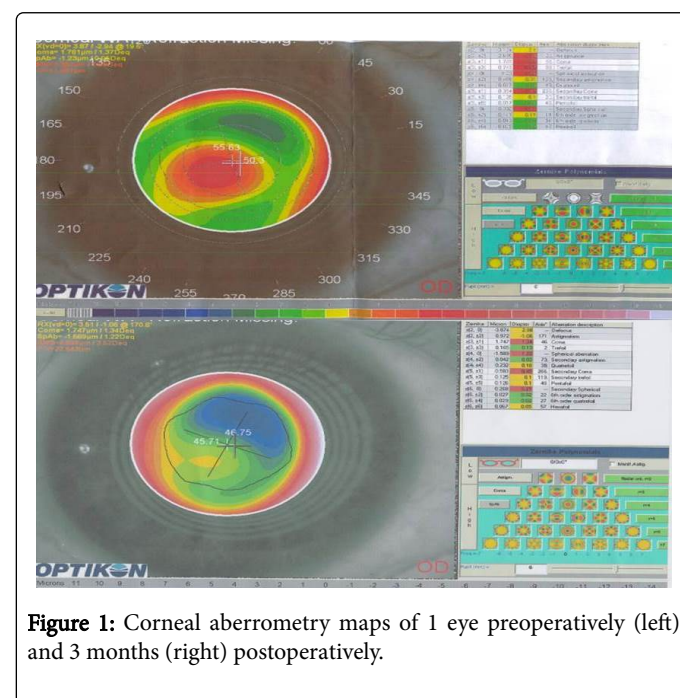
hydrochloride 0.5%. As fully explained by Daxer 31, an 8.5 millimeter stromal pocket was made by a pocket maker microkeratome (Dioptex GmbH) at the depth of 300 microns. Microkeratome contained a suction ring and a surgical blade. First, suction ring was fixed over the cornea, and then a stromal pocket was made using surgical blade. The incision site was adjacent to the steep axis of the cornea. At the next step, suction ring was removed and Keraring 355 was implanted in the pocket. The surgeon chose the suitable thickness for Keraring 355 based on a pre-designed nomogram; a custom-surgeon nomogram [26]. The cornea was covered by a silicone-hydrogel bandage contact lens (Bausch & Lomb). Subsequently, patients were recommended to use topical chloramphenicol and betamethasone every 6 hours for 1 week and topical lubricants continued for one month.

Statistical analysis

All data were analyzed using SPSS 18. Mean, standard deviation and tables were used to describe the data. Comparing means of variables, Paired-T test were used. The normality testing for Gaussian distribution was performed using the shapiro-wilk normality test. In the case of non-Gaussian data distribution, the data were compared using the Wilcoxon matched-pairs signed rank test.

Results

22 eyes of 21 patients (17 men, 4 women) were studied. Mean age of patients was 29 ± 6 years ranging from 21 to 48 year. In this case series, no intraoperative or postoperative complications occurred. The mean of UCVA significantly improved from 0.75 ± 0.33 LogMAR before surgery to 0.31 ± 0.23 LogMAR and the mean BSCVA improved (from 0.31 ± 0.16 to 0.19 ± 0.15) after surgery ($P < 0.05$) (Table 1). Cylindrical refractive error showed significant decrease from -3.80 ± 1.03 to -2.1 ± 1.27 . ($P < 0.001$) (Table 1). As the minimum, maximum and mean of keratometric data showed significant decrease after the surgery; a significant flattening effect was observed in our study ($P < 0.001$) (Table 1).



Mean of defocus error improved significantly from 1.44 ± 2.03 to -2.77 ± 2.76 microns ($P < 0.001$) (Table 1). Mean of secondary comma error increased significantly from 0.31 ± 0.14 to 0.67 ± 0.27 . ($P < 0.001$) (Table 1). Mean of spherical error increased significantly from $-0.04 \pm$

0.35 to -1.49 ± 0.79 . ($P < 0.001$) (Table 1). Furthermore, Figure 1 compares the preoperative corneal aberrometry maps and the maps 3 months after implantation; the maps show significant surgically induced change.

p-value	Months Postoperative	Preoperative	
<0.001	0.31 (0.23)	0.75 (0.33)	UCVA (LogMAR) Mean (SD)
0.041	0.19 (0.15)	0.31 (0.16)	BCVA (LogMAR) Mean (SD)
0.041	0.01 (2.47)		Sphere (D) Mean (SD)
<0.001	-2.1(1.127)	3.8(1.03)	Cylinder (D) Mean (SD)
0.024	-1.52 (2.77)	-3.49 (1.61)	SEQ (D) Mean (SD)
<0.001	43.61 (2.74)	50.22 (2.45)	K.Max Value (D) Mean (SD)
<0.001	41.39(2.74)	45.22(1.88)	K. Min Value (D) Mean (SD)
<0.001	42.50 (2.76)	47.61 (2.03)	K. Mean Value (D) Mean (SD)
0.251	5.09 (1.85)	5.57 (1.56)	RMS (μm) Mean (SD)
<0.001	1.88 (2.32)	-0.91 (1.45)	Defocus (μm) Mean (SD)
0.664	0.71 (0.32)	0.76 (0.31)	Trefoil (μm) Mean (SD)
0.007	0.33 (0.25)	0.19 (0.09)	Quatrefoil (μm) Mean (SD)
0.181	0.26 (0.15)	0.46 (0.27)	SA (μm) Mean (SD)
<0.001	0.51 (0.22)	0.25 (0.10)	SC (μm) Mean (SD)
<0.001	0.24 (0.14)	0.05 (0.04)	SS (μm) Mean (SD)
0.431	0.10 (0.07)	0.14 (0.07)	ST (μm) Mean (SD)
<0.001	1.14 (0.59)	0.21 (0.11)	Spherical (μm) Mean (SD)
<0.001	-1.39 (0.95)	-4.47 (1.59)	Astigmatism (μm) Mean (SD)
0.096	2.04 (0.79)	1.88 (0.85)	Comma (μm) Mean (SD)

SD: Standard Deviation; D: Diopter; SC: Secondary Comma; ST: Secondary Trefoil; SA: Secondary Astigmatism; SS: Secondary Spherical Significances are based on Wilcoxon signed-rank test. $P < 0.05$.

Table 1: Comparison between Preoperative and postoperative visual outcomes, K-values and aberrometry outcomes.

Discussion

Our results show that UCVA, BCVA, spherical and cylindrical refractive error improved three month after intrastromal keraring 355 implantation. Spherical and cylindrical refractive error decreased 1.4 diopter and 1.7 diopter respectively. These results are in line with other studies [8,30-38]. UCVA improved three lines which is compatible with studies of Vega estrad et al. [31] and Gharibieh et al. [38]. Likewise, BSCVA improved one line which is well-matched with other studies [33-38].

Maximum, minimum and mean of keratometric data decreased 7.00, 4.30 and 5.50 Diopter after surgery respectively. These results are in agreement with studies of Jadidi et al. [30], Jabbarvand et al. [33], Alio et al. [29] and Sansanayudh et al. [32]. The similar results in these studies can be related to similar 6 mm diameter and larger arc of rings. Many other studies found less decrease in Keratometric data which is probably because of smaller arcs and larger diameters of implanted rings [8,14,32-38]. As mentioned by Jabbarvand et al. [29] and Alio et

al. [25], it seems that complete rings could correct corneal curvature more effectively because of their stronger arc-shortening effect. Second order defocus error decreased 4.21 microns after intervention. This amount accords with spherical refractive error. Also, second order astigmatism decreased 2.48 microns which accords with cylindrical refractive error. Although clinically and statistically insignificant, Comma error increased a little after intervention. However it was consistent with some studies [8,30-32].

Jabbarvand [29] and Haddad [28] found significant decrease for this type of error in their studies. The difference can be attributable to differences in mean of follow-up times and implanted rings, and difference in surgical technics, differences in stages of KCN between study population and different techniques to measure errors. Notwithstanding that in Jabbarvand study, patients with larger pupil than 5.5 millimeter were excluded from the study. Furthermore, In spite of secondary comma error, Trefoil error did not increase significantly, which is consistent with study by Jabbarvand et al. [29]. In the face of Vega-Estrada et al. [27] and Shayebak et al. [14] studies

showing significant decrease in comma-like errors, our result shows little statistically insignificant increase in this type of error. This inconsistency can be attributable to different study population as just advanced KCN patients were included in the mentioned studies.

Considering primary spherical error, As Pinero et al. [19] mentioned, mechanical method to implant intrastromal segment can result in negative increase in spherical error, our study shows increase in a negative direction which accords with previous studies [25-28]. Secondary spherical error and quadrafoil also showed significant increase despite secondary astigmatism error which remained the same. Additionally, Spherical-like errors Showed significant increase which can be attributable to Keraring effect on corneal sphericity. We suggest use of larger diameter to decrease this effect.

At last, aberrometric parameters, RMS of all types of errors, showed insignificant decrease which is consistent with little improvement in BCVA. Our study had some limitations including small sample size, short follow-up duration, and lack of control group and mechanical method of surgery. In conclusion, this study demonstrated that there was a significant change after intrastromal Keraring 355 implantation and BCVA, spherical and cylindrical refractive error and keratometric data but complex and little effect on aberrometric parameters that is worthy of further study.

Acknowledgment

The authors would like to acknowledge the staff of the Eye Clinic in Bina Eye Hospital Research Center for their invaluable help during the entire process of this study.

References

- Gomes JA, Tan D, Rapuano CJ, Belin MW, Ambrósio R Jr, et al. (2015) Global consensus on keratoconus and ectatic diseases. *Cornea* 4: 359-369.
- Rabinowitz YS (1998) Keratoconus. *Surv Ophthalmol* 42: 297-319.
- Weed KH, MacEwen CJ, Giles T, Low J, Mc Ghee CN (2008) The Dundee university Scottish Keratoconus study: demographics, corneal signs, associated diseases, and eye rubbing. *Eye* 22: 534-541.
- Bilgin LK, Yilmaz S, Araz B, Yüksel SB, Sezen T (2009) 30 years of contact lens prescribing for keratoconic patients in Turkey. *Cont Lens Anterior Eye* 32: 16-21.
- Funnell CL, Ball J, Noble BA (2006) Comparative cohort study of the outcomes of deep lamellar keratoplasty and penetrating keratoplasty for keratoconus. *Eye (Lond)* 20: 527-532.
- Olson RJ, Pingree M, Ridges R, Lundergan ML, Alldredge C Jr, et al. (2000) Penetrating keratoplasty for keratoconus: a long-term review of results and complications. *J Cataract Refract Surg* 26: 987-991.
- Torquetti L, Berbel RF, Ferrara P (2009) Long-term follow-up of intrastromal corneal ring segments in keratoconus. *J Cataract Refract Surg* 35: 1768-1773.
- Piñero DP, Alio JL, El Kady B, Coskunseven E, Morbelli H, et al. (2009) Refractive and aberrometric outcomes of intracorneal ring segments for keratoconus: mechanical versus femtosecond-assisted procedures. *Ophthalmol* 116: 1675-1687.
- Ferrara P, Torquetti L (2009) Clinical outcomes after implantation of a new intrastromal corneal ring with a 210-degree arc length. *J Cataract Refract Surg* 35: 1604-1608.
- Coskunseven E, Kymionis GD, Tsiklis NS, Atun S, Arslan E, et al. (2008) One-year results of intrastromal corneal ring segment implantation (KeraRing) using femtosecond laser in patients with keratoconus. *Am J Ophthalmol* 145: 775-779.
- Shetty R, Kurian M, Anand D, Mhaske P, Narayana KM, et al. (2008) Intacs in advanced keratoconus. *Cornea* 27: 1022-1029.
- Ertan A, Ozkicil E (2008) Effect of age on outcomes in patients with keratoconus treated by Intacs using a femtosecond laser. *J Refract Surg* 24: 690-695.
- Ertan A, Kamburoglu G (2008) Intacs implantation using femtosecond laser for management of keratoconus: comparison of 306 cases in different stages. *J Cataract Refract Surg* 34: 1521-1526.
- Shabayek MH, Alio' JL (2007) Intrastromal corneal ring segment implantation by femtosecond laser for keratoconus correction. *Ophthalmology* 114: 1643-1652.
- Nosé W, Neves RA, Burris TE, Schanzlin DJ, Belfort Júnior R (1996) Intrastromal corneal ring: 12-month sighted myopic eyes. *J Refract Surg* 12: 20-28.
- Burris TE (1998) Intrastromal corneal ring technology: results and indications. *Curr Opin Ophthalmol* 9: 9-14.
- Colin J, Cochener B, Savary G, Malet F (2000) Correcting keratoconus with intracorneal rings. *J Cataract Refract Surg* 26: 1117-1122.
- <http://www.accessdata.fda.gov/scripts/cdrh/cfdocs/cfhde/hde.cfm?id=H040002>
- Piñero DP, Alio JL (2010) Intracorneal ring segments in ectatic corneal disease - a review. *Clin Exp Ophthalmol* 38: 154-167.
- Ertan A, Colin J (2007) Intracorneal rings for keratoconus and keratectasia. *J Cataract Refract Surg* 33: 1303-1314.
- Siganos D, Ferrara P, Chatzinikolas K, Bessis N, Papastergiou G (2002) Ferrara intrastromal corneal rings for the correction of keratoconus. *J Cataract Refract Surg* 28: 1947-1951.
- Hamdi IM (2011) Preliminary results of intrastromal corneal ring segment implantation to treat moderate to severe keratoconus. *J Cataract Refractive Surgery* 37: 1125-1132.
- <http://www.mediphacos.com/medico/>
- Silvestrini T, Mathis M, Loomas B, Burris TA (1994) Geometric model to predict the change in corneal curvature from the intrastromal corneal ring (ICR). *Invest Ophthalmol Vis Sci* 35: 2023.
- Alió JL, Artola A, Hassanein A, Haroun H, Galal A (2005) One or 2 Intacs segments for the correction of keratoconus. *J Cataract Refract Surg* 31: 943-953.
- Jadidi K, Mosavi SA, Nejat F, Naderi M, Janani L, et al. (2015) Intrastromal corneal ring segment implantation (keraring 355°) in patients with central keratoconus: 6-month follow-up. *J Ophthalmol* 2015: 916385.
- Vega-Estrada A, Alio JL, Brenner L, Burguera N (2013) Outcomes of intrastromal corneal ring segments for treatment of keratoconus: Five-year follow-up analysis. *J Cataract Refract Surg* 39: 1234-1240.
- Haddad W, Fadlallah A, Dirani A, El Rami H, Fahd D, et al. (2012) Comparison of 2 types of intrastromal corneal ring segments for keratoconus. *J Cataract Refract Surg* 38: 1214-1221.
- Vega-Estrada A, Alio JL, Brenner LF, Javaloy J, Plaza Puche AB, et al. (2013) Outcome Analysis of Intracorneal Ring Segments for the Treatment of Keratoconus Based on Visual, Refractive, and Aberrometric Impairment. *Am J Ophthalmol* 155: 575-584.
- Alio JL, Pinero DP, Daxer A (2011) Clinical Outcomes after Complete Ring Implantation in Corneal Ectasia Using the Femtosecond Technology: A Pilot Study. *Ophthalmology* 118: 1282-1290.
- Pinero DP, Alio JL, El Kady B, Pascual I (2010) Corneal aberrometric and refractive performance of 2 intrastromal corneal ring segment models in early and moderate ectatic disease. *J Cataract Refract Surg* 36: 102-109.
- Sansanayudh W, Bahar I, Kumar NL, Shehadeh-Mashour R, Ritenour R, et al. (2010) Intrastromal corneal ring segment SK implantation for moderate to severe keratoconus. *J Cataract Refract Surg* 36: 110-113.
- Perez-Merino P, Ortiz S, Alejandre N, De Castro A, Jimenez-Alfaro I, et al. (2014) Ocular and optical coherence tomography-based corneal aberrometry in keratoconic eyes treated by intracorneal ring segments. *Am J Ophthalmol* 157: 116-127.

-
34. Maeda N, Klyce SD, Smolek MK (1995) Comparison of methods for detecting keratoconus using videokeratography *Arch Ophthalmol* 113: 870-874.
 35. Rabinowitz YS, Rasheed K, Yang H, Elashoff J (1998) Accuracy of ultrasonic pachymetry and videokeratography in detecting keratoconus. *J Cataract Refract Surg* 24: 196-201.
 36. Amsler M (1965) Early diagnosis and microsymptoms. *Ophthalmologica* 149: 438-446.
 37. Jabbarvand M, Salamatrad A, Hashemian H, Mazloumi M, Khodaparast M (2013) Continuous intracorneal ring implantation for keratoconus using a femtosecond laser. *J Cataract Refract Surg* 39: 1081-1087.
 38. Gharaibeh AM, Muhsen SM, AbuKhader IB, Ababneh OH, Abu-Ameerh MA, et al. (2012) KeraRing intrastromal corneal ring segments for correction of keratoconus. *Cornea* 31: 115-120.