

Abdominal Tuberculosis: a Benign Differential Diagnosis for Peritoneal Carcinosis: Report of a Case

Dagmar Schweinfurth¹, Reinholdt-Dieter Baier¹ and Sven Richter^{1,2*}

¹Department of General, Visceral and Vascular Surgery, Fürst-Stirum-Klinik, Bruchsal, Germany

²University of Saarland, Medical Faculty, Homburg/Saar, Germany

*Corresponding author: Sven Richter, Department of General, Visceral and Vascular Surgery, Allgemein-, Fürst-Stirum-Klinik, Gutleutstraße 1-14, D-76646 Bruchsal, Germany, Tel: +49725170857401; Fax: +49725170857409; E-mail: sven.richter@kliniken-lk.de

Rec date: September 08, 2013, Acc date: October 28, 2014, Pub date: November 10, 2014

Copyright: © 2014 Schweinfurth D, et al. This is an open-access article distributed under the terms of the Creative Commons Attribution License, which permits unrestricted use, distribution, and reproduction in any medium, provided the original author and source are credited.

Abstract

Tuberculosis remains a challenge in medicine despite availability of antibiotic treatments. Latent tuberculosis is found in a third of the world's population. Abdominal tuberculosis is a rare condition in high-income countries, with peritoneal tuberculosis and splenic abscess occurring even less frequently, even in countries with higher prevalence of abdominal tuberculosis. We describe such an uncommon constellation of peritoneal tuberculosis and splenic abscess. Our case demonstrates the challenges in diagnosing abdominal tuberculosis, providing the caveat that tuberculosis should be kept in mind whenever unspecific findings occur in abdominal imaging or unusual surgical findings. In our case, thorough history-taking - including explicit questionings about tuberculosis exposition decades ago - provided the only lead pointing towards the correct interpretation of otherwise unspecific findings. In our case, tuberculosis as a differential diagnosis to peritoneal carcinosis was only implied after histopathological evaluation, followed by timely diagnostics for pulmonary involvement and potential infectiousness.

Keywords: Abdominal tuberculosis, Peritoneal carcinosis, Surgery

Introduction

Tuberculosis remains a challenge in world medicine despite the availability of antibiotic treatments; even more challenging it is nowadays due to development of resistant types. According to WHO, latent tuberculosis is found in a third of the world's population. The worldwide mortality due to tuberculosis in 2012 was 1.3 million, mainly in low- and middle-income countries. Nonetheless, high-income countries are not spared from tuberculosis, including the multi-drug resistant types [1].

Prevalence of tuberculosis in Germany was estimated to 7.8 (3.3-14) per 100000 in 2012. While the typical site is pulmonary, whereby 28% were smear-positive and 47% were smear-unknown, the remaining 28% of new cases reported were extrapulmonary [1]. In patients with abdominal tuberculosis, multiple sites are affected in 27%, while 36 to 47% show concomitant pulmonary involvement upon further examination [2]. Peritoneal tuberculosis accounts for 2% of abdominal manifestations [2].

Splenic abscess and peritoneal tuberculosis are rarely seen in high-income countries, they are not frequent in countries with higher prevalence of abdominal tuberculosis. In the present report, we describe such an uncommon constellation.

Case Report

Clinical history

A 59-year-old woman presented with mild fatigue and mild upper left abdominal and left flank pain for more than five weeks. Four weeks earlier, she had received Gentamicin and Ciprofloxacin as an

empirical treatment for pyelonephritis. As symptoms persisted, an MRI had been conducted, which revealed a large space occupying lesion in the spleen. This lesion was walled, having hypo- and hyperintense areas, dilating the splenic capsule towards the upper left side (Figure 1).

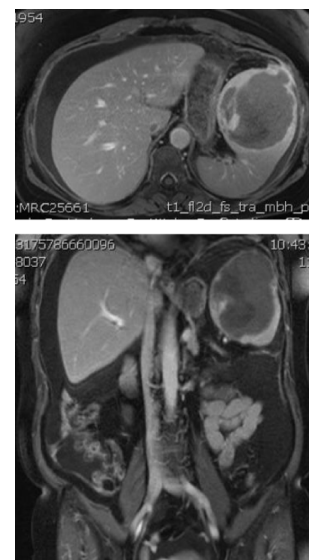


Figure 1: T1-weighted MRI scan, revealing a large splenic lesion with hypo- and hyperintense areas

The patient had a history of hypertension and hypothyroidism which were controlled under treatment (Ramipril 5 mg, Carvedilol 25 mg, Levothyroxine 100 µg). Fourteen months prior to this current

presentation, juxtaglenoidal 360° arthrolysis had been performed due to calcific tendinosis of the left infraspinatus tendon. No other previous health problems were reported. She had no unusual travel or work history; she was born and had been living in Germany.

Initial investigations showed an elevated CA-125 level (734 U/ml (<=35 U/ml)) and a slightly elevated HCG level (6.8 mU/ml(<5 mU/ml)). Immunoblot assays (Western Blot IgG) from blood serum samples for *Echinococcus granulosus* and *E. multilocularis* were negative, and complete blood count showed no eosinophilia. A high level of cholesterol was found in the ascites sample (151 mg/dl), the serum-ascites albumine gradient was >1.1. No other significant laboratory alterations were seen: all common laboratory parameters, e.g. for liver function (ALAT, ASAT, GGT, INR) or kidney function (creatinine, urea) were within normal range. Blood count showed normal values, and only CRP levels were slightly elevated (21.1 mg/l, normal value: <5 mg/l).

Treatment

Diagnostic and therapeutic splenectomy was indicated with the radiological differential diagnoses of splenic abscess or a large echinococcal cyst, which would have accounted for the patient's symptoms.

Intra-operatively, upon opening of the abdomen, disseminated lesions resembling milky-white semolina grains were seen on the entire small intestine and omentum; the latter formed an omental cake and adhered to the spleen. A few of these lesions were also seen on the spleen and liver capsule and in the parietal peritoneum of abdomen and pelvis. The uterus and ovaries appeared normal. Two operating surgeons and a gynecologist opined that the appearance of these lesions was consistent with peritoneal carcinosis. Splenectomy and omentectomy were performed. The volume of ascites removed was about 3 litres. Adhesions of intestinal loops caused by the lesions were mobilised.

Histopathology

Histopathological examination showed no signs of malignancy. Instead, necrosis with incipient organisation and chronic florid granulomatous inflammation of the omentum with granulomas were observed, suggesting the possibilities of sarcoidosis, tuberculosis, or atypical mycobacteriosis (Figure 2). Further tests revealed negative PCR for tuberculosis in the samples which had unfortunately been formalin-fixed as tuberculosis had not been suspected. PCR for atypical mycobacteria was also negative. There was no evidence of a ruptured dermoid cyst to account for the granulomatous inflammation.

Further radiological and laboratory investigations cANCA, pANCA and ACE were within normal reference range, arguing against sarcoidosis. Interferon-gamma release assay (quantiferon test) was positive, leaning towards *M. tuberculosis* infection.

A post-operative thorax CT scan revealed no evidence of either sarcoidosis or tuberculosis. Re-evaluation of the MRI showed no signs of a ruptured dermoid cyst. Abdominal sonography eight days post-operative revealed no unusual findings after splenectomy and omentectomy apart from a small left renal cyst; especially, there were no signs of peritoneal thickening, lymphadenopathy, or ascites.

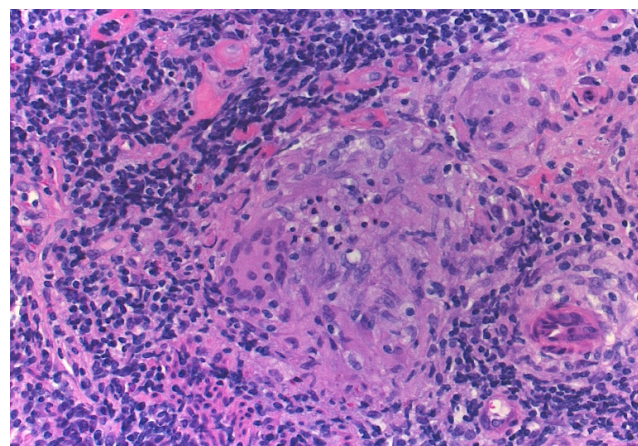


Figure 2: HE stain of epithelioid granuloma with Langerhans type giant cells

Clinical course post-surgery

Postoperatively, the patient reported swift remission of the initial pain. CT of the thorax revealed pleural effusions and left lower lobe infiltrates, suggesting a clinically inapparent hospital acquired pneumonia, which was treated with Piperacillin and Tazobactam successfully for five days. The patient remained asymptomatic. She was discharged eleven days post-operatively under the impression of peritoneal carcinosis with unknown primary tumour, pending histopathological examination results. As soon as histopathological examination results and relevant investigation results were available and leaned towards abdominal tuberculosis, the patient was referred to a tertiary centre for further management.

It also later emerged that her brother had been diagnosed with tuberculosis during his military service, as had her sister, both more than thirty years ago. Records also showed that her sister had been registered with the local health authorities, and the family's accommodation had been decontaminated and declared clear.

Follow-up MRI at 11th and 28th week after surgery showed an inconspicuous abdomen after splenectomy and omentectomy. No more ascites was seen. Hence, no further diagnostic or therapeutic interventions were considered necessary.

Clinico-radiologic-pathologic diagnosis

Abdominal tuberculosis with tuberculous splenic abscess and peritoneal tuberculosis.

Discussion

Diagnosis of abdominal tuberculosis can be quite challenging, especially when the clinical presentation and laboratory investigations are not suggestive of this disease. This may lead to errors in diagnostic and therapeutic procedures.

Our patient in this case report displayed two uncommon morphological entities, namely splenic abscess and peritoneal tuberculosis. Splenic abscess is rare in otherwise healthy patients, and mostly occurs in patients with neoplasia, immunodeficiency,

hemoglobinopathies, trauma, metastatic infection, splenic infarction and diabetes. Patients usually present not only with upper left abdominal pain, but also fever and leucocytosis [3]. Mostly, it develops as an opportunistic infection due to *Klebsiella pneumoniae*, *Escherichia coli*, and *Staphylococcus aureus* [4]. Tuberculous splenic abscesses are generally rare, and extremely rare in immuno-competent patients. A few case reports recorded otherwise healthy patients who presented with left abdominal discomfort, similar to our patient [5-7]. Generally, splenectomy is the gold standard treatment for symptomatic splenic abscess, but it is often fraught with complications caused by concomitant diseases of the patients. Ultrasound- or CT-guided drainage has been suggested as an alternative for high-risk patients [3,4].

One of the radiological differential diagnoses in this case was echinococcal cysts. Echinococcal cysts may cause similar symptoms. Echinococcus is not excluded by negative serology, late echinococcal cysts may appear partly solid, or partially or fully calcified, displaying a similar morphology as in our case [8]. In late or inactive echinococcal cysts, antihelminthic treatment is not indicated, and the decision for a surgical option is guided by symptoms of the patients [8]. Diagnosis of peritoneal tuberculosis is less straightforward because the radiological morphology is unspecific [2,7]. Peritoneal thickening may be noticed upon very careful examination in ultrasound and MRI scans [9]. In CT morphology, three patterns of peritoneal tuberculosis are defined: "wet type" with significant amounts of ascites (90%) "fibrotic fixed type" with omental mass, matted bowel loops and mesentery, and less ascites (7%), "dry type" with dense adhesions, fibrous peritoneal reaction, and caseous nodules (3%). Coexistence with lymphadenopathy (seen more commonly in tuberculosis than sarcoidosis), ascites, splenomegaly and splenic lesions may point to the diagnosis of abdominal tuberculosis [9]. Peritoneal carcinosis and abdominal sarcoidosis are important differential diagnoses [2].

There are several case studies resembling our case, which describe peritoneal tuberculosis mimicking advanced ovarian cancer due to similar clinical presentation and serology [10-13]. The clinical and serological constellations described resemble that of our patient, namely ascites, omental thickening, irregularities in the abdomen and pelvis, and elevated CA-125 level; however, none of these patients had a splenic lesion. Bacteriological cultures were negative, but the patients responded to tuberculostatic treatment.

For definitive diagnosis of tuberculosis, the cultivation of mycobacteria from specimens (e.g. ascites or sputum) in Löwenstein-Jensen medium is gold standard, followed by PCR and evidence of caseating granulomas [2]. Further differentiation and testing for antibiotic susceptibility should follow, once positive cultures are established.

However, clinical chemistry and cultivation of ascites samples often prove inconclusive in peritoneal tuberculosis. A low serum-ascites albumin gradient is sensitive, but not specific. The same applies to CA-125. Adenosine desaminase activity has been reported sensitive and specific when >30 mU/l, but not in patients with concomitant liver cirrhosis. PCR yields good results in smear-positive patients, with less sensitivity in smear-negative cases. Ziehl-Neelsen stain for acid-fast bacteria is positive in less than 3% of ascites specimens, while cultures are positive in only 35% (requiring four to eight weeks of incubation). Thus, histopathological assessment of tissue samples, acquired through laparoscopy if necessary has been suggested as the best diagnostic method [12]. Frozen-section analysis is also recommended by the authors of the case studies quoted above [13].

As our case report shows, laboratory tests for detection and proof of tuberculosis may be poor. After all, only the Interferon-gamma release assay was positive for tuberculosis. Especially when the initial clinical diagnosis may lead to a totally different entity like peritoneal carcinosis, not all necessary examinations will be pursued in time. In this context, we have to admit that collecting pus from the splenic abscess - before putting the specimen into formalin - would most certainly have led to an earlier correct diagnosis of *M. tuberculosis*. Therefore, collecting pus or intra-operative smears should not be forgotten in good surgical practice.

Once the diagnosis is clear, treatment for non-MDR tuberculosis in immune-competent patients is straightforward. Treatment of abdominal tuberculosis is mainly conservative, comprising a 'short course' of six months, typically including two months of Rifampicin, Isoniazid, Pyrazinamide and Ethambutol followed by four months of Isoniazid and Rifampicin, or longer courses. Patient compliance and clinical monitoring for side effects are important to ensure favourable outcomes. Surgery is indicated for management of complications (obstruction, strictures, fistulae, perforation, hemorrhage). In patients with tuberculous splenic abscess, splenectomy is the treatment of choice, with standard vaccinations for overwhelming post-splenectomy infection (OPSI) prophylaxis two weeks after surgery. In asymptomatic patients with isolated serological positivity and no remaining morphological correlates following surgical therapy of abdominal tuberculosis, close clinical and radiological surveillance may suffice, depending on the individual risk profile.

Conclusion

Abdominal tuberculosis is a condition rarely seen in high-income countries. As the diagnosis remains challenging, tuberculosis should be kept in mind whenever unspecific findings occur in abdominal imaging or unusual surgical findings. In our case, thorough history-taking-including explicit questioning about tuberculosis exposition decades ago - provided the only lead pointing towards the correct interpretation of otherwise unspecific findings. Abdominal tuberculosis as a differential diagnosis to peritoneal carcinosis should remain until histopathological evaluation is finalized. Because pulmonary involvement and hence potential infectiousness is present in more than 40% of patients with abdominal tuberculosis, pulmonary imaging and serological testing should be initiated as soon as reasonable suspicion arises to allow timely treatment and isolation precautions.

Trite as it sounds, while it may not be lupus, unless proven otherwise, it may always be tuberculosis.

References

1. WHO 2013. Global tuberculosis report 2013
2. Lee WK, Van Tonder F, Tartaglia CJ, Daga C, Cazzato RL, et al. (2012) CT appearances of abdominal tuberculosis. *Clin Radiol* 67: 596-604.
3. Conzo G, Docimo G, Palazzo A, Della Pietra C, Stanzione F, et al. (2012) The role of percutaneous US-guided drainage in the treatment of splenic abscess. Case report and review of the literature. *Ann Ital Chir* 83: 433-436.
4. Tung CC, Chen FC, Lo CJ (2006) Splenic abscess: an easily overlooked disease? *Am Surg* 72: 322-325.
5. Mishra H, Pradeep R, Rao GV, Anuradha S, Nageshwar Reddy D (2013) Isolated tuberculosis of the spleen: A case report and review of literature. *Indian J Surg* 75: 235-236.

-
6. Pratap V, Sinha SP, Bumb SS, Bhaskar DJ (2014) Splenic tuberculosis: a rare entity. *BMJ Case Rep* 2014.
 7. Sinha AK, Agarwal A, Agrawal CS, Mishra A, Dabadi K (2006) Tuberculous splenic abscess--a case report and review of literature. *Indian J Pathol Microbiol* 49: 270-272.
 8. Kern P (2003) Echinococcus granulosus infection: clinical presentation, medical treatment and outcome. *Langenbecks Arch Surg* 388: 413-420.
 9. von Hahn T, Bange FC, Westhaus S, Rifai K, Attia D, et al. (2014) Ultrasound presentation of abdominal tuberculosis in a German tertiary care center. *Scand J Gastroenterol* 49: 184-190.
 10. Bilgin T, Karabay A, Dolar E, DevelioŦlu OH (2001) Peritoneal tuberculosis with pelvic abdominal mass, ascites and elevated CA 125 mimicking advanced ovarian carcinoma: a series of 10 cases. *Int J Gynecol Cancer* 11: 290-294.
 11. Piura B, Rabinovich A, Leron E, Yanai-Inbar I, Mazor M (2003) Peritoneal tuberculosis--an uncommon disease that may deceive the gynecologist. *Eur J Obstet Gynecol Reprod Biol* 110: 230-234.
 12. Protopapas A, Milingos S, Diakomanolis E, Elsheikh A, Protogerou A, et al. (2003) Miliary tuberculous peritonitis mimicking advanced ovarian cancer. *Gynecol Obstet Invest* 56: 89-92.
 13. Gurbuz, Karateke A, Kabaca C, Kir G, Cetingoz E (2006) Peritoneal tuberculosis simulating advanced ovarian carcinoma: is clinical impression sufficient to administer neoadjuvant chemotherapy for advanced ovarian cancer? In *Int J Gynecol Cancer* 16: 290-294.