

# A Survey on Radiographic Prescription Practices in Dental Implant Assessment among Dentists in Kerala, India

Prabhath Ramakrishnan<sup>1</sup>, Faris Mohammed Shafi<sup>2</sup>, Anil Subhash<sup>2</sup>, Ajeya Kumara EG<sup>3</sup>, Jithesh Chakkarayan<sup>4</sup>, Janisha Vengalath<sup>1</sup>

<sup>1</sup>Department of Oral Medicine and Radiology, Kannur Dental College, Anjarakandy, Kannur, Kerala, India. <sup>2</sup>Department of Prosthodontics, Kannur Dental College, Anjarakandy, Kannur, Kerala, India. <sup>3</sup>Department of Periodontics, Kannur Dental College, Anjarakandy, Kannur, Kerala, India. <sup>4</sup>Department of Orthodontics and Dentofacial Orthopaedics, Kannur Dental College, Anjarakandy, Kannur, Kerala, India.

## Abstract

**Aims and objectives:** To conduct a survey of the current radiographic prescription practices among implant practitioners in the state of Kerala, India.

**Methods:** 300 dentists were interviewed by employing a questionnaire which enquired about the radiographic evaluation methods prescribed by practitioners in implant site assessment in their implantology practice. Other reasons for choosing particular imaging modalities were also enquired. The data collected from the survey was analysed using Epi-Info 7.1.3 software.

**Results:** Around 87.33% of the dentists prescribed only OPG for the implant site assessment and only 4.66% ordered Orthopantomograph (OPG) in combination with an Intra Oral Periapical Radiograph (IOPAR) and 4.33% ordered OPG with Computed Tomography (CT). Only 0.02% of the practitioners ordered CT as a single examination and 1% ordered it in conjunction with other modalities. 0.066% individuals ordered IOPAR as the sole imaging modality and none of them ever prescribed conventional or Cone beam computed tomography.

**Conclusions:** Our study has conclusively proven that most of the dentists prescribe OPG followed by a combination of OPG and Intraoral periapical radiographs in their implant practices. Many of them were not aware and did not follow the American Academy of Oral and Maxillofacial Radiology, European Academy of Dentomaxillofacial Radiology, European Association of Osseointegration and International Congress of Oral Implantology recommendations regarding cross-sectional imaging.

*Key Words: Dental implants, Radiography, Dentist practice patterns, OPG, Computed tomography*

## Introduction

Dental Implants, widely used in the replacement of edentulous spaces, have grown by leaps and bounds in the past few decades, with newer advances in the field accelerating at lightning speeds. The way dental practitioners have taken to this technological advancement in oral rehabilitation is really impressive. One of the main criteria in the assessment of success in oral implants has been radiographic measurement of marginal bone loss [1-3]. In the clinical practice of implantology, radiographic imaging assists in the preoperative assessment and treatment planning, surgical procedure, post operative evaluation and the ongoing implant functioning. Many types of radiographic modalities are used in implantology namely, Intra-Oral Periapical Radiography (IOPAR), Orthopantomography (OPG), occlusal radiography, Conventional tomography, Computed Tomography (CT) and Cone-Beam Computed Tomography (CBCT). Usually, it is the practicing clinician who decides which modality best suits him and his needs [4-10].

Beason and Brooks [11] surveyed the different imaging modalities used in implant site assessment in a random group of practitioners in Michigan, USA and the results showed that 95% of them take OPG for at least 80% patients and 90% said they never prescribed any form of cross-sectional imaging contrary to the recommendations put forward by the professional bodies like American Academy of Oral and Maxillofacial Radiology (AAOMR), European Academy

of Dentomaxillofacial Radiology (EADMFR), European Association of Osseointegration (EAO) and International Congress of Oral Implantology (ICOI) [12-16]. A survey conducted by Sakakura et.al, surveyed a group of dentists in Brazil by using a questionnaire about radiographic prescription practices and it showed that 68.3% of dentists prescribed only OPG for dental implant assessment. Only 7.2% of practitioners prescribed conventional tomography or CT as a single examination, and 10.1% ordered it in combination with other imaging modalities. The main reasons given for prescribing OPG were broad coverage and cost (86.4%) [17]. Recent studies by McCrea and Shelley et.al conducted in the United Kingdom have also not shown any contradicting results [6,18].

The recent position paper on the use of radiology in dental implantology put forward by the AAOMR recommended that cross-sectional imaging be used for the assessment of all dental implant sites and that currently CBCT is the imaging method of choice at present to gain this diagnostic information [13].

There is extremely scarce literature worldwide regarding the radiographic prescription practices among implant practitioners worldwide and whether they adhere to the recommendations put forward by professional bodies like AAOMR, EADMFR, EAO and ICOI [13-16].

It is also a cause for concern that there is absolutely no literature of any sort reported from the Indian sub-continent, where thousands of implants are placed each year, regarding

Corresponding author: Prabhath Ramakrishnan, Department of Oral Medicine and Radiology, Kannur Dental College, Anjarakandy, Kannur, Kerala, India; Tel: 00919746556779; e-mail: prabathrk@gmail.com

radiographic prescription practices for implant site assessment. Hence, we thought it prudent to conduct such a survey among implant practitioners.

### Materials and Methods

300 dentists were randomly interviewed by employing a questionnaire which enquired about the radiographic evaluation methods prescribed by practitioners in pre and post operative assessment in their implantology practice. All of the dentists involved in the study were specialised or trained in implant dentistry and included specialities like Oral and Maxillofacial Surgery (35.4%), Prosthodontics (32.8%), General Dentistry (12%), and Periodontology (19.8%). A close ended questionnaire was given to the dentists participating in the study and data collected regarding the radiographic prescription practices for pre operative implant assessment and follow up, like OPG, Conventional tomography, CT, and OPG. They were also asked regarding whether combination modalities were used in assessment. The questionnaire also enquired about the reasons for the particular imaging modality being chosen like Cost, Patient radiation dose, Broad coverage of facial bones and teeth, availability, and measurement precision. The data was also analysed to ascertain if a combination of these reasons affected their judgement in choosing the imaging modality. The data collected from the survey was analysed using Epi-Info 7.1.3 software and the results determined.

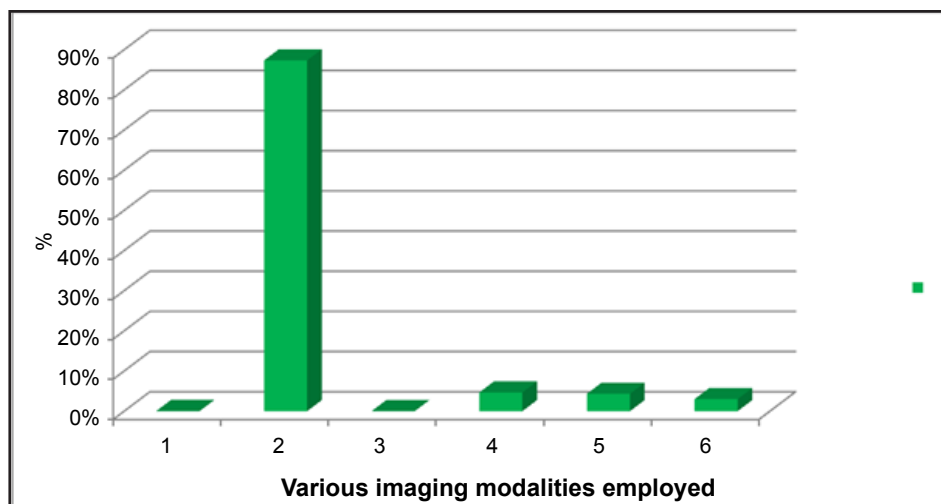
### Results

The results are exhibited in *Figures 1 and 2* and in *Table 1*. The radiographs most commonly prescribed were the OPG (87.33%) followed by OPG plus IOPAR (4.66%). The next modality was a combination of OPG and CT scans (4.33%) followed by a combination of OPG+IOPAR+CT (1%). Approximately 0.02% of the practitioners prescribed CT scan as the sole imaging modality and only a meagre 0.066% used IOPAR alone for assessment (*Figure 1*). None of the practitioners mentioned opting for conventional tomography or Cone Beam Computed Tomography (CBCT). When enquired about the reason for prescribing certain modalities the main reason was broad coverage of facial bones and teeth (65.33), followed by measurement precision (7.33%), availability (5.66%), Cost (1.66%) and patient radiation dose (1%) (*Figure 2*)

*Table 1* depicts the reasons given for prescribing each specific examination or a combination of multiple modalities. The main reason why practitioners chose OPG was because of the broad coverage (69.84%) and a combination of cost and availability (12.59%). None of the practitioners advised a conventional tomography or a CBCT and hence it was not included in the final data analysis (*Table 1*).

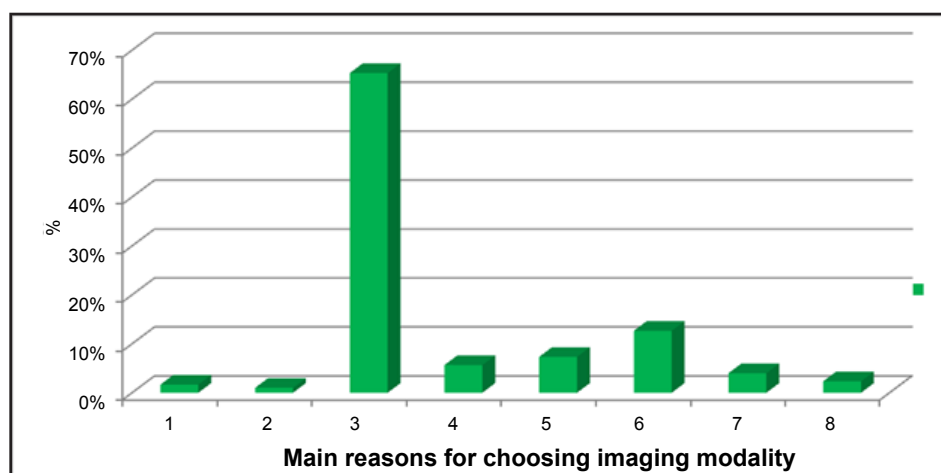
### Discussion

We decided to conduct this survey which was the first of its kind in the Indian subcontinent to survey the current radiographic prescription practices in Dental Implant



**Figure 1.** The distribution of the various imaging modalities in implant site assessment. 1. IOPAR; 2. OPG; 3. CT; 4. OPG+IOPAR; 5. OPG+CT; 6. OPG+IOPAR+CT.

**Figure 2.** Distribution of the reasons for prescribing particular imaging modalities for assessment of implants. 1. Cost; 2. Patient radiation dose; 3. Broad coverage of facial bones and teeth; 4. Availability; 5. Measurement precision; 6. Cost+availability; 7. Cost+broad coverage; 8. Cost+precision.



**Table 1.** The distribution of the different imaging modalities chosen by various dentists in implant site assessment.

The different types of radiographic examinations prescribed for dental implant assessment									
Radiographic examination employed									Total
IOPAR	1	0	0	1	0	0	0	0	2
OPG	4	3	183	11	9	33	12	7	262
CT	0	0	2	0	4	0	0	0	6
CONV.TOM	0	0	0	0	0	0	0	0	0
OPG+IOPAR	0	0	4	5	0	5	0	0	14
OPG+CT	0	0	6	0	7	0	0	0	13
OPG+IOPAR+CT	0	0	1	0	2	0	0	0	3
Total									300

assessment and whether they are aware of and follow the recommendations put forward by the American Academy of Oral and Maxillofacial Radiology (AAOMR), European Academy of Dental and Maxillofacial Radiology (EADMFR), European Association for Osseointegration (EAO) and the International congress of Oral Implantologists (ICOI) [13-16].

As per the AAOMR recommendations OPG may be used for the initial assessment and an IOPAR can be used to supplement the preliminary information from the OPG. Initial diagnostic information should not be gleaned from a Cone beam Computed Tomography (CBCT) [13]. The EADMFR guidelines put forward 20 basic principles for the use of dental CBCT where they have also mentioned that CBCT examination is justified only if it adds new information to the patient's existing condition [14]. The EAO has recommended that clinicians should decide if cross-sectional imaging is required or not based on the information from conventional radiography. They have recommended that if cross-sectional imaging is warranted, then the case must be referred to specialist dentomaxillofacial radiologist. They have recommended that fundamentally proper clinical examination must be performed with recommended standard radiographs before deciding if cross-sectional imaging is indicated [15].

The ICOI recommended that the benefits from subjecting a patient to CBCT examination must outweigh the risks and should not be taken without obtaining proper medical and dental history and performing thorough clinical examination of the sites. The radiographic modality should be tailored to individual needs and the smallest possible Field of View (FOV) must be used [16].

In this survey conducted in the state of Kerala in India, we have ascertained that the OPG, mostly solely, was the most frequent imaging modality chosen by the implant dentistry practitioners for their implant practices. Approximately a huge 97.3% of the practitioners preferred an OPG examination either as a single imaging modality or as a combination with other imaging modalities. This proved that they have all not been following the international AAOMR, EADMFR, EAO or ICOI recommendations, about which 98% of the practitioners were not even aware of our study has shown similar results as Beason and Brooks; and Sakakura et al. where 95% and 82.6% practitioners respectively chose OPGs in their implant practices over other modalities contrary to the AAOMR and EADMFR recommendations [11,13,17]. McCrea performed a study involving members of the British Society of Periodontology, which enquired about the adherence to EAO guidelines. Clinicians using other cross-sectional imaging were in minority namely, Linear tomography-8%, multi-

directional Tomography-25% and Cone Beam Computed Tomography-2.5% [6]. A recent study by Shelley et.al showed no agreement among practitioners about image prescription methods which is similar to the results obtained by us [17,18]. Similar to Sakakura et al. study, more than half of the dentists (65.33%) prescribed OPG, due to broad coverage of the facial bones and teeth (69.84%), followed by cost and availability (12.59%). Because of a substantial number of people have chosen cost over other factors, we assume that cost plays an important role in addition to the need for diagnostic information by the practitioners, which maybe because india is still an economically developing country when compared to other developed counterparts. Most of the practitioners we believe would be performing this procedure without proper cross-sectional information. They rely on their clinical judgement to assess the bone width and many a time this may result in bad prognosis for the implant because of the lack of sufficient bone in terms of quantity [19]. In our study we came to know that only 6 practitioners (0.02%) of our sample ever prescribed a cross-sectional imaging modality for their cases. In this case all the practitioners made use of Spiral CT scans and no one ever prescribed a conventional tomography or a CBCT for their patients. This is very similar to the study by Beason and Brooks where more than 90% of the dentists had never used conventional tomography and 65% had never used CT, and is also similar to the study by Sakakura et al., where only 7.2% of the dentists prescribed conventional tomography or Computed Tomography (CT) as a single examination and 10.1% prescribed CT in combination other types of radiographic examination bringing the total upto 17.3% [11,17]. McCrea also conducted a postal questionnaire similar to ours in which the practitioners were quizzed regarding their knowhow of the guidelines put forward by professional bodies, out of which 208 clinicians (80.8%) did not follow UK selection criteria for single sites and around 217 clinicians (77.5%) did not follow the criteria for multiple sites. In addition to 263 clinicians (94%) did not follow the USA selection criteria. They concluded that around 80% of the participants in the survey were not following the guidelines for pre-implant imaging. The author was of the opinion that there is a need for research and formulation of selection criteria that will be prescribed by practitioners of implantology [6]. In the recent study by Shelley et.al 169 dentists were surveyed which showed no consensus among practitioners on radiographic prescription practices. Implantologists who placed more than 100 implants per annum were not using imaging guides and often used similar views for implant site assessment. Those who had a Cone Beam Computed Tomography (CBCT)

machine often used it without actually considering whether the case was indicated for the examination or not. They concluded that there was a need for the formulation of evidence based criteria for radiographic prescription which had to be widely disseminated among practitioners by educating them [18].

OPG provides an excellent general overview of the dentition and the jaws. But, they have certain inherent limitations when used for pre and post implant assessment like distortions in the horizontal plane, magnification in the vertical plane and the image is only a two dimensional representation of a three dimensional entity. Important anatomical structures like the Inferior alveolar canal are also not well demonstrated on the OPG. Another drawback is that images closer to the lingual cortex may many a time be superimposed at a higher level in the radiograph not to mention the numerous airway shadows, Ghost images and soft tissue shadows which can adversely affect treatment planning [20-22].

We feel the main reasons for not prescribing a cross-sectional imaging modality by most of the practitioners is because of the lack of awareness of the recommendations of the AAOMR, EADMFR, EAO or ICOI and also due to the lack of availability of conventional tomography or CBCT in the state of kerala. During the drafting of this article it has come to the knowledge of the authors that the first CBCT centre is being set up in kerala state by a private practitioner and there is no such apparatus available for mass use in the government sector. The non-availability of the imaging modality, coupled with the dentist's familiarity with assessment of an OPG image and lack of knowledge about cross-sectional imaging may all be factors contributing to the poor prescription of cross sectional imaging for dental implant site assessment. Around 18.99% of the practitioners have mentioned cost with other factors like availability, broad coverage and measurement precision as concerns which affected their judgement. In a developing third world country like India it is only a small percentage of the population who can go for a costly treatment option like an implant. The costs involved in cross-sectional imaging may add to this burden causing practitioner's to forego cross-sectional imaging techniques and rely more on their clinical acumen and expertise in implant placement. Similar to Sakakura et al's study, 3 dentist's (1%) considered radiation dose to influence their prescription [17]. Similar to dental schools internationally, Indian dental schools also stress a lot on dose reduction by following the ALARA (As Low as Reasonably Achievable) principle. But, definitely the lowest dose possible should not be achieved at the cost of poor diagnostic information. This would also lead to practitioners

requesting a repeat radiographic examination increasing the cumulative irradiation to the patient.

The AAOMR recommends that although initial imaging assessment maybe achieved with OPG supplemented with IOPAR, for preoperative diagnostic assessment a cross-sectional imaging be used for implant site assessment [13]. They also recommend CBCT as the imaging modality of choice because very minimal radiation dose can provide the greatest diagnostic yield which should be the hallmark of any radiographic imaging modality. However, for periodic post operative implant monitoring, IOPAR and OPG cases would be able to provide adequate diagnostic information. In India similar to other countries the interpretation of CBCT images is done by specialist oral and maxillofacial radiologist who also specialises in oral medicine. These specialists are few in number and the general dentist is not trained to interpret cross-sectional images which maybe a cause for the reduced number of referrals. Small changes in the dental education curriculum can change all that. This is already being implemented in the curriculum prescribed by the Dental Council of India where maxillofacial radiology is being taught at the undergraduate level itself. The use of CBCT in implant imaging seems to be very promising however there is a need for more research on the efficacy of CBCT in assessment of the implant site. Currently there has not been any large scale standardised trials involving CBCT use and implant success or failure anywhere in literature and would be a good avenue to direct further research. To conclude, this survey has shown similar results as that of Beason and Brooks Sakakura et.al, McCrea and Shelley et.al where the majority of the dentists in kerala state in india prescribe OPG as both an initial and final diagnostic modality for dental implant assessment based on broad coverage, cost and availability and are not following the recommendations and guidelines put forward by professional bodies engaged in the practice of Implantology [6,11,17,18]. Approximately 98% of the practitioners were not even aware of recommendations existing for proper implant radiology practice. We feel there is a need to develop a broad evidence based criteria for radiographic prescription in implant site assessment and this has to be introduced in the current dental school curriculum throughout the world. For this to be possible, data from different regions of the world regarding radiographic prescription practices must be collated and all the professional bodies located around the world; not just the US and UK have to collaborate to put forward a consensus paper establishing guidelines for radiographic implant site assessment.

## References

1. Schnitman PA, Schulman LB. Recommendations of the consensus development conference on dental implants. *Journal of American Dental Association*. 1979; **98**: 373-377.
2. Albrektsson T, Zarb G, Worthington P, Eriksson AR. The long-term efficacy of currently used dental implants: A review and proposed criteria of success. *International Journal of Oral Maxillofacial Implants*. 1986; **1**: 11-25.
3. Smith D, Zarb G. Criteria for success of osseointegrated endosseous implants. *Journal of Prosthetic Dentistry*. 1989; **62**: 567-572.
4. Scaf G, Lurie AG, Mosier KM, Kantor ML, Ramsby GR, Freedman ML. Dosimetry and cost of imaging osseointegrated implants with film-based and computed tomography. *Oral Surgery, Oral Medicine, Oral Pathology, Oral Radiology, and Endodontics*. 1997; **83**: 41-48.
5. Lindh C, Petersson A. Radiologic examination for location of the mandibular canal: A comparison between panoramic radiography and conventional tomography. *International Journal of Oral and Maxillofacial Implants*. 1989; **4**: 249-253.
6. McCrea SJ. Pre-operative radiographs for dental implants - are selection criteria being followed? *British Dental Journal*. 2008; **204**: 675-682.



7. Pharoah MJ. Imaging techniques and their clinical significance. *International Journal of Prosthodontics*. 1993; **6**: 176-179.
8. Theory of Rotational Panoramic Radiography. In: Welander U, Tronje G, Mc David WD, Langland OE, Langlais RP (Editors) *Panoramic radiology* (2<sup>nd</sup> edn.) Philadelphia: Lea and Febiger, 1989; pp. 38-75.
9. Tal H, Moses OA comparison of panoramic radiography with computed tomography in the planning of implant surgery. *Dentomaxillofacial Radiology*. 1991; **20**: 40-42.
10. Fredholm U, Bolin A, Andersson L. Preimplant radiographic assessment of available maxillary bone support: comparison of tomographic and panoramic technique. *Swedish Dental Journal*. 1993; **17**: 103-109.
11. Beason RC, Brooks SL. Preoperative implant site assessment in southeast Michigan. *Journal of Dental Research*. 2001; **80**: 137.
12. Tyndall DA, Brooks SL. Selection criteria for dental implant site imaging: a position paper of the American Academy of Oral and Maxillofacial Radiology. *Oral Surgery, Oral Medicine, Oral Pathology, Oral Radiology, and Endodontics*. 2000; **89**: 630-637.
13. Tyndall DA, Price JB, Tetradis S, Ganz SD, Hildebolt C, Scarfe WC. Position statement of the American Academy of Oral and Maxillofacial Radiology on selection criteria for the use of radiology in dental implantology with emphasis on cone beam computed tomography. *Oral Surgery, Oral Medicine, Oral Pathology, Oral Radiology*. 2012; **113**: 817-826.
14. Horner K, Islam M, Flygare L, Tsiklakis K, Whaites E. Basic principles for use of dental cone beam computed tomography. A consensus workshop organized by the European Academy of Dental and Maxillofacial Radiology. *Dentomaxillofacial Radiology*. 2009; **38**: 187-195.
15. Harris D, Buser D, Dula K, Grondahl K, Jacobs R, Lekholm U, Nakielny R, Van Teenberghe D, Van der Stelt P. European Association for Osseointegration (E.A.O.) guidelines for the use of diagnostic imaging in implant dentistry. A consensus workshop organized by the European Association for Osseointegration in Trinity College Dublin. *Clinical Oral Implants Research*. 2002; **13**: 566-570.
16. Benavides E, Rios HF, Ganz SD, An CH, Resnik R, Reardon GT, Feldman SJ, Mah JK, Hatcher D, Kim MJ, Sohn DS, Palti A, Perel ML, Judy KW, Misch CE, Wang HL. Use of cone beam computed tomography in implant dentistry: The International Congress of Oral Implantologists consensus report. *Implant Dentistry*. 2012; **21**: 78-86.
17. Sakakura CE, Morais JA, Loffredo LC, Scaf G. A survey of radiographic prescription in dental implant assessment. *Dentomaxillofacial Radiology*. 2003; **32**: 397-400.
18. Shelley AM, Wardle L, Goodwin M, Brunton P, Horner K. A questionnaire study to investigate custom and practice of imaging methods for the anterior region of the mandible prior to dental implant placement. *Dentomaxillofacial Radiology*. 2013; **42**: 2-11.
19. Schropp L, Wenzel A, Kostopoulos L. Impact of conventional tomography on prediction of the appropriate implant size. *Oral Surgery Oral Medicine Oral Pathology Oral Radiology Endodontics*. 2001; **92**: 458-463.
20. Endosteal Dental Implants. In: Babbush CA, McKinney RV (Editors) *Evaluation and selection of the endosteal implant patient*. St Louis: Mosby Year Book, 1991; pp. 63-74.
21. Ten Bruggenkate CM, Van der Linden LW, Oosterbeek HS. Parallelism of implants visualized on the orthopantomogram. *International Journal of Oral Maxillofacial Surgery*. 1989; **18**: 213-215.
22. Theory of rotational panoramic radiography. In: Welander U, Tronje G, McDavid WD, DelBalso AM, Langlais RP, Langland OE (Editors) *Panoramic Radiology* (2<sup>nd</sup> edn) Philadelphia: Lea & Febiger. 1989; pp. 38-40.