

A Rare Case of Extra-Pulmonary Manifestation of *Mycoplasma pneumoniae*

Carl Tabb II^{1*}, Vignesh Gunasekaran¹, Lara Kothari¹ and Deepak Kamat²

¹Children's Hospital of Michigan Detroit, Michigan, USA; ²University of Texas Health Science Center San Antonio, TX, USA

ABSTRACT

Background and aim: *Mycoplasma pneumoniae* is one of the many organisms causing pneumonia in children. It commonly presents with pulmonary manifestations however uncommonly infection with *M. pneumoniae* causes extra-pulmonary manifestations. Involvement of liver is one of such rare extra-pulmonary manifestations of *M. pneumoniae*. Direct and indirect hits along with vascular occlusion leading to liver injury have been postulated to be the cause of liver involvement.

Case presentation: A 10-year-old African American boy with mild obstructive sleep apnea, chronic migraine, gastroesophageal reflux presented with 5-day history of rash, fever, emesis, dark urine, diarrhea, thrush, decreased oral intake and abdominal pain. The rash didn't improve with diphenhydramine at home. Patient was initially tachycardic, tachypneic, and febrile to 39.6°C. Initial physical examination revealed, scleral icterus, maculopapular erythematous diffuse rash all over the body, bilateral conjunctivitis, with right upper quadrant tenderness but no organomegaly. Initial laboratory results showed moderate transaminitis, along with elevated bilirubin, however initial imaging study was found to be normal. The patient over the course of his admission continued to spike high fevers and WBC counts continued to rise.

Conclusion: *Mycoplasma pneumoniae* is often thought to cause pulmonary disease and very few cases have been presented with extra-pulmonary manifestations. Early diagnosis and initiation appropriate therapy improves outcome and decreases the incidence of extra-pulmonary manifestations.

Keywords: Extra-pulmonary mycoplasma; *Mycoplasma pneumoniae*; Atypical pneumonia

INTRODUCTION

Case

A 10-year-old African American boy with mild obstructive sleep apnea, chronic migraine, gastroesophageal reflux presented with a 5-day history of rash, fever, emesis, dark urine, diarrhea, thrush, decreased oral intake and abdominal pain. The patient at that time did not have HIV testing done and was not using any inhaled corticosteroids. Per the patient's parents, his immunizations were up to date and the rash did not improve with at home administration of diphenhydramine.

The patient's vital signs in the emergency department were as follows: temperature of 39.6°C, heart rate 109 beats per min, blood pressure 128/71 mmHg, respiratory rate 34 breaths per minute, height, weight, and BMI were all found to be within the 5th-75th percentile and considered appropriate for age. Physical examination revealed, scleral icterus, maculopapular erythematous diffuse rash all over the body, bilateral conjunctivitis, with right upper quadrant tenderness but no organomegaly was present.

His laboratory evaluation revealed ALT 335 units/L (7-52 units/L normal range), AST 175 units/L (13-59 units/L normal range), alkaline phosphatase 482 units/L (134-518 units/L normal range), total bilirubin 3.7 mg/dL (normal range <1.50 mg/dL), and direct bilirubin 1.2 mg/dL (normal range 0.03-0.18 mg/dL). His WBC count was slightly elevated at 11.7 K/Cumm (normal range 5-20 K/Cumm) and his hemoglobin was normal at 11.1 g/dL (normal range 10.4-14.5 g/dL). As well, abdominal ultrasound was normal. The patient's acute hepatitis panel including: A, B, and C IgG and IgM antibodies were negative as were the pharyngeal streptococcal antigen test. Due to these findings, the patient was admitted for further evaluation.

Over the course of his 10-day admission, he continued to spike fevers and his WBC count continued to trend upwards. Pediatric infectious diseases and rheumatology services were consulted and additional laboratory evaluation was performed. C3/C4, EBV IgM panel, ANA/anti dsDNA, haptoglobin, anti SMA, ceruloplasmin, stool toxin/cultures were all negative. Per rheumatology recommendation, these tests were ordered to rule

Correspondence to: Carl Tabb II, Children's Hospital of Michigan Detroit, Michigan, USA, Tel: 313-966-0254; E-mail: ctabb02@gmail.com

Received: February 01, 2019, **Accepted:** April 05, 2019, **Published:** April 12, 2019

Citation: Tabb II C, Gunasekaran V, Kothari L, Kamat D (2019) A Rare Case of Extra-Pulmonary Manifestation of *Mycoplasma pneumoniae*. Clin Pediatr OA 4:153.

Copyright: © 2019 Tabb II C, et al. This is an open-access article distributed under the terms of the Creative Commons Attribution License, which permits unrestricted use, distribution, and reproduction in any medium, provided the original author and source are credited

out any potential cause of autoimmune etiology for the patient's symptoms and to rule out other less common infectious causes. At that time, his chest X-ray showed right lower lobe pneumonia and *Mycoplasma* IgM to be found positive. The patient was started on a 10-day course of doxycycline. Following initiation of treatment, the patient's symptoms began to rapidly improve, his WBC along with liver enzymes count began to trend downward and the patient's rash began to subside. At that time, the patient was deemed to be clinically stable and discharged home in the care of his parents. The patient had a follow-up planned with both infectious diseases and rheumatology services.

DISCUSSION

Mycoplasma pneumoniae is a major cause of respiratory infection in school-age children and young adults. *Mycoplasma pneumoniae* is also a known cause of atypical pneumonia with different clinical presentation than standard pneumonia. Atypical pneumonia is thought to cause approximately 17% of hospital acquired pneumonia, with prevalence ranging between 3% and approximately 43%. There also appears to be no difference in gender predisposition to the disease process; [1,2] which was often thought to cause atypical community acquired pneumonia with protracted and insidious onset in children and adolescents. Other causes of atypical community acquired pneumonia are *Chlamydia* and *Legionella* [3]. It is important to note that while labeled as atypical- infections caused by the previously mentioned bacteria are quite common. Often bilateral findings of opacities on chest radiographs are one of the differentiating factors in classifying the disease process (Figure 1). Usually pulmonary findings are the common presenting symptom however, extrapulmonary findings are also common. Extrapulmonary manifestations of *Mycoplasma pneumoniae* usually involve skin, cardiovascular, neurologic and hematologic systems. [4] This can be explained by one of three mechanisms:

1. **Direct hit:** Bacteria are present at the site of inflammation and the cytokines induced by the lipoproteins in the bacterial cell membrane cause the tissue injury [5].
2. **Indirect hit:** The tissue damage is due to immune response wherein the host antibodies attack the host cells [4,5].
3. **Vascular occlusion:** The inflammatory response leads to obstruction of the blood flow.

Early onset hepatitis can be explained by direct hit mechanism, whereas late onset hepatitis is more likely to be due to an indirect hit. In our patient, with his early onset liver enzyme abnormalities and resolution of symptoms after starting doxycycline (without steroids) it appears more like a direct hit causing the extra pulmonary manifestation.

Review of the literature shows very few cases of liver involvement secondary to *Mycoplasma*. One case of hepatitis without pneumonia was reported from Korea [6,7]. In addition, *Mycoplasma* associated encephalitis has been reported in two children after viral upper respiratory infection. With increased advancements and laboratory access, pediatricians should have a high degree of suspicion for extra pulmonary manifestations of *Mycoplasma* and early initiation of appropriate antibiotics is indicated.

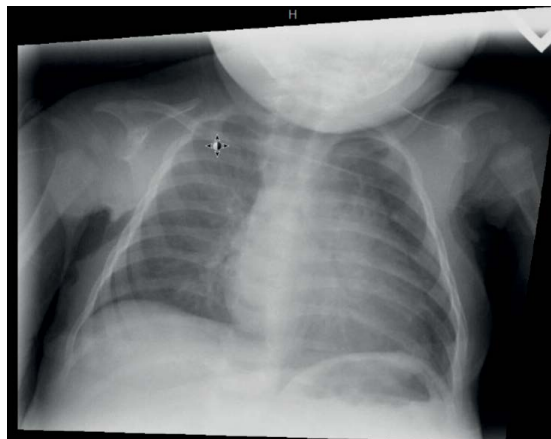


Figure 1: Showing per staff radiologists bilateral hazy airspace opacities greatest in the right upper lung and left perihilar region that may represent an atypical pneumonia or atelectasis.

REFERENCES

1. Schneeberger PM, Dorigo-Zetsma JW, Van Der Zee A, Van Bon M, Van Opstal JL. Diagnosis of atypical pathogens in patients hospitalized with community-acquired respiratory infection. *Scand J Infect Dis.* 2004;36:269-273.
2. File TM Jr, Tan JS. Chlamydia pneumoniae pneumonia. *Semin Respir Crit Care Med.* 2000;21:285-294.
3. McCormack WM, Kasper DL, Braunwald E, Fauci AS. Infections due to Mycoplasmas. *Harrison's Principles of Internal Medicine.* New York: McGraw-Hill; 16th (eds.) 2005;1008-1011.
4. Garnier JM, Noel G, Retornaz K, Blanc P, Minodier P. Extrapulmonary infections due to *Mycoplasma pneumoniae*. *Arch Pediatr.* 2005;12:2-6.
5. Grulich C, Baumert TF, Blum H. Acute *Mycoplasma pneumoniae* infection presenting as cholestatic hepatitis. *J Clin Microbiol.* 2003;41:514-515.
6. Lee SW, Yang SS, Chang CS, Yeh HJ, Chow WK. *Mycoplasma pneumoniae*-associated acute hepatitis in an adult patient without lung infection. *J Chin Med Assoc.* 2009;72:204-6.
7. Park IH, Choi du Y, Oh YK, Kim JD, Yu ST. A case of acute myopericarditis associated with *Mycoplasma pneumoniae* infection in a child. *Korean Circ J.* 2012;42:709-713.