



A Case Report: A Cementless Total Hip Arthroplasty in A Patient with Alkaptonuria

Augusto Dagnino, Nicola Ursino¹ and Alfonso Maria De Simone²

¹IRCCS Istituto Ortopedico Galeazzi MI, Italy

²Seconda Università degli Studi di Napoli, Italy

Abstract

Ochronosis is connective tissue manifestation of Alkaptonuria. Joint involvement especially hip and knee destruction is seen. The cartilage is pigmented and destroyed. A 55years old male (Figure 1) with a previous total arthroplasty on both shoulders, has recently develop a hip pain. He was affected of alkaptonuria (AKU). We proceed with a total hip arthroplasty with cement less cup and modular cement less stem. Functional and quality of life scores of pre operative and post operative were compared with good results. The HHS had raised from 38,725 to 89,725, the SF36 raised too. There are no data of evaluation of QoL in literature in patients with AKU.

Keywords: Total hip arthroplasty; Ochronosis; Alkaptonuria; Quality of life; HHS; SF36

Introduction

Alkaptonuria (AKU) is an autosomal recessive disorder, caused by deficiency of the homogentisate 1,2 dioxygenase (HGO), an enzyme which normally catalyses the conversion of homogentisic acid (HGA) into maleylacetoacetic acid, in the tyrosine degradation pathway. AKU is characterized by a plasmatic accumulation and subsequently an increased urinary excretion of HGA. In absence of HGO, HGA is rapidly oxidized to benzoquinone acetic acid (BQA). BQA polymerizes to amelanin-like pigment, which accumulates in connective tissues (ochronosis). This condition leads to a severe and crippling arthropathy [1,2,3].

Materials and Methods

The fragility of the cartilage of AKU patients leads to fragmentation of its upper layer, causing the detachment of small fragments (shards) with consequent exposure of the subchondral bone. For this reason patients suffer joints pain and quickly involved in a multiple joints replacement [1]. Our patient already was treated with multiple joint replacements, both shoulders were treated with an inverse arthroplasty, and now is presenting hip pain as frequently viewed in AKU patients [4]. In literature [5] there are many articles with different treatments of ochronosis with cement or cementless devices [6,7]. In AKU the lesions are limited to the cartilage and nothing append to the cancellous bone. Considering the age of the patient (55 years old) cement less modular stem and cement less cup for us is the best choice.

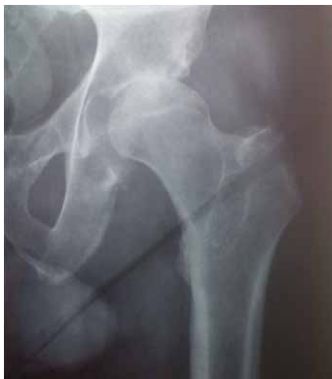

Figure 1: 1Preoperativeimage

We proceed to the surgery using a mini-invasive postero-lateral approach. After capsulotomy we discovered the classical black-pigmented femoral head (figure 2). The pigmentation of soft tissue such as the capsule is similar to a metallosis disease [6]. We proceed with osteotomy of the neck and the cancellous bone seemed good. After acetabulum reaming we removed cartilage until we reached good cancellous bone that shows an aspect similar to a normal bone, with white-colored structure of the cancellous bone and cortical of the lamina quadrilateral. A Zimmer Trilogy Modular Cup of 52 mm diameter and a 32 mm liner with HWMPE was placed without problems and with a good primary fixation. We prepared than the femur and we checked with our plan the correct match of the distance. We placed a ZIMMER CLS Brevius Kinectiv stem with a neck R and a 32 mm delta ceramic head standard length. We checked the leg length and the stability with good results (figure 3).

After the surgery we start the rehabilitation. As usual patient rise on the second day after surgery with canes and stair, climbing in the 4th day.

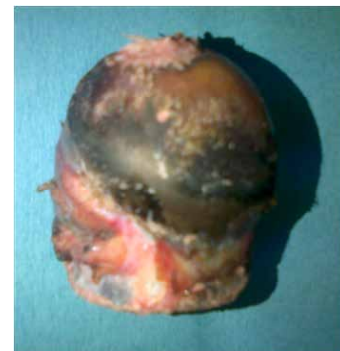

Figure 2: Blackpigmentedfemoral head

***Corresponding author:** Dr. Augusto Dagnino, IRCCS Istituto Ortopedico Galeazzi (MI) Italy, Tel: +393474550552; E-mail: dr.dagnino@gmail.com

Received July 01, 2013; **Accepted** July 27, 2013; **Published** August 02, 2013

Citation: Dagnino A, Ursino N, De Simone AM (2013) A Case Report: A Cementless Total Hip Arthroplasty in A Patient with Alkaptonuria. Orthop Muscul Syst 2: 126. doi:10.4172/2161-0533.1000126

Copyright: © 2013 Dagnino A, et al. This is an open-access article distributed under the terms of the Creative Commons Attribution License, which permits unrestricted use, distribution, and reproduction in any medium, provided the original author and source are credited.

Results

The evaluation of results are made considering a functional score (the Harris Hip Score) and a quality of life score (SF 36).

The preoperative and 6 months post operative results for HHS are shown in Chart 1.

We like to evaluate the perception of quality of life (QoL) too, and we submit the SF-36. We use the Italian version with the comparison with the mean Italian value made by Dr. Mosconi at Mario Negri Institute (<http://crc.marionegri.it/qdv/questionari/sf36/sf36v1ita.htm>). The result can be viewed in Chart 2.

Conclusions

The patient was treated with a total hip arthroplasty with successful results.

We have evaluated after 6 months of the surgery with functional and quality of life scores. We obtained the some results with no AKU patients. The AKU damage is limited and the bone is still good so cementless implants are good. Analyzing the sf36 scores we have the

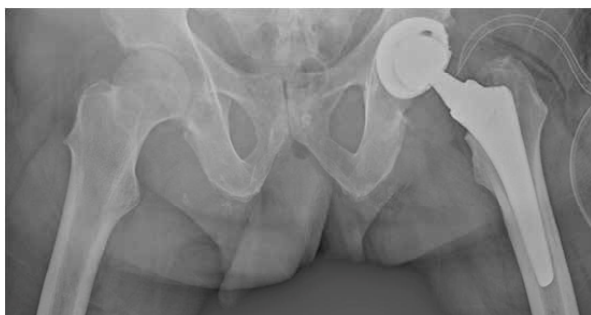

Figure 3: Postoperative check

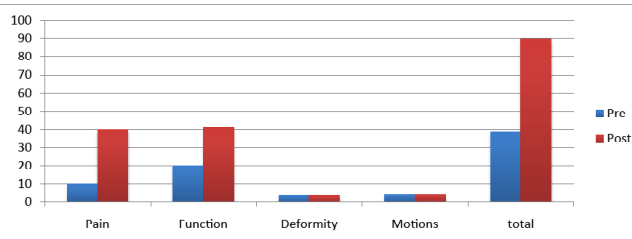


Chart 1 : HHS Pre post operative

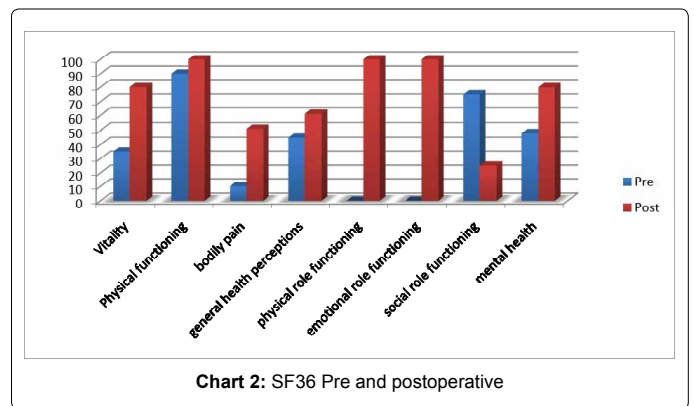


Chart 2: SF36 Pre and postoperative

only 2 results that after the surgery are still low: bodily pain and social role functioning [8,9]. This is because the AKU is probably damaging other articulations and so even if the functional score analyze the joint replaced with good results, the perception of the quality of live tells us that the patient is still suffering same discomfort.

We think that the QoL scores are more important that the functional scores, because patients need a full restoration of quality of life and not just a successfully surgical performance.

References

1. Taylor AM, Boyde A, Wilson PJ, Jarvis JC, Davidson JS, et al. (2011) The role of calcified cartilage and subchondral bone in the initiation and progression of ochronotic arthropathy in alkaptonuria. *Arthritis Rheum* 63: 3887-3896.
2. Borman P, Bodur H, Ciliz D (2002) Ochrotonic arthropathy. *Rheumatol Int* 21: 205-209.
3. Corrà T, Zaccala M, Galante M (1995) Ochrotonic arthropathy: rapid destructive hip osteoarthritis associated with metabolic disease. *Clin Rheumatol* 14: 474-477.
4. Demir S (2003) Alkaptonuric ochronosis: a case with multiple joint replacement arthroplasties. *Clin Rheumatol* 22: 437-439.
5. Cetinus E, Cever I, Kural C, Erturk H, Akyildiz M (2005) Ochrotonic arthritis: case reports and review of the literature. *Rheumatol Int* 25: 465-468.
6. Siavashi B, Zehtab MJ, Pendar E (2009) Ochrotonosis of hip joint; a case report. *Cases J* 2: 9337.
7. Shimizu I, Hamada T, Khalpey Z, Miyaniishi K, Hara T (2007) Ochrotonic arthropathy: pathological evidence of acute destruction of the hip joint. *Clin Rheumatol* 26: 1189-1191.
8. Dom K, Pittevels T (1997) Ochrotonic arthropathy: the black hip. Case report and review of the literature. *Acta Orthop Belg* 63: 122-125.
9. AydoÄYdu S, Cullu E, Ozsoy MH, Sur H (2000) Cementless total knee arthroplasty in ochrotonic arthropathy: a case report with a 4-year follow-up. *J Arthroplasty* 15: 539-543.