

A Case of Successful Extracorporeal Membrane Oxygenation Support for Cardiac Arrest Associated with Nonocclusive Mesenteric Ischemia

Koichiro Ogura^{1*}, Takehiko Oami¹, Noriyuki Hattori¹, Eizo Watanabe¹, Ryuzo Abe¹, Tomoaki Hashida¹, Takayuki Toma² and Shigeto Oda¹

¹Department of Emergency and Critical Care Medicine, Chiba University Graduate School of Medicine, Japan

²Department of Frontier Surgery, Chiba University Graduate School of Medicine, Japan

*Corresponding author: Koichiro Ogura, Department of Emergency and Critical Care Medicine, Chiba University Graduate School of Medicine, 1-8-1 Inohana, Chuo, Chiba, Chiba, Japan, Tel: +81-43-226-2341; E-mail: koogura55@gmail.com

Received date: April 28, 2016; Accepted date: May 01, 2016; Published date: May 09, 2016

Copyright: © 2016 Ogura K, et al. This is an open-access article distributed under the terms of the Creative Commons Attribution License, which permits unrestricted use, distribution, and reproduction in any medium, provided the original author and source are credited.

Abstract

Background: We report a case of successful extracorporeal membrane oxygenation (ECMO) support for cardiac arrest associated with nonocclusive mesenteric ischemia (NOMI).

Case presentation: A 34-year-old previously healthy woman in the sixth week of her second pregnancy was carried to our hospital for abdominal pain and vomiting. She had apparent peritoneal irritation signs with marked hyperglycemia and metabolic acidosis and developed refractory shock. Since portal venous gas and intestinal dilatation without enhancement in contrast-enhanced computed tomography (CT) were observed, a subtotal resection of the small intestine and right hemicolectomy against widespread intestinal necrosis were performed as an emergency operation. The patient returned to the intensive care unit (ICU) with open abdominal management. Severe respiratory failure gradually developed during the operation, and veno-venous (V-V) ECMO was prepared to start in the ICU after the operation. However, cardiac arrest occurred abruptly during the cannulation for ECMO. Therefore, veno-arterial (V-A) ECMO was implemented and hemodynamic status gradually improved. V-A ECMO was switched to V-V ECMO on Day 4 because of persistent respiratory failure. Colostomy was performed on Day 5, abdominal wall was closed on Day 8, and ECMO was successfully weaned off on Day 9. Furthermore, several surgical interventions including gauze packing for retroperitoneal bleeding and operation for intestinal dehiscence, and right lower extremity amputation were needed. She was free from the ICU on Day 78. Finally, closure of the colostomy and anastomosis of the residual duodenum and colon were performed, and the patient was discharged from the hospital without any neurologic impairment on Day 262.

Conclusion: Successful surgical interventions and appropriate ECMO support contributed to the patient's survival.

Keywords: Nonocclusive mesenteric ischemia; Extracorporeal membrane oxygenation; Cardiac arrest; Pregnancy; Damage control surgery; Diabetic ketoacidosis

Abbreviations

APACHE II Score: Acute Physiology and Chronic Health Evaluation II Score; APRV: Airway Pressure Release Ventilation; CHDF: Continuous Hemodiafiltration; CT: Computed Tomography; DCS: Damage Control Surgery; DKA: Diabetic Ketoacidosis; ECMO: Extracorporeal Membrane Oxygenation; ICU: Intensive Care Unit; NOMI: Nonocclusive Mesenteric Ischemia; PMMA: Polymethyl Methacrylate; SOFA Score: Sequential Organ Failure Assessment Score; V-A: Venous-Arterial; V-V: Venous-Venous

Introduction

Nonocclusive mesenteric ischemia (NOMI) is a condition characterized by intestinal ischemia without any obstruction of the mesenteric artery or vein. NOMI requires extensive intestinal resection, and the outcome is very poor due to complicating organ failure [1]. We report herein a successful case of ECMO support for

postoperative cardiac arrest associated with NOMI that occurred during pregnancy.

Case Presentation

Case: 34-year-old woman

Past history: The patient had no particular past history except for glycosuria identified during her first pregnancy without any follow-up.

Present history: She was in her second pregnancy with 6 weeks of gestation. She carried to our hospital with abdominal pain and vomiting that persisted for 2 days. She did not exhibit any obstetric abnormalities. Soon after admission, she fell into shock and unconsciousness.

Present symptoms: Glasgow Coma Scale, E4V4M6; blood pressure, 84/43 mmHg; heart rate, 130/min; respiratory rate, 37/min; body temperature, 36.1°C; marked peripheral coldness, abdominal distention and tenderness with muscular defense; Acute physiology and chronic health evaluation II score (APACHE II score), 45; Sequential organ failure assessment score (SOFA score), 15.

Laboratory findings upon hospitalization (Table 1): Blood biochemistry results revealed hyperlactatemia. Marked metabolic

acidosis and electrolyte abnormality with excessively high levels of interleukin-6, procalcitonin and endotoxin. As a result, abnormally high blood glucose and a marked increase in total ketone bodies led to a diagnosis of diabetic ketoacidosis (DKA).

Blood Cell Content			Biochemistry			Electrolytes		
WBC	4500	(/mm ³)	AST	13	(IU/L)	Na	106	(mEq/L)
RBC	3.94×10 ⁴	(/mm ³)	ALT	13	(IU/L)	K	4.3	(mEq/L)
Hb	12.0	(g/dL)	LDH	132	(IU/L)	Cl	85	(mEq/L)
Ht	32.0	(%)	ALP	218	(U/L)	Ca	7.7	(mEq/L)
Plt	15.1×10 ⁴	(/mm ³)	TP	4.3	(g/dL)			
			Alb	2.3	(g/dL)			
			UN	41	(mg/dL)	Coagulation system		
Blood gas analysis			Cre	2.16	(mg/dL)	PT activity	11.2	(sec)
pH	7.18		T-Bil	0.4	(mg/dL)	APTT	47.1	(sec)
PaO ₂	194	(mmHg)	CK	364	(U/L)	FDP	5.5	(µg/mL)
PaCO ₂	22	(mmHg)	CK-MB	20.1	(U/L)			
HCO ₃ ⁻	8.2	(mmol/mL)	CRP	6.8	(mg/dL)			
BE	-20.2	(mmol/mL)	Glucose	1346	(mg/dL)	Others		
Lactate	3.6	(mmol/L)	HbA1C	6.5	(%)	IL-6	61573	(pg/mL)
	(O ₂ 8L/min)		Total ketone body	5390	(µmol/mL)	PCT	320.2	(ng/mL)
IL-6= interleukin-6, PCT= procalcitonin						Endotoxin	17.73	(pg/mL)

Table 1: Laboratory findings upon hospitalization.

Clinical course after intensive care unit (ICU) admission: Since contrast-enhanced computed tomography (CT) scanning identified an extensive filling defect area in the intestinal tract wall with a large volume of portal venous gas (Figure 1), an emergency laparotomy was performed. Ischemia and necrosis were observed in most parts of the small intestine and ascending colon. Minimum essential surgery (subtotal resection of small intestine and right hemicolectomy) was performed due to unstable circulatory/respiratory dynamics, and the patient returned to the ICU with open abdominal management. The duration of surgery was one hour and 36 minutes.

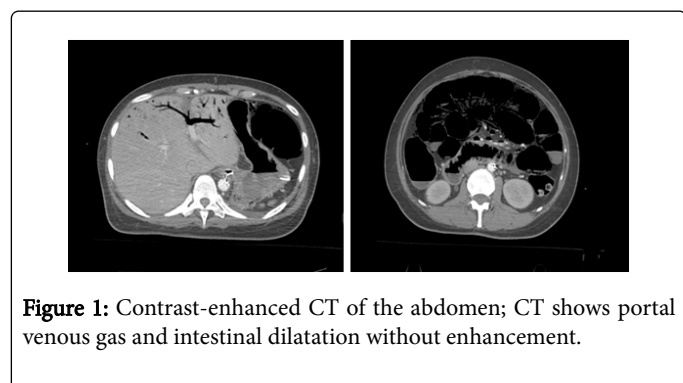


Figure 1: Contrast-enhanced CT of the abdomen; CT shows portal venous gas and intestinal dilatation without enhancement.

Since subsequent pathological examination demonstrated no apparent occlusive lesions in the mesenteric artery or vein, a diagnosis of NOMI was established. Close examinations for autoimmune

diseases, vasculitis, and thrombotic diathesis were all negative in relevant blood tests.

Postoperative course (Figure 2): Chest-X-ray upon return to the ICU demonstrated a marked decrease in radiolucency. P/F ratio was 35 mmHg despite the high positive pressure ventilation at FiO₂ of 1.0 in the airway pressure release ventilation (APRV) mode. Therefore, we decided to implement V-V ECMO.

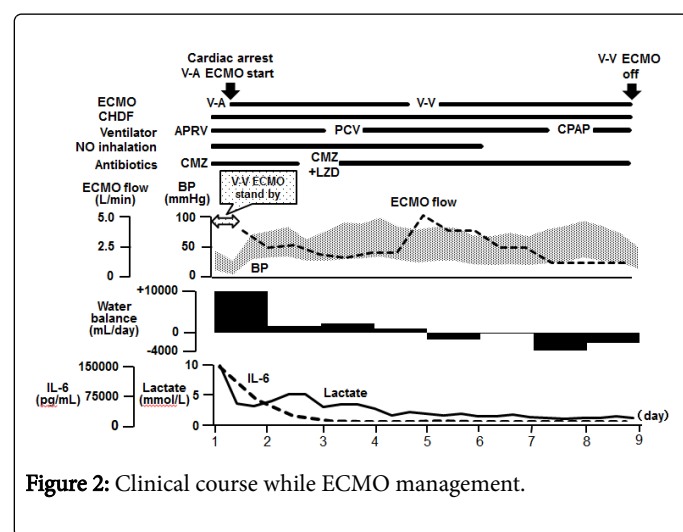


Figure 2: Clinical course while ECMO management.

However, exacerbation of hemodynamics induced by progressive respiratory failure and postoperative stress led to cardiac arrest during cannulation. V-A ECMO was hastily introduced in place of V-V ECMO. A 25-Fr Biomedicus cannula™ (Medtronic, Minneapolis, United States of America) was placed in the right internal jugular vein as a venous (drainage) cannula; while a 17-Fr Biomedicus cannula™ (Medtronic, Minneapolis, United States of America) was placed in the right femoral artery as an arterial (return) cannula. A BIOCUBE6000™ membrane oxygenator (Nipro, Osaka, Japan) and a Rota flow™ centrifugal pump (Maquet, Rastatt, Germany) were used. Since drainage failure was happened frequently, careful infusion of crystalloid or blood transfusion with monitoring hemodynamic parameters was performed to ensure the required blood flow. In addition, continuous hemodiafiltration (CHDF) using polymethyl methacrylate (PMMA) membrane hemofilter for renal replacement therapy and cytokine modulation was performed concomitantly, and administration of hydrocortisone for relative adrenal insufficiency and appropriate antibiotics were also initiated. By day 4, these treatments enabled to wean off V-A ECMO although respiratory failure has not recovered yet. Furthermore, compartment syndrome of right lower limb developed and surgical fasciotomy was required despite supplemental blood flow with the bypass circuit to prevent ischemia. Accordingly, V-A ECMO was switched to V-V ECMO on day 4. On day 5, colostomy was performed, with concomitant resection of the necrotized uterus with embryo and left ovary. Abdominal wall was closed at this time. With subsequent improvement of oxygenation, V-V ECMO was terminated on day 9. On day 14, irrigation drainage and colostomy were performed to cope with anastomotic leak. Gauze packing was placed for retroperitoneal bleeding on day 24. Furthermore, since extensive necrosis and infection were observed in the right lower extremity, above knee amputation was performed on day 26. Her general condition has been gradually stabilized thereafter, and mechanical ventilation was terminated on day 35. She was discharged from the ICU on day 78.

Finally, we performed closure of the colostomy and anastomosis of the residual duodenum and colon on Day 152. She was discharged to her home without any neurologic impairments on Day 262. She is currently on outpatient care with continued home parenteral nutrition due to short bowel syndrome.

Discussion

This is a case of successful resection of necrotized intestine and intensive care (including ECMO) in NOMI with multiple organ failure. NOMI is known as a lethal condition triggered by shock or heart failure in high-risk patients with heart disease, on chronic maintenance dialysis, or at an advanced age [1,2]. In the present case, the patient had no such risk factors, but developed NOMI in her early pregnancy through a rapid clinical course. Although the mechanism of developing NOMI in this patient could not be clarified by pathological findings, glycosuria identified during her first pregnancy and development of DKA on ICU admission suggest possible exacerbation of glucose tolerance and electrolyte abnormality with hyperemesis

gravidarum-induced severe dehydration led to NOMI. To date, several cases of DKA complicating with NOMI have been reported in Japan. Our literature search was unable to identify any reports describing an association between pregnancy and development of NOMI.

Most cases of NOMI bring about intestinal necrosis and therefore require extensive intestinal resection for treatment. In such cases, the outcome is extremely poor, as indicated by mortality rates of approximately 50-80% [1,3], which reaches 75% in the presence of portal venous gas [4]. In the present case, extensive intestinal necrosis and portal venous gas were noted with preoperative complications such as hyperlactatemia and severe metabolic acidosis. The patient fell into cardiac arrest due to severe respiratory/circulatory failure after surgery and was expected poor prognosis based on an APACHE II score of 45 (corresponding to an estimated mortality rate of 97.8%).

In the treatment of trauma or abdominal emergencies, damage control surgery (DCS) is recommended in critically ill patients with the deadly triad (hypothermia, acidosis, and coagulopathy) [5,6]. Although this patient had not fell into deadly triad before surgery, development to it during surgery was anticipated. Therefore, the first surgery of this patient was limited to resection of the apparently necrotized part of the intestine as DCS. Consequently, fatal collapse was occurred at not operation room but ICU and ECMO was implemented very quickly by intensivist. If cardiac arrest was happened during surgery, the duration of cardiac arrest might be longer. In addition, indication of ECMO in such cases depends on the result of source control. As the surgery had been finished, the decision to introduce ECMO was easier. In summary, DCS and quick implement of ECMO led to the survival of this patient.

Conclusion

Successful survival of a patient developing cardiac arrest associated with nonocclusive mesenteric ischemia during pregnancy was achieved by damage control surgery and quick introduction of ECMO.

References

1. Yukaya T, Saeki H, Taketani K, Ando K, Ida S, et al. (2014) Clinical outcomes and prognostic factors after surgery for non-occlusive mesenteric ischemia: a multicenter study. *J Gastrointest Surg* 18: 1642-1647.
2. John AS, Tuerff SD, Kerstein MD (2000) Nonocclusive mesenteric infarction in hemodialysis patients. *J Am Coll Surg* 190: 84-88.
3. Trompeter M, Brazda T, Remy CT, Vestring T, Reimer P (2002) Non-occlusive mesenteric ischemia: etiology, diagnosis, and interventional therapy. *Eur Radiol* 12: 1179-1187.
4. Liebman PR, Patten MT, Manny J, Benfield JR, Hechtman HB (1978) Hepatic--portal venous gas in adults: etiology, pathophysiology and clinical significance. *Ann Surg* 187: 281-287.
5. Rotondo MF, Schwab CW, McGonigal MD, Phillips GR 3rd, Fruchterman TM, et al. (1993) 'Damage control': an approach for improved survival in exsanguinating penetrating abdominal injury. *J Trauma* 35: 375-382.
6. Weber DG, Bendinelli C, Balogh ZJ (2014) Damage control surgery for abdominal emergencies. *Br J Surg* 101: e109-118.