

A Case of Idiopathic Non-Cirrhotic Portal Hypertension

Reza F. Saidi^{1,*}, Marc Leduc¹, Hwajeong Lee², Nadeem Anwar³, Shimul Shah¹, Nicolas Jabbour¹ and Adel Bozorgzadeh¹

¹Division of Organ Transplantation, Department of Surgery, University of Massachusetts Medical School, Worcester, MA

²Department of Pathology, University of Massachusetts Medical School, Worcester, MA

³Department of Medicine, University of Massachusetts Medical School, Worcester, MA

Dear Editor

Idiopathic Non-Cirrhotic Portal Hypertension (INCPH) is a rare cause of portal hypertension. Its etiology is still unknown but its prognosis is excellent. Herein, we report a case of a 21 year old gentleman who was found to be thrombocytopenic on routine lab work before right anterior cruciate ligament repair. He had no other symptoms on initial presentation. He denied any history of GI bleeding, encephalopathy, ascites, jaundice, or abdominal distention. His past medical and family history were negative.

On examination his blood pressure was 140/80, HR 52/min, and he was afebrile. He was non-icteric. His exam was benign except for soft a palpable spleen 2 cm below the costal margin. He was hemocult negative. He had a creatinine of 1.12, Bilirubin of 1.4, AST of 26 and ALT of 56. His platelet count was 76,000, hematocrit 48.9, and hemoglobin 16.5. His INR was 1.1. Hepatitis B surface antibody was positive due to vaccination. HBS negative core antibody, Hepatitis A and C serologies were negative. His EBV serologies were negative.

A bone marrow biopsy did not reveal any hematological cause of his thrombocytopenia. He also underwent a CT scan of the abdomen which showed splenomegaly, enlarged intra-abdominal varices, and Grade II esophageal varices which required banding. Liver ultrasound showed patent vasculature. He underwent a transjugular liver biopsy with hepatic vein and wedge pressure measurements as well as hepatic vein venograms. His venography showed a normal course, caliber and branching, his hepatic vein and wedge pressures were 12 and 21 mm Hg respectively with a corrected sinusoidal gradient of 8. His biopsy showed vascular abnormalities (megasinusoids) and irregularly distributed vessels without fibrosis associated with focal nodular regenerative change suggestive of INCPH (Figure 1). He underwent variceal banding. He is currently doing very well.

Portal hypertension is a clinical syndrome defined by a portosystemic venous pressure gradient exceeding 5 mm Hg. [1] Liver cirrhosis is the most frequent cause of portal hypertension in the western hemisphere. However, in a variety of disorders, portal hypertension develops in the absence of cirrhosis. This condition is referred to as noncirrhotic portal hypertension. [1] The most common cause of noncirrhotic

portal hypertension worldwide is schistosomiasis. [2] In the Western world, chronic liver diseases, such as nonalcoholic steatohepatitis, primary biliary cirrhosis, primary sclerosing cholangitis and congenital hepatic fibrosis together with extrahepatic portal vein thrombosis and Budd-Chiari syndrome are common causes of noncirrhotic portal hypertension. Chronic arsenic toxicity is also one of the causes of non cirrhotic portal fibrosis [3]. If all these conditions have been ruled out, the diagnosis of INCPH can be made. [4-6] In the Western world INCPH might be responsible for 3%-5% of cases of portal hypertension. [6] Majority of the patients are asymptomatic but some present with GI bleeding or splenomegaly. Currently, liver biopsy remains essential in the diagnosis of INCPH. Histopathological characteristics of INCPH are heterogeneous, demonstrating overlap between several pathological entities (e.g., hepatoportal sclerosis, nodular regenerative hyperplasia, and incomplete septal cirrhosis). [4] INCPH is regarded as a relative benign disorder (5-year survival of nearly 100%). Despite the fact that data regarding treatment of variceal bleeding in INCPH patients are lacking, following the guidelines regarding cirrhotic variceal bleeding has been recommended. In general, prognosis and survival of INCPH patients is good [6].

References

- Hillaire S, Bonte E, Denninger MH, Casadevall N, Cadranel JF, et al. (2002) Idiopathic non-cirrhotic intrahepatic portal hypertension in the West: a re-evaluation in 28 patients. *Gut* 51: 275-280.
- Basu AK, Boyer J, Bhattacharya R, Mallik KC, Sen Gupta KP (1967) Non-cirrhotic portal fibrosis with portal hypertension: a new syndrome. I. Clinical and function studies and results of operations. *Indian J Med Res* 55: 336-350
- Mazumder DN (2005) Effect of chronic intake of arsenic contaminated water on liver. *Toxicol Appl Pharmacol* 206: 169-175
- Sarin SK, Kumar A, Chawla YK, Bajjal SS, Dhiman RK, et al. (2007) Noncirrhotic portal fibrosis/idiopathic portal hypertension: APASL recommendations for diagnosis and treatment. *Hepatol Int* 1: 398-413.
- Eapen CE, Nightingale P, Hubscher SG, Lane PJ, Plant T, et al. (2011) Non-cirrhotic intrahepatic portal hypertension: associated gut diseases and prognostic factors. *Dig Dis Sci* 56: 227-235.
- Sarin SK, Kapoor D (2002) Non-cirrhotic portal fibrosis: current concepts and management. *J Gastroenterol Hepatol* 17: 526-534.

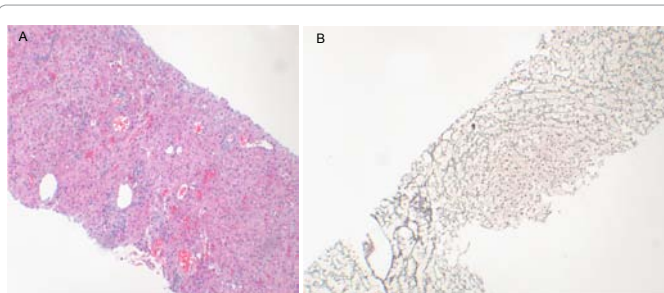


Figure 1: Liver biopsy showed (A); Clusters of dilated sinusoids (megasinusoids), and irregularly distributed vascular profiles, (B) Reticulin stain shows vague nodularity of the liver parenchyma without evidence of cirrhosis.

*Corresponding author: Reza F. Saidi, MD, Assistant Professor of Surgery, Division of Organ Transplantation, Department of Surgery, University of Massachusetts Medical School, 55 Lake Avenue North, S6-426, Worcester MA, 01655, Tel: (508) 334-2023, Fax: (508) 856-1102, E-mail: Reza.Saidi@umassmemorial.org

Received February 22, 2012; Accepted March 28, 2012; Published April 01, 2012

Citation: Saidi RF, Leduc M, Lee H, Anwar N, Shah S, et al. (2012) A Case of Idiopathic Non-Cirrhotic Portal Hypertension. *J Liver* 1:104. doi:10.4172/2167-0889.1000104

Copyright: © 2012 Saidi RF, et al. This is an open-access article distributed under the terms of the Creative Commons Attribution License, which permits unrestricted use, distribution, and reproduction in any medium, provided the original author and source are credited.