

A Case of Atypical Acanthamoeba Keratitis with Cruciate Stromal Infiltration

Yeon Soo Kang, Hyo Seok Lee, Won Choi and Kyung Chul Yoon*

Department of Ophthalmology, Chonnam National University Medical School and Hospital, Gwangju, South Korea

*Corresponding author: Kyung Chul Yoon, Department of Ophthalmology, Chonnam National University Medical School and Hospital, 42 Jebong-ro, Dong-gu, Gwangju, 501-757, South Korea, Tel: 82-62-220-6741; Fax: 82-62-227-1642; E-mail: kcyoon@jnu.ac.kr

Received date: August 17, 2016; Accepted date: October 10, 2016; Published date: October 14, 2016

Copyright: © 2016 Kang YS, et al. This is an open-access article distributed under the terms of the Creative Commons Attribution License, which permits unrestricted use, distribution, and reproduction in any medium, provided the original author and source are credited.

Abstract

Purpose: To report a case of atypical Acanthamoeba keratitis (AK) with cruciate stromal infiltration, which was successfully treated.

Case report: A 16-year-old woman with a history of intermittent soft contact lens wear was referred to our eye center. At presentation, her best-corrected visual acuity (BCVA) was 3/20 in the right eye. Slit lamp examination showed irregular epithelial infiltration, and mild edema in the cornea of the right eye. Topical antibiotics and antiviral agents were applied. After 1 week, her BCVA in the right eye decreased to counting fingers and epithelial infiltration was aggravated. Diffuse cruciate stromal infiltration newly developed. Under the presumptive diagnosis of AK, topical antibiotics and antiviral agents were stopped, and topical 0.02% chlorhexidine was started. After 2 weeks of treatment, the stromal infiltration decreased and culture was positive for Acanthamoeba species. After 3 months of treatment, the cornea was clear and her BCVA was 20/20 in the right eye.

Conclusions: Atypical AK can present as cruciate stromal infiltration and can be treated successfully with topical 0.02% chlorhexidine.

Keywords: Acanthamoeba keratitis; Cruciate stromal infiltration

Introduction

Acanthamoeba keratitis (AK) is a severe sight threatening corneal infection [1] and the number of patients with AK has increased dramatically in the last few decades [2]. In previous studies, AK primarily affected otherwise healthy contact lens wearers and young females [3].

Its symptoms are often nonspecific; severe pain, photophobia, and blurred vision may be present in bacterial, viral, and fungal keratitis [4]. Classic signs (eg, ring-shaped stromal infiltration, radial perineuritis, and limbitis) are not always present [5-7]. Diagnosis of AK is challenging because of these nonspecific symptoms and signs. Delays in proper diagnosis have been correlated with more extensive disease, greater likelihood of requiring keratoplasty, and worse final visual acuity [8].

Herein, we report a case of atypical AK with cruciate stromal infiltration, which was treated successfully with topical 0.02% chlorhexidine.

Case Report

A 16-year-old woman presented with a 2-week history of pain and decreased visual acuity in the right eye. The patient was an intermittent soft contact lens wearer. She had been treated 1 week previously for a herpes simplex keratitis (HSK) and had received topical antiviral

treatment. At presentation, her best-corrected visual acuity (BCVA) was 3/20 in the right eye and 20/20 in the left eye. Slit-lamp examination showed irregular epithelial infiltration and mild edema of the cornea in the right eye. Topical gatifloxacin (Gatiflo; Handok, Chungbuk, Korea) and ganciclovir ointment (Virgan[®]; Spectrum Théa Pharmaceuticals, Macclesfield, UK) four times per day with frequent instillation of artificial tears were prescribed.

After 1 week, her BCVA in right eye decreased to counting fingers. Epithelial infiltration and edema of the cornea were aggravated. Diffuse cruciate stromal infiltration was newly developed (Figure 1A). We suspected AK, and performed corneal culture for Acanthamoeba. Topical gatifloxacin and ganciclovir ointments were stopped and topical 0.02% chlorhexidine was applied hourly.

At 2 weeks, the epithelial and stromal infiltration of the cornea decreased (Figure 1B) and her BCVA improved to 12/20 in the right eye. Corneal culture was positive for Acanthamoeba species. The topical treatment was continued.

At 1 month, the patient was more comfortable. Corneal infiltration was nearly absent, but faint stromal haze was persisted. Topical 0.02% chlorhexidine was tapered to 3 times a day. At 3 months, her cornea was clear (Figure 1C) and BCVA was 20/20 in the right eye.

Discussion

This report emphasizes the need to suspect Acanthamoeba keratitis in contact lens wearers who present with cruciate stromal infiltration and progressively worsening keratitis that is unresponsive to usual antibiotics and antiviral therapy.

Eighty-five percent of AK cases are associated with contact lens use, with the improper use of tap water for contact lens care being the most significant risk factor [9]. Although all contact lens wearers are at risk of microbial keratitis, the epithelial thinning, overnight lens wear and corneal microtrauma that occurs with orthokeratology is considered especially hazardous [10]. Education regarding correct contact lens care is therefore extremely important in these patients.

AK can present with a dendritiform pattern of epithelial erosion that is frequently mistaken for HSK [11], and a nummular keratitis that may be confused with adenoviral keratitis [12]. However, the dendritiform pattern of AK does not have the terminal bulbs seen in HSK [13]. AK must be considered in all cases of presumed HSK or adenoviral keratitis in contact lens wearers. Features indicated of AK include pain out of proportion to slitlamp signs, contact lens contamination with tap water, poor response to topical antivirals [14].

Early AK includes epithelial disease such as punctate keratitis, pseudodendrites, and perineuritis without deep stromal involvement and anterior stromal disease such as subepithelial infiltrates [15]. Late AK findings include deep stromal infiltrates with or without epithelial disease and stromal ring infiltrates [16]. However, classic findings of AK such as perineuritis and ring infiltrate were only observed in about 20% of patients [15]. Jiang et al. reported salt-like dense infiltrate dots and groove-shaped corneal melting in 85.6% and 61.1% of patients, respectively [1].

In this study, we reported diffuse cruciate stromal infiltration as an atypical presentation of AK. The patient was treated with topical 0.02% chlorhexidine and visual function was successfully improved. Thus, ophthalmologists should maintain a high level of suspicion of AK in patients with cruciate stromal infiltration.

References

1. Jiang C, Sun X, Wang Z, Zhang Y (2015) Acanthamoeba keratitis: clinical characteristics and management. *Ocul Surf* 13: 164-168.
2. Jones BR, McGill JJ, Steele AD (1975) Recurrent suppurative kerato-uveitis with loss of eye due to infection by Acanthamoeba castellanii. *Trans Ophthalmol Soc U K* 95: 210-213.
3. Chin J, Young AL, Hui M, Jhanji V (2015) Acanthamoeba keratitis: 10-year study at a tertiary eye care center in Hong Kong. *Cont Lens Anterior Eye* 38: 99-103.
4. Gupta R, Gorski M, Henderson T, Lazzaro D, Haseeb MA (2015) Clinical Course of Unilateral Acanthamoeba Keratitis in a Cosmetic Contact Lens Wearer. *Ann Clin Lab Sci* 45: 366-370.
5. Sharma S, Garg P, Rao GN (2000) Patient characteristics, diagnosis, and treatment of non-contact lens related Acanthamoeba keratitis. *Br J Ophthalmol* 84: 1103-1108.
6. Mathers WD, Sutphin JE, Folberg R, Meier PA, Wenzel RP, et al. (1996) Outbreak of keratitis presumed to be caused by Acanthamoeba. *Am J Ophthalmol* 121: 129-142.
7. Kovacević D, Misljenović T, Misljenović N, Mikulčić M, Dabeska-Novkovski D (2008) Acanthamoeba keratitis--importance of the early diagnosis. *Coll Antropol* 32 Suppl 2: 221-224.
8. Claerhout I, Goegebuer A, Van Den Broecke C, Kestelyn P (2004) Delay in diagnosis and outcome of Acanthamoeba keratitis. *Graefes Arch Clin Exp Ophthalmol* 242: 648-653.

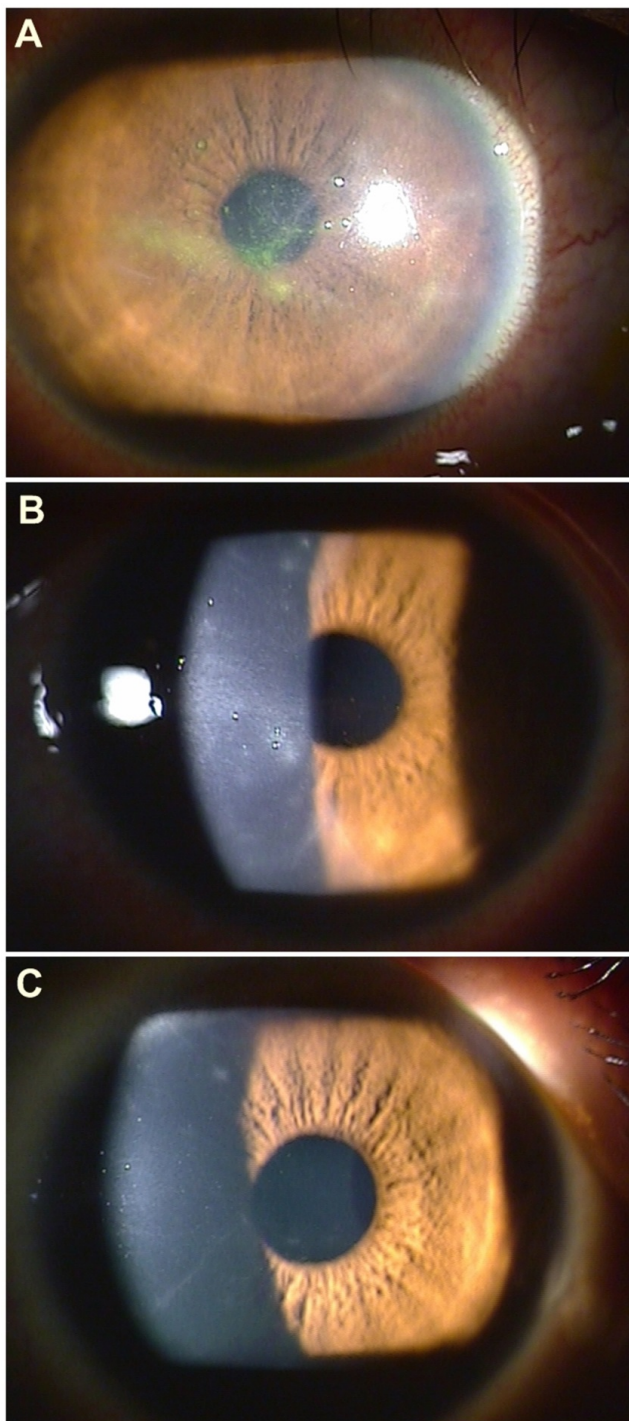


Figure 1: Slit lamp findings of 16-year old woman with a history of intermittent soft contact lens wear. A: After 1 week of treatment with topical antibiotics and antiviral agents, cruciate stromal infiltration was newly developed. Under the presumptive diagnosis of AK, topical antibiotics and antiviral agent were stopped, and topical 0.02% chlorhexidine was started. B: After 2 weeks of treatment, the epithelial and stromal infiltration of the cornea decreased. C: At 3 months, the cornea was clear.

-
9. Greenwell TH, Loh RS, Chehade M, Mills RAD (2013) Misdiagnosis of orthokeratology-related Acanthamoeba keratitis as herpes simplex virus keratitis. *Clin Experiment Ophthalmol* 41: 418-420.
 10. Yepes N, Lee SB, Hill V, Ashenurst M, Saunders PP, et al. (2005) Infectious keratitis after overnight orthokeratology in Canada. *Cornea* 24: 857-860.
 11. Tay-Kearney ML, McGhee CN, Crawford GJ, Trown K (1993) Acanthamoeba keratitis. A masquerade of presentation in six cases. *Aust N Z J Ophthalmol* 21: 237-245.
 12. Reinhard T, Schilgen G, Steinert M, Hacker J, Sundmacher R (2003) Nummular infiltrates in Acanthamoeba keratitis. *Acta Ophthalmol Scand* 81: 541-543.
 13. Perry HD, Donnenfeld ED, Foulks GN, Moadel K, Kanellopoulos AJ (1995) Decreased corneal sensation as an initial feature of Acanthamoeba keratitis. *Ophthalmology* 102: 1565-1568.
 14. Lindsay RG, Watters G, Johnson R, Ormonde SE, Snibson GR (2007) Acanthamoeba keratitis and contact lens wear. *Clin Exp Optom* 90: 351-360.
 15. Qian Y, Meisler DM, Langston RH, Jeng BH (2010) Clinical experience with Acanthamoeba keratitis at the cole eye institute, 1999-2008. *Cornea* 29: 1016-1021.
 16. Ross J, Roy SL, Mathers WD, Ritterband DC, Yoder JS, et al. (2014) Clinical characteristics of Acanthamoeba keratitis infections in 28 states, 2008 to 2011. *Cornea* 33: 161-168.