

# Wolff-Parkinson-White and Prolonged “Q-T” Patterns in the Same Electrocardiographic Record

Francisco R Breijo-Marquez<sup>1\*</sup> and Pardo Ríos M<sup>2</sup>

<sup>1</sup>Department-in-Chief, Murcia University School of Medicine, Department of Clinical and Experimental Cardiology, University Campus.30100, Murcia, Spain

<sup>2</sup>Associate Professor of Cardiology, Murcia University School of Medicine, Department of Clinical and Experimental Cardiology, University Campus.30100, Murcia, Spain

## Abstract

Wolff-Parkinson-White syndrome (WPWS) is a congenital heart disease (PRKAG2. Genetic map 7q36) characterised by a premature ventricular depolarisation caused by an abnormal atrioventricular accessory pathway known as Kent's bundle.

Prolonged QT syndrome (PQTS) consists of an abnormal prolongation of the QT interval on the ECG, which can be both inherited and acquired. This anomaly is known to favour the occurrence of malign cardiac arrhythmias, above all polymorphic ventricular tachycardia, ventricular fibrillation and “torsade de pointes”.

When taken separately, both syndromes have little incidence, which leads us to expect this incidence to be even lower when they are found on the same electrocardiogram. Incidentally, the current medical literature contains no publications on this topic. This clinical case aims to establish the existence of an electrocardiographic pattern characterised by WPW and a PQTS pattern on an ECG record. With a high susceptibility to crisis of tachycardia, especially at night, several episodes of syncope, even cardiac arrest.

The patient is a 24-year-old man. Since childhood, he has suffered from more than four tachycardia attacks, three documented syncope episodes, as well as two cardiac arrests recovered, for which he was treated with electric discharges. Afterwards, he was treated with radiofrequency ablation of Kent's bundle, with permanent positive results so far (Figure 1).

## Some Thoughts on this Case Report

Currently, our research team is working on features and management of this peculiar entity cardiology. Unfortunately, some are unknown to us yet.

The patient was positive for the gene of LQT1 (KCNQ1) (Figure 2).

He had not taken any medication to induce QT interval prolongation.

The fundamental symptoms were strong palpitations (especially at night), crises of severe tachycardia (greater than 250 bpm), episodes of syncope documented, with total reduction of consciousness, hypovolemic shock, reaching suffering two cardiac arrests.

The patient specific medication was never against the long QT, since he was never diagnosed with it: The long QT went unnoticed by your physicians. Our research team was who discovered to the two entities together in the same record ECG.

Although is a WPW intermittent, in all leads there is always a prolonged QT interval (values greater than 0.480 seconds), as can be measured in the ECG recording.

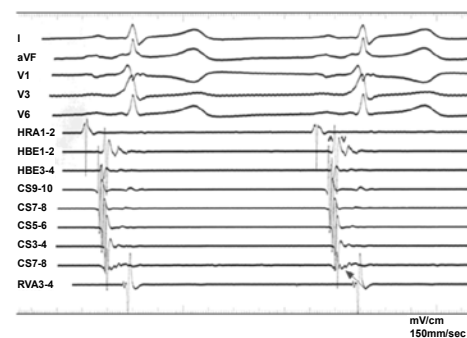
Following ablation, the patient has not suffered similar symptoms so far. Possibly this is because the patient is with sodium blockers as treatment, currently:

Your physicians chose the drug “hydroquinidine hydrochloride” against the WPW (a sodium blocker channels, class I) by orally. Because it has a stabilizing effect on the myocyte membrane and the capsule

form with allows a stable absorption hydroquinidine for 8-12 hours and avoids the “peaks” in the hematic concentration of the substance. The maximum dose is 12.9mg/kg/ day, orally in two intakes each 12 hours. The dose is interrupted or reduced when the arrhythmia is eliminated or improved, or if hypotension occurs, the QRS complex widens by 50% or more, or the maximum dose is achieved.

The risks of intoxication or adverse effects are also lower.

Since the patient remains without symptoms following the radio-frequency ablation, we decided to maintain the current treatment but with strict control of the patient.



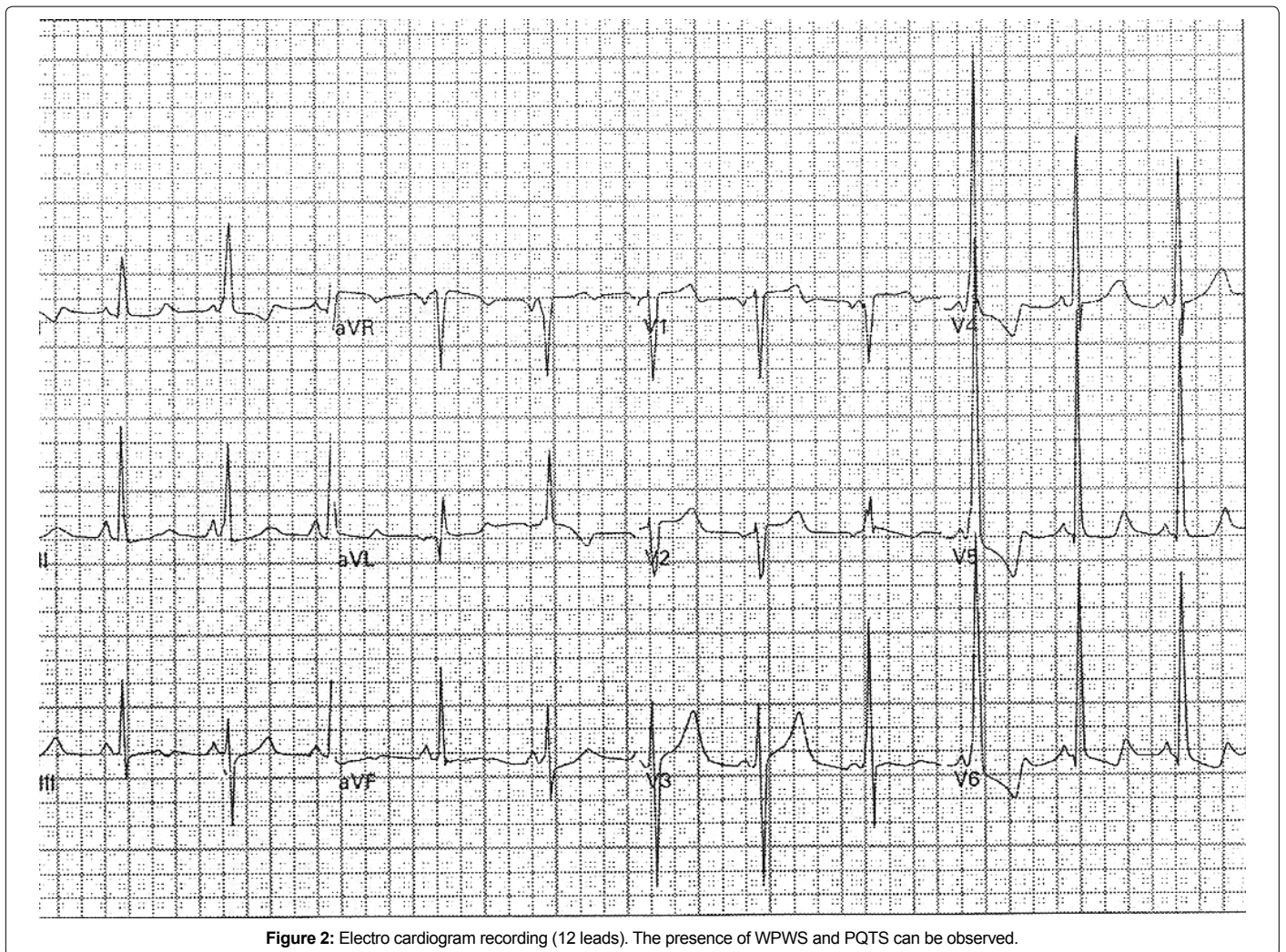
**Figure 1: Electro physiology Study.** In the EPS graphic can be seen (arrow) typical signs of a WPW: Intracardiac electrogram showing under right ventricular pacing, atrial activation precocity in distal coronary sinus followed by His bundle.

\*Corresponding authors: Francisco R Breijo-Marquez, Murcia University School of Medicine, Department of Clinical and Experimental Cardiology, University Campus.30100, Murcia, Spain, Tel: 968681250 673517585; E-mail: [fbreijo@aol.com](mailto:fbreijo@aol.com)

Received December 16, 2010; Accepted January 19, 2011; Published January 21, 2011

**Citation:** Breijo-Marquez FR, Pardo Ríos M (2011) Wolff-Parkinson-White and Prolonged “Q-T” Patterns in the Same Electrocardiographic Record. J Clin Exp Cardiol 2:118. doi:10.4172/2155-9880.1000118

**Copyright:** © 2011 Breijo-Marquez FR, et al. This is an open-access article distributed under the terms of the Creative Commons Attribution License, which permits unrestricted use, distribution, and reproduction in any medium, provided the original author and source are credited.



QT interval duration following the ablation was similar to the duration before ablation. Ie, a prolonged QT.