

Widening of Mediastinum: Achalasia

Chien-Ming Chao^{1,2} and Wei-Ting Lin^{3,4}

¹Departments of Intensive Care Medicine, Chi Mei Medical Center, Liouying, Tainan, Taiwan

²Department of Nursing, Min-Hwei College of Health Care Management, Tainan

³Department of Orthopaedics, Chi Mei Medical Center, Tainan, Taiwan

⁴Department of Physical Therapy, Shu Zen College of Medicine and Management, Taiwan

*Corresponding author: Wei-Ting Lin, Department of Orthopaedics, Chi Mei Medical Center, Tainan, Taiwan, E-mail: aapriliaa@gmail.com

Received date: February 03, 2015; Accepted date: February 10, 2015; Published date: February 17, 2015

Copyright: © 2015 Lin WT, et al. This is an open-access article distributed under the terms of the Creative Commons Attribution License, which permits unrestricted use, distribution, and reproduction in any medium, provided the original author and source are credited.

Description

A 50-year-old man presented with progressive dysphagia for months. Chest radiography showed widening of mediastinum with heterogeneous density (Figure 1A, arrows).

Computed tomography of chest disclosed significant dilation of thoracic esophagus with diffuse smooth wall thickening, distal beaking-appearance narrowing, and much of fluid and food retention (Figure 1B and C). Therefore, the diagnosis of achalasia was confirmed.

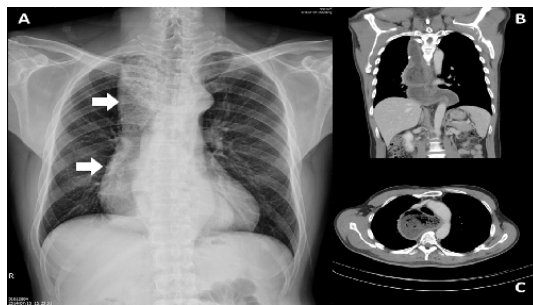


Figure 1: Chest radiography.