

# Changes in the Visual Cortex in Patients with High-Tension Glaucoma

Jan Lešták, Jaroslav Tintěra, Martin Kynčl, Zuzana Svatá\*, Jiří Obenberger and Andrea Saifrtová

JL Clinic, V Hůrkách 1296/10, Prague, Czech Republic

## Abstract

**Objective:** To verify whether there is a correlation between visual field changes in high-tension glaucoma and changes in functional magnetic resonance of the visual cortex.

**Methods and patients:** The authors examined nine patients with high-tension glaucoma in different stages by functional magnetic resonance (fMRI). The measurements were carried out on the Philips Achieva 3T TX MR system using the BOLD method. Optical stimulation was provided by a black and white checkerboard alternated with its negative image with a frequency of 2 Hz. Each measurement consisted of a sequence of five 30-second active phase periods and five resting periods of the same length. The obtained data were processed using SPM8 software.

The complex ophthalmological examination was supplemented by the visual field in the rapid threshold program mode. The sum of sensitivities in the homolateral halves of the visual fields (ranging from 0-22 degrees) was compared to the extent of fMRI contralateral activity of the visual cortex.

The group was compared to a group of eight healthy persons.

**Results:** The obtained data were subjected to a statistical analysis (Non-parametric Spearman's rank correlation coefficient) which showed a medium-grade correlation between the visual field changes and the changes in the visual cortex.  $R=0.667$  ( $p<0.05$ ),  $R=0.767$  ( $p<0.016$ ) respectively.

**Conclusion:** The authors proved that the progression of glaucoma disease corresponds to the functional changes in the cerebral cortex. The loss of ganglion cells of the striate cortex most probably results in the interconnection of the optical radiation with the functional ganglion cells of the temporal lobe.

**Keywords:** High-tension glaucoma, Visual cortex, fMRI

## Introduction

Glaucomas keep being defined as a chronic progressive neuropathy with excavation on the optic nerve disc and subsequent changes in the visual field. This formulation does not, however, correspond to the most recent knowledge and has to be revised. Taking a more up-to-date approach, glaucoma is defined as a disease in which progressive loss of ganglion cells of the retina and their axons demonstrates itself by changes in the visual field and atrophy of the optic nerve with excavation. However, even this definition emphasising damage to ganglion cells prior to its axons is not complete as it does not indicate damage to the ganglion cells of the subcortical and cortical centres of the brain.

Nowadays, there are a number of studies proving damage to the corpus geniculatum laterale and the visual cortex both in experimental animals [1-8].

In our paper, we tried to prove damage to the visual cortex in high-tension glaucoma patients in different stages of the disease.

## Group of patients and methods

Nine patients with different stages of high-tension glaucoma were enrolled in the group (3 females aged 41-65 and 6 males aged 40-73). This group was compared with a group of eight healthy persons (3 females aged 23-46 and 5 males aged 23-65).

## Functional MR imaging

All measurements of functional MR imaging (fMRI) were performed using the Philips Achieva TX SERIES with the magnetic field of 3 Tesla. A standard SENSE RF 8-channel head coil was used for the scanning. Optical stimulation for fMRI was carried out using the Eloquence (InVivo) commercial stimulation system.

fMRI was measured by the BOLD method using a gradient-echo EPI sequence with the following parameters: TE=30 ms, TR=3 s, flip angle 90°. The measured volume consisted of 39 continual slices of 2 mm in thickness and the size of the measured voxel (spatial resolution) was 2 x 2 x 2 mm (FOV=208 x 208 mm, matrix 104 x 104, reconstruction matrix 128 x 128, SENSE factor of 1.8). fMRI was performed in all the subjects. An alternation of a black and white checkerboard (Figure 1) was shown to the subjects during the fMRI acquisition. The alternation was in the form of colour inversion with the frequency of 2 Hz. During the resting phase, the subjects were shown a static cross hair placed in the middle of the visual field. Each measurement consisted of a five 30-second blocks of active phase periods (10 dynamic scans) and five resting periods of the same length. Altogether, each measurement consisted of 100 dynamic scans and lasted 5 minutes.


fMRI assessment was performed using SPM8 software. During the pre-processing, the data were motion corrected (realigned), corrected for slice timing, smoothed the Gauss filter with FWHM of 6 x 6 x 6 mm and finally normalized into the MNI\_152 space. The subject-level statistic was created using a general linear model with the canonical hemodynamic response function (HRF) applied to the stimulation

**\*Corresponding author:** Zuzana Svata, JL Clinic, V Hůrkách 1296/10, Prague, Czech Republic, E-mail: [zuzkasvata@seznam.cz](mailto:zuzkasvata@seznam.cz)

**Received** October 19, 2011; **Accepted** December 15, 2011; **Published** December 19, 2011

**Citation:** Lešták J, Tintěra J, Kynčl M, Svatá Z, Obenberger J, et al. (2011) Changes in the Visual Cortex in Patients with High-Tension Glaucoma. J Clin Exp Ophthalmol S4:002. doi:10.4172/2155-9570.S4-002

**Copyright:** © 2011 Lešták J, et al. This is an open-access article distributed under the terms of the Creative Commons Attribution License, which permits unrestricted use, distribution, and reproduction in any medium, provided the original author and source are credited.



**Figure 1:** illustrates the black and white (BW) checkerboard used for the stimulation. During this stimulation the checkerboard was alternated, with its inversion at the frequency of 2 Hz.

paradigm. The statistical maps were thresholded at the level of  $p=0.05$  with FWE correction. The group statistic was carried out using the unpaired t-test with the uncorrected threshold at  $p=0.005$  and the minimum number of continuous voxels being 50 (8 subjects in each group).

### Ophthalmological examination

The complex ophthalmological examination was supplemented by the visual field using the glaucoma program in the rapid threshold program mode (Medmont M700, visual acuity was corrected to short distance). The sum of sensitivities in the homolateral halves of the visual fields (ranging from 0-22 degrees) was compared to the range of contralateral activity of the visual cortex fMRI.

### Statistical processing

Possible dependencies between the visual field changes and changes in the brain were assessed using correlation coefficients arranged in a correlation matrix. Since the data normality requirement in some of the parameters was not fulfilled and distant values sometimes occurred in the group, the non-parametric Spearman's rank correlation coefficient was applied.

The value of the correlation coefficient can be used to distinguish weak ( $|R|<0.3$ ), median ( $0.3<|R|<0.8$ ) and strong ( $|R|>0.8$ ) dependency (correlation).

### Results

The following table present the arithmetic average, median and standard deviation of the measured parameters for the control group and the patients (visual field and fMRI).

Right halves of visual fields (sum of sensitivities in dB)			
	Average	Median	Standard deviation
Control group	2200,25	2196,5	59,598
Patients	1367,22	1493	532,519
Left halves of visual fields (sum of sensitivities in dB)			
Control group	2165,75	2176	69,496
Patients	1396,556	1615	611,179
fMRI of the left occipital hemisphere (voxel numbers)			
Control group	4181,5	3445,5	2365,976
Patients	2981,667	2550	1531,15
fMRI of the right occipital hemisphere (voxel numbers)			
Control group	4414,625	4093	2280,784
Patients	2995,556	2232	1983,546

The resulting correlation coefficient between the right half of the visual field and fMRI activation extent on the left was 0.667 ( $p<0.05$ ). The correlation coefficient between the left halves of the visual fields and fMRI activation on the right was 0.767 ( $p<0.016$ ).

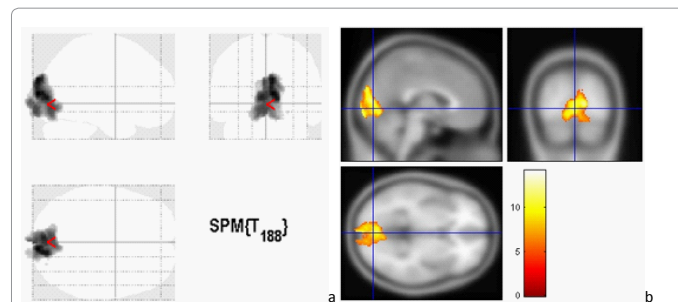
In two patients with the largest changes in the visual fields, neuron activation occurred in the region of the temporal lobes. This observation is proved by the patient whose fMRI finding is illustrated in (Figure 3). It can be suggested that cortex plasticity which may be superior to anatomical relationships enables even patients with substantial alteration of the visual functions to keep at least the rest of those functions. Examination of the visual field in the same patient is illustrated in (Figure 4).

The group statistic results can be seen in (Figures 5 and 6). Compared to the patients, the activation in the controls is more significant only in a narrow region around the medial centre of the occipital gyrus (coordinates in MNI (-6,-100,-3)) and a small region on the lateral surface of the inferior occipital gyrus on the right (39,-66,-13), and also in the frontal lobe (gyrus frontalis inferior (-53,7,13)), (Figure 5).

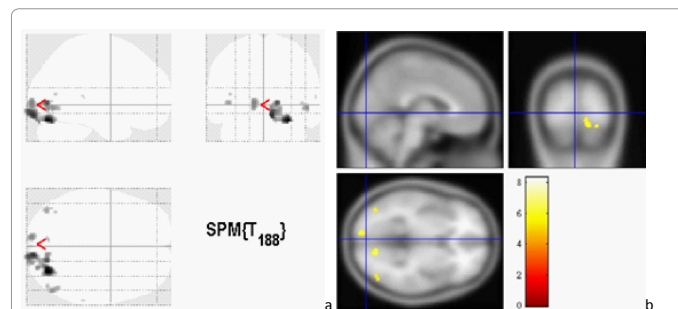
The most significant reaction in patients, when compared to the controls, can be seen bilaterally in the temporal lobes (middle temporal gyrus (-53,-58,22), (-50,-20,-16) and (48,-54,22)), in the right parietal lobe (54,-58,32) and in the medial cingulum and paracingular gyrus (-6,-47,35), (Figure 6).

### Discussion

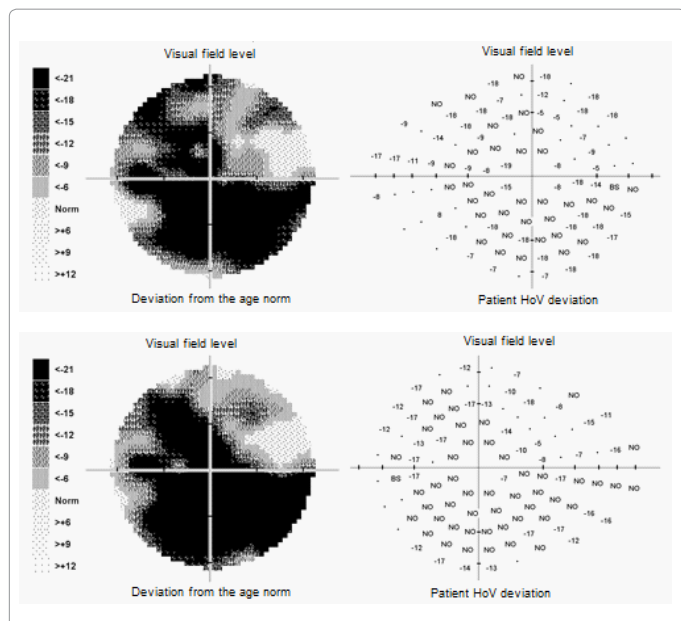
There are not many studies dealing with functional magnetic resonance for glaucoma [9,10], however, all of them proved changes in the visual cortex region.



**Figure 2:** Resulting fMRI images of a selected healthy subject - male aged 65. a) projection of activations in the axial, sagittal and coronal directions, b) orthogonal slices of the selected regions.

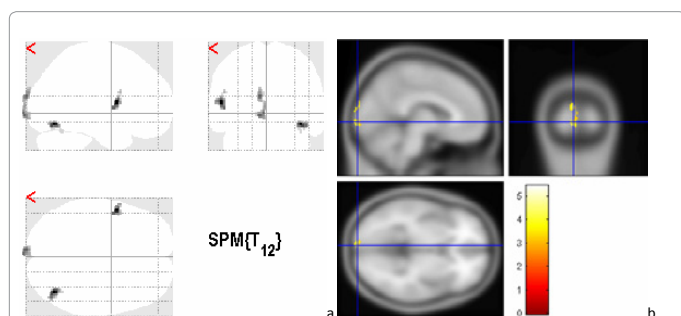


**Figure 3:** Example of fMRI in a patient with secondary glaucoma (male aged 58). A significant drop in neuron activity can be observed. a) projection of activations in the axial and coronal directions, b) orthogonal slices in the selected region.

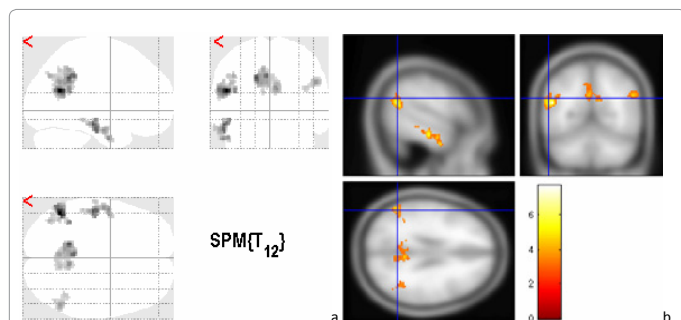


**Figure 4:** Top - right visual field, bottom - left visual field of the same patient. On the left is sensitivity in the visual field shaded in grey, on the right is the sensitivity drop compared to a normal visual field.

No = an absolute scotoma, negative numerical values illustrate the drop in dB.



**Figure 5:** illustrates the regions with statistically high activation in the control group in comparison to the patients, with stimulation using a black and white checkerboard (8 subjects in each group). a) projection of activations in the axial, sagittal and coronal directions, b) orthogonal slices of the selected region.



**Figure 6:** illustrates regions with statistically higher activation in patients when compared with the control group during the stimulation using the black and white checkerboard.

The aim of this study with patients with different changes in the visual field was not only to demonstrate the damage to the central nervous system (CNS) associated with glaucoma, but also the extent of functional changes in the visual cortex depending on the changes in the visual field.

The animal model of glaucoma suggests that retinal ganglion cells have an adverse effect on V1 cells owing to transsynaptic degeneration. There are not many reports of this fact occurring in humans.

Transsynaptic degeneration may play a role in the animal glaucoma model as well [11,12]. The death of retinal ganglion cells may quickly trigger a cascade of actions along the retino-cortical pathways with neurochemical [13], metabolic [2,14], functional [15] and neuropathological consequences for the corpus geniculatum laterale and V1, which may result in neuron loss and their final shrinking [16-19].

It must be emphasised that the measurement of neuron activity changes using fMRI does not provide direct evidence of glaucoma-linked neurodegeneration in CGL or V1. Functional changes in the neuron activity associated with neuronal disease can be independent of the structural changes of neurons/axons in the CNS and vice versa. For example, the current fMRI studies found that the neuronal activity in the cortical representation of the fovea centralis persists despite a clear macular retinal pathology with a loss of foveal vision [20,21].

Cell death in glaucoma is not an important limit of transsynaptic degeneration associated with the glaucoma eye. There is a decrease in the number and size of M and P cells receiving inputs from the non-glaucoma eye in the primate model [19].

Changes in visual fields in glaucoma result from the loss of ganglion cells and their axons in the whole vision system. Zhang et al. [10] were surprised to find a negative correlation between the changes in visual fields (evaluating PSD) and the fMRI activations. This negative correlation means that if PSD values increase with the visual field changes, the fMRI activation extent decreases. In our group, where was compared the sum of sensitivities in the homolateral halves of visual fields, the value of sensitivities in the visual field as well as the fMRI activation extent decrease with the disease progression, i.e. was established a positive correlation. The correlation coefficient between the right half of the visual field and the fMRI activations on the left was 0.667 ( $p < 0.05$ ). The correlation coefficient between the left half of the visual field and the fMRI activations on the right was 0.767 ( $p < 0.016$ ).

On the basis of our results, we believe that the drop in the fMRI activation is not caused by a vascularization disorder in the respective region but is associated with changes in the neurovascular link during oxygen extraction caused by a reduced number of surviving neurons. This so-called transsynaptic degeneration is also advocated by Duncan et al. [9].

## Conclusion

The authors proved that the progression of glaucoma disease corresponds with the functional changes in the visual cortex. The loss of ganglion cells of the striate cortex probably results in the interconnection of optical radiation with the functional ganglion cells of the temporal lobe.

## References

1. Crawford ML, Harwerth RS, Smith EL 3rd, Shen F, Carter-Dawson L (2000) Glaucoma in primates: Cytochrome oxidase reactivity in parvo- and magnocellular pathways. Invest Ophthalmol Vis Sci 41: 1791-1802.

2. Crawford ML, Harwerth RS, Smith EL 3rd, Mills S, Ewing B (2001) Experimental glaucoma in primates: changes in cytochrome oxidase blobs in V1 cortex. *Invest Ophthalmol Vis Sci* 42: 358–364.
3. Chan KC, So KF, Wu EX (2009) Proton magnetic resonance spectroscopy revealed choline reduction in the visual cortex in an experimental model of chronic glaucoma. *Exp Eye Res* 88: 65-70.
4. Gupta N, Yucel YH (2001) Glaucoma and the brain. *J Glaucoma* 10: S28–29.
5. Gupta N, Ang LC, Noël de Tilly L, Bidaisee L, Yücel YH (2006) Human glaucoma and neural degeneration in intracranial optic nerve, lateral geniculate nucleus, and visual cortex. *Br J Ophthalmol* June 90: 674–678.
6. Gupta N, Greenberg G, de Tilly LN, Polemidiotis M, Yucel YH (2009) Atrophy of the lateral geniculate nucleus in human glaucoma detected by magnetic resonance imaging. *Br J Ophthalmol* 93: 56-60.
7. Duncan RO, Sample PA, Weinreb RN, Bowd C, Zangwill LM (2007) Retinotopic organization of primary visual cortex in glaucoma: a method for comparing cortical function with damage to the optic disc. *Invest Ophthalmol Vis Sci* 48: 733-744.
8. Boucard CC, Hernowo AT, Maguire RP, Jansonius NM, Roerdink JB, et al. (2009) Changes in cortical grey matter density associated with long-standing retinal visual field defects. *Brain*. July 132: 1898–1906.
9. Duncan RO, Sample PA, Weinreb RN, Bowd C, Zangwill LM (2007) Retinotopic Organization of Primary Visual Cortex in Glaucoma: Comparing fMRI Measurements of Cortical Function with Visual Field Loss. *Prog Retin Eye Res* 26: 38-56.
10. Zhang QG, Wang B, Wang N (2010) Functional fMRI signal changes in primary visual cortex corresponding to the central normal visual field of patients with primary open-angle glaucoma. *Invest Ophthalmol Vis Sci* 51: 4627-4634.
11. Gupta N, Yucel YH (2001) Glaucoma and the brain. *J Glaucoma* 10: S28–29.
12. Gupta N, Yucel YH (2003) Brain changes in glaucoma. *Eur J Ophthalmol* 13: 32–35.
13. Crawford ML, Harwerth RS, Smith EL 3rd, Shen F, Carter-Dawson L (2000) Glaucoma in primates: Cytochrome oxidase reactivity in parvo- and magnocellular pathways. *Invest Ophthalmol Vis Sci* 41: 1791–1802.
14. Smith IELI, Chino YM, Harwerth RS, Rider WHI, Crawford ML (1993) Retinal inputs to the monkey's lateral geniculate nucleus in experimental glaucoma. *Clin Vis Sci* 113–139.
15. Weber AJ, Chen H, Hubbard WC, Kaufman PL (2000) Experimental glaucoma and cell size, density, and number in the primate lateral geniculate nucleus. *Invest Ophthalmol Vis Sci* May 41: 1370-1379.
16. Yucel YH, Zhang Q, Gupta N, Kaufman PL, Weinreb RN (2000) Loss of neurons in magnocellular and parvocellular layers of the lateral geniculate nucleus in glaucoma. *Arch Ophthalmol* 118: 378–384.
17. Yucel YH, Zhang Q, Weinreb RN, Kaufman PL, Gupta N (2001) Atrophy of relay neurons in magno- and parvocellular layers in the lateral geniculate nucleus in experimental glaucoma. *Invest Ophthalmol Vis Sci* 42: 3216–3222.
18. Yucel YH, Zhang Q, Weinreb RN, Kaufman PL, Gupta N (2003) Effects of retinal ganglion cell loss on magno-, parvo-, koniocellular pathways in the lateral geniculate nucleus and visual cortex in glaucoma. *Prog Retin Eye Res* 22: 465–481.
19. Nguyen TH, Stievenart JL, Saucet JC, Le Gargasson JF, Cohen YS, et al (2004) Cortical response to age-related macular degeneration (Part II). Functional MRI study. *J Fr Ophtalmol* 27: 72–86.
20. Baker CI, Peli E, Knouf N, Kanwisher NG (2005) Reorganization of visual processing in macular degeneration. *J Neurosci*. 25: 614–618.

This article was originally published in a special issue, **Glaucoma** handled by Editor(s). Dr. Zaher Sbeity, University of Bonn, Germany