

Ventricular Septal Defect in Adults: Analysis of Survival with and Without Interventional Procedures. The Relevant Role of Echocardiography

Nilda Espinola-Zavaleta^{1,5}, Maria Elena Soto^{1*}, Reema Chugh², Christian Buelna-Cano³, Carlos Daniel Higuera Medina⁴, Paola Romano, Albornoz⁵ and Eulo Lupi-Herrera^{1,5}

¹Instituto Nacional de Cardiología "Ignacio Chávez", Mexico City, Mexico

²Kaiser Foundation Hospitals, Panorama City, California, USA

³Summer investigation programme, Baja California University, Mexico City, Mexico

⁴Summer investigation programme, Guadalajara University, Mexico City, Mexico

⁵ABC Medical Center, I.A.P., Mexico City, Mexico

Abstract

Background: Ventricular septal defects (VSDs) are one of the most common congenital heart defects, although many close spontaneously by adulthood.

The main aim of this investigation was a) to investigate by echo the best cut-off value of pulmonary artery systolic pressure (PASP) in relation to VSD size, for defining the surgical or interventional treatment (SIT), b) to compare medical versus SIT results and c) to analyze morbidity and mortality of adults with VSDs.

Material: 193 patients aged ≥ 16 years with VSDs were studied. All had a complete clinical examination, electrocardiogram, chest x-ray and transthoracic echocardiography. Fifty three (27.5%) patients underwent cardiac catheterization.

Results: Seventy (36.3%) were asymptomatic, 119 (61.7%) had cardiomegaly, and 124 (64.2%) pulmonary artery hypertension (PAH). The PASP in small defined VSDs was 38 ± 19 , and in large it was 69 ± 34 mmHg. Twenty one (11%) developed Eisenmenger syndrome (ES). The best cut-off point for PASP was 65 mmHg. The coefficient of correlation between VSD size and degree of PASP was 0.64 ($p \leq 0.000$). Forty-five patients had surgical and 10 interventional VSD closure. The patients who underwent SIT had better survival than those who received medical treatment ($P < 0.000$). There were 32 (16.6%) cardiac deaths.

Conclusions: VSD in adulthood is symptomatic in the majority of cases. The best cut-off point for PASP was 65 mmHg for defining SIT. There were 32 (16.6%) deaths during the follow-up period. Patients with ES had a poor prognosis. Patients who underwent SIT had better survival than those who received medical treatment.

Keywords: Ventricular septal defect; Pulmonary artery hypertension; Echocardiography; Eisenmenger syndrome

Abbreviations: VSDs: Ventricular Septal Defects; SIT: Surgical or Interventional Treatment; PASP: Pulmonary Artery Systolic Pressure; PAH: Pulmonary Artery Hypertension; PVR: Pulmonary Vascular Resistance; LV: Left Ventricle; RV: Right Ventricle; LA: Left Atrium; LVEF: Left Ventricular Ejection Fraction; CHD: Congenital Heart Defects; ES: Eisenmenger Syndrome

Introduction

Although VSDs are one of the most common congenital heart defects (CHD) at birth, in the adults they are relatively rare, because the majority of them close spontaneously [1]. The prevalence of this CHD is 1.17 per 1000 live births, or 0.5% per 1000 adults; however the numbers have increased lately due to the detection by improved diagnostic techniques [2].

The morphological classification of VSDs depends on their location. The types of VSDs are: perimembranous (80%), muscular or trabecular (5-20%), inlet (8%), and infundibular that are also called suprasternal, subpulmonary, or doubly committed subarterial (5-7%) [3].

By the hemodynamic classification, the VSDs are defined as restrictive or nonrestrictive, based upon the physiologic consequences resulting from the size of the defect and on the pulmonary vascular resistance (PVR). Restrictive VSDs are usually small in size and have a left to right shunt. In nonrestrictive VSDs, the pulmonary arterial and aortic pressures are equal so the magnitude and direction of the shunt is determined by the PVR.

Eisenmenger's syndrome includes all systemic-to-pulmonary shunts due to large defects leading to a severe increase in PVR and resulting in a reversed (pulmonary-to-systemic) or bidirectional shunt [4].

Echocardiography is a sensitive, descriptive tool with an excellent detection rate (88%-95%). Its accuracy depends upon the size, location of the defect and on the operator experience [5,6]. It also provides an accurate hemodynamic assessment of the shunt, volume overload severity, subpulmonary and pulmonary stenosis and PAH [7]. It also helps in assessment of concomitant defects such as aortic regurgitation secondary to aortic valve distortion and prolapse seen in infundibular/double committed subarterial VSDs due to the Venturi effect [8].

***Corresponding author:** Maria Elena Soto, MD, MsSc, Instituto Nacional de Cardiología "Ignacio Chávez", Juan Badiano N° 1, Colonia Sección XVI, Delegación Tlalpan, C.P. 14080, Mexico City, Mexico, E-mail: mesoto50@hotmail.com

Received December 22, 2011; **Accepted** January 31, 2012; **Published** February 02, 2012

Citation: Espinola-Zavaleta N, Soto ME, Chugh R, Buelna-Cano C, Higuera Medina CD, et al. (2012) Ventricular Septal Defect in Adults: Analysis of Survival with and Without Interventional Procedures. The Relevant Role of Echocardiography. J Clin Exp Cardiol 3:192. doi:10.4172/2155-9880.1000192

Copyright: © 2012 Espinola-Zavaleta N, et al. This is an open-access article distributed under the terms of the Creative Commons Attribution License, which permits unrestricted use, distribution, and reproduction in any medium, provided the original author and source are credited.

The aim of this investigation was a) to find the best cut-off value of PASP in relation to the VSD size (large or small VSD based on size over or less than 10 mm, respectively), in order to best define the SIT, b) to compare the medical versus SIT in relation to mortality and c) to analyze the morbidity and mortality of adults with VSDs.

Material and Methods

From January 2000 to January 2008, we studied 193 patients aged ≥ 16 years with VSDs from our outpatient clinic. All patients had a complete clinical examination, an electrocardiogram, a chest x-ray and a transthoracic echocardiogram. They were 107 women (55.4%) and 86 men (44.6%), with a mean age of 34 ± 10.8 years (range: 17-71).

The follow-up period was considered from the patient's 16th birthday to the year that he/she was last seen. The median follow-up period was 6 years (ranging from 1 to 53 years).

Cardiomegaly was defined as a transverse diameter $\geq 50\%$ of the transverse diameter of the chest, measured on the chest X-ray. Fifty three patients (27.5%) underwent heart catheterization.

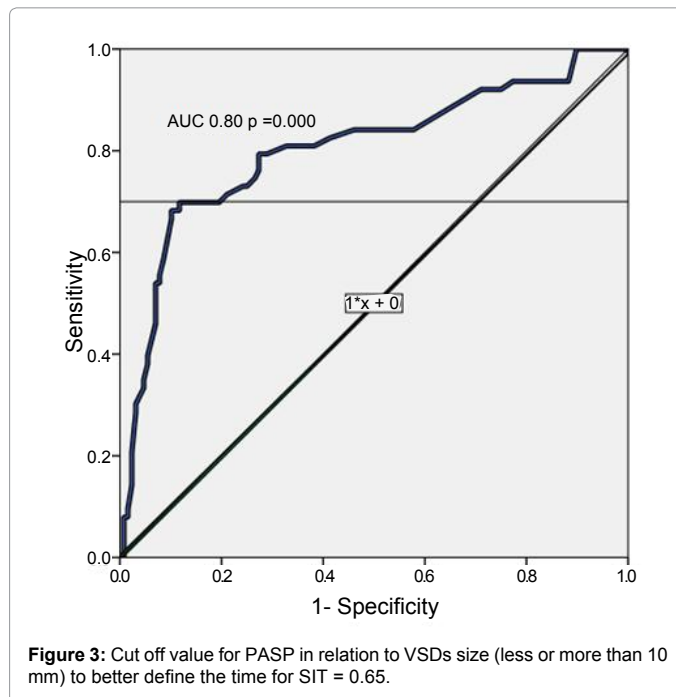
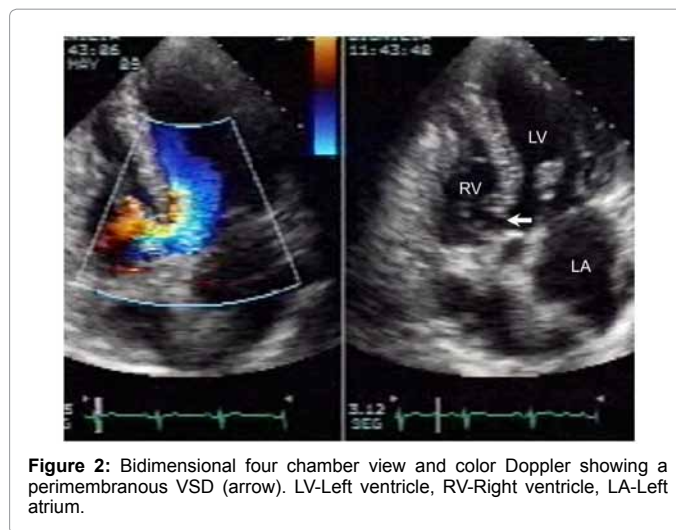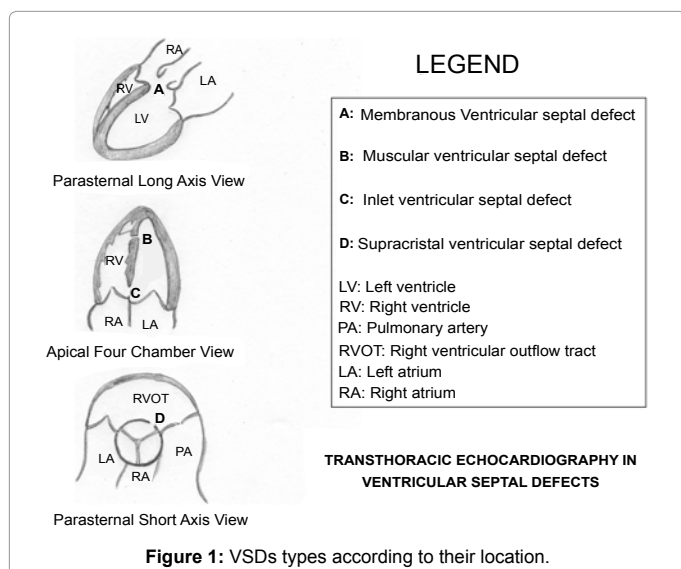
Echocardiographic protocol

The parasternal long axis view was used for imaging defects in all portions of the infundibular septum and segments of the trabecular septum. The parasternal short-axis view allows imaging of the membranous septum and assessment of the extent of the defect in this portion of the septum. The short axis view through the two atrioventricular valves allows visualization of the inlet septum as well as anterior and superior portions of the trabecular septum.

The apical four-chamber view was used for imaging the inlet septum. This view also provides information about the alignment of the muscular and infundibular septa.

The absolute size of VSDs was measured in above mentioned echocardiographic planes according to the type.

In patients with VSDs without ventricular outflow obstruction, the pressure difference between the left and right ventricle was calculated from the peak velocity of the systolic jet [9,10]. The right ventricular systolic pressure was calculated as: $RV \text{ systolic pressure} = \text{systolic arm blood pressure} - (\text{peak velocity})^2 \times 4$ [11].



Small VSDs were defined as having a maximum diameter less than 10 mm, with a left-to-right shunt of 2:1, and PASP < 40 mmHg [12].

The left-to-right shunt volume of VSDs was measured as previously described [13].

The studies were interpreted by two expert echo cardiographers.

The indication for surgical treatment of the Cardiologist were the presence of left-to-right shunt calculated by echocardiography associated with clinical repercussion, and for interventional treatment were left-to right shunt and muscular and perimembranous VSDs in this cases was very important the diameter of edge below the aortic annulus, no minor of 2mm.

Statistical analysis

Descriptive characteristics of normal continuous variables were

expressed as mean \pm 1 SD and categorical variables as absolute numbers and/or percentages. Non-normal data were presented as median and interquartile range. Measurement of absolute and relative frequencies and direct comparison of proportions were performed to assess differences according to variables tested. For the Bivariable analysis Student's test, χ^2 test and Fisher's exact test were used as appropriate, and Cox regression was used for multivariate analysis.

The receiver operating characteristic (ROC) curve was constructed to assess the cut-off value of PASP in relation to the size of the VSD (greater than or less than 10 mm), in order to determine the timing for SIT.

The Kaplan-Meier test was used for survival analysis. Covariates were the size of VSD and the PASP. A P-value of <0.05 was considered significant. Statistical analysis was performed by the SPSS 12.0 software Packaged (Chicago, IL, USA).

Results

Clinical data, electrocardiographic and chest x-ray findings (Table 1).

Seventy patients (36.3%) were asymptomatic during the study period. One hundred and twenty three patients (63.7%) had dyspnea (112 had exertional, 8 had orthopnea and 3 had paroxysmal nocturnal dyspnea).

The most common electrocardiographic findings were: right bundle branch block, right ventricular enlargement, left ventricular enlargement, right ventricular hypertrophy and left bundle branch block. Seventy four patients (38.3%) with a small VSD had a normal cardiac silhouette and pulmonary vascularity, and 119 (61.7%) had cardiomegaly (Table 1).

Echocardiography

The interobserver variability in this study was of 0.97.

The types of VSDs based upon location are summarized in Table 2, (Figure 1). The size (Figure 2) and gradient of VSDs, diastolic and systolic diameters of the left ventricle, left ventricular ejection fraction and PASP are shown in Table 3. Small VSD's (< 10 mm) had median PASP of 28.5 mmHg (range: 27-30), median Qp/Qs of 1.2 (range 0.77-4).

One hundred and thirty patients (67.4%) had a small and 63 (32.6%) had large VSDs. The PASP was normal in 69 patients (35.8%) and 124 (64.2%) had PAH (Table 4). The mean calculated PASP in small VSDs was 38 ± 19 mmHg, and in large was 69 ± 34 mmHg.

Twenty one patients (11%) had ES. The mean age of this group was 35.4 ± 10 years.

The best cut-off point for PASP was 65 mmHg as shown in figure 3, categorized according to the size of VSD (less or more than 10 mm), with a sensitivity of 68% and a specificity of 98%.

The coefficient of correlation (r) for VSD size and the degree of PASP was 0.64 (Figure 4).

The median for PASP by hemodynamic assessment was 65 mmHg (range: 17 to 140 mmHg). The coefficient of correlation (r) between the degree of PASP determined by echocardiography and the degree of PASP determined by right heart catheterization was 0.67.

One hundred and forty nine (77.2%) patients had an isolated VSD, of these five (2.6%) had Down syndrome and forty four (22.8%) had associated CHD. Atrial septal defect, patent ductus arteriosus and/or pulmonary stenosis were the most common findings, seen in 36 patients (18.6%) (Table 5).

Clinical data	n	%	Electrocardiogram	n	%	Cardiothoracic ratio	n	%
Dyspnea	123	63.7	Right bundle branch block	46	23.8	0.50-0.54	49	25.4
Palpitations	33	17.1	Right ventricular enlargement	45	23.3	0.55-0.59	43	22.3
Leg edema	23	11.9	Left ventricular enlargement	32	16.6	0.60-0.6	22	11.4
Chest pain	20	10.4	Right ventricular hypertrophy	28	14.5	≥ 0.65	5	2.6
Cyanosis	18	9.4	Right atrial enlargement	27	14			
Syncope	15	7.8	Left bundle branch block	22	11.4			
Asthenia	13	6.7	Left ventricular hypertrophy	15	7.8			
Headache	10	5.2	Left atrial enlargement	14	7.3			
			Supraventricular arrhythmias	9	4.7			
			Left anterior hemiblock	3	1.6			
			Left posterior hemiblock	1	0.5			

Table 1: Clinical, electrocardiographic and chest x-ray findings in adult VSDs patients.

Type	n	%
Perimembranous	153	79.3
Muscular or trabecular	36	18.6
Subarterial infundibular	4	2.1

Table 2: Type of ventricular septal defects (n=193).

	Size VSD (mm)	Maximun gradient VSD (mmHg)	LV diastolic diameter (mm)	LV systolic diameter (mm)	LVEF (%)	RV diastolic diameter (mm)	Pulmonary artery systolic pressure by ECHO (mmHg)	Pulmonary artery systolic pressure by Catheter (mmHg)
Mean	10.4	69.5	48.0	30.8	61.8	32.5	53	77
SD	6.6	33	8.4	7.7	6.2	5.0	33	43

LV-Left ventricle, RV-Right ventricle, LVEF_left ventricular ejection fraction

Table 3: Echocardiographic and hemodynamic findings.

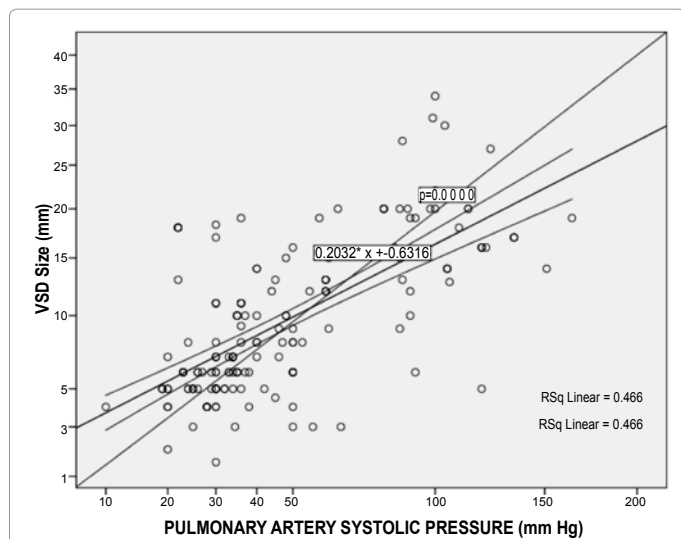


Figure 4: Correlation between the size of VSD and the degree of PASP (r= 0.64).

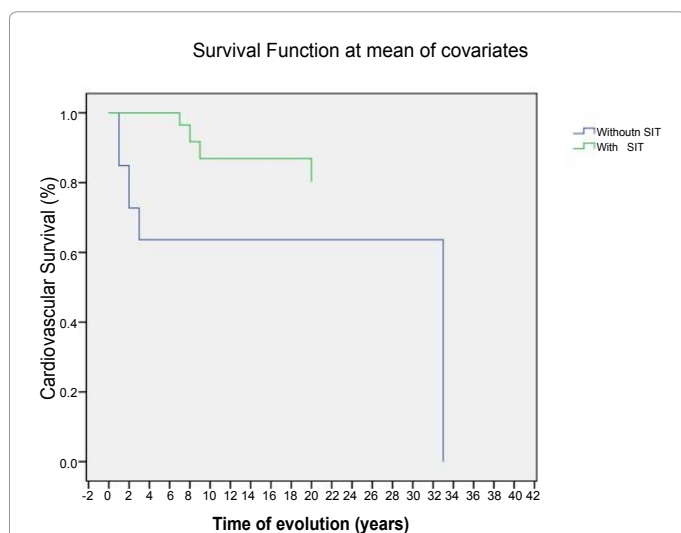


Figure 5: Kaplan Meier analysis showed that patients who received SIT had a better survival (10-year survival = 90%) than those who received medical treatment (10-year survival = 60%), p ≤ 0.000.

Surgical and interventional closure

Forty five had surgical and 10 patients had an interventional closure of the defect in adult life. The mean PASP in these patients was of 37.6 ± 13.8 mmHg. Residual small VSDs were seen in 12 patients (26.7%), regardless of the SIT.

The mean follow-up of surgical patients was 13 ± 11.5 years with a range from 0.5 to 41 years. VSD closed spontaneously between 17 and 25 years of age in 5 patients (2.6%).

Survival

There were 32 (16.6%) deaths during the follow-up period and the mean age at death was 32 years (SD ± 12). Twenty two patients died due to progressive right heart failure (5 of these had associated pneumonia), 3 had infective endocarditis, and 4 had sudden cardiac death.

Those who underwent SIT had better survival in comparison with those who had received medical treatment (Figure 5). The 10-year survival decreased to 50% when the PASP was ≥ 90 mmHg.

Multivariate Cox regression analysis including all strata of PAH showed that survival in our study was affected by the presence of ES and Down syndrome (p < 0.000).

Discussion

VSD is a congenital heart anomaly that can be symptomatic in adulthood in the majority of the cases, as was seen in our patients (63.7%). The most common type of VSD in our study was the perimembranous defect (79.3%), which is similar to what is described in the literature (75% to 80%) [12].

To define the surgical time, the best echocardiographic cut-off value of PAH, categorized according to the VSD size (greater or less than 10 mm) in our series was a PASP of 65 mmHg with a sensitivity of 68% and specificity of 98%, r = 0.64. There was a good correlation between PASP determined by echocardiography compared with that determined by right heart catheterization (r = 0.67). This cut off value of PASP could be used prospectively, although since 1968 surgical treatment has been considered in patients with VSD and PASP less than 61 ± 1 mmHg with good results [14]. According to published experience, in patients with VSD and severe PAH in whom surgical treatment is controversial; a trial with pulmonary vasodilators should be attempted. If the hemodynamic parameters significantly improve with the trial of pulmonary vasodilators, the VSD repair should be performed [15].

One study reported that ES develops in 10% to 15% of cases with VSD [14], as was observed in our study (11%) and this is associated with a poor prognosis. However, studies have shown that CHD patients with ES have a more favorable prognosis when compared with primary pulmonary hypertension in the adult population. Unfortunately, most patients succumb by their fourth decade [14,16].

In our series, 22 (11.3%) patients with ES (one of them had Down syndrome) had a mean PASP was of 97 ± 33 mm Hg and the mean VSD size was of 15.3 ± 6.5 mmHg and these patients died in the fourth decade due to progressive right heart failure. ES and Down syndrome affected the survival of our patients because right ventricular dysfunction. As we know, all these patients were not candidates for SIT.

The treatment of VSD depends on the type of defect, diameters,

	n=124	%
Mild (31-49 mmHg)	41	21.2
Moderate (50-69 mmHg)	43	22.3
Severe (≥ 70 mmHg)	40	20.7

Table 4: Level of pulmonary artery systolic pressure in VSD adult population.

Types	n= 44	%
Atrial septal defect	15	7.8
Patent ductus arteriosus	11	5.7
Pulmonary stenosis	8	4.1
Coarctation of the aorta	3	1.6
Bicuspid aortic valve	3	1.6
Pulmonary stenosis + Patent ductus arteriosus	1	0.5
Patent ductus arteriosus + Coarctation of the aorta	1	0.5
Mitral valve prolapse	1	0.5
Ebstein's anomaly	1	0.5

Table 5: Associated congenital cardiovascular lesions.

shunt severity, PVR, pulmonary vascular reactivity [15], and associated anomalies. In our series, patients who received SIT had a better survival (10-year survival of 90%) than those who were under medical treatment (10-year survival of 60%). Residual VSDs occur in 26.7 % of the cases, regardless of SIT, but these VSDs were small and hemodynamically insignificant.

Spontaneous closure of VSD in adults is uncommon. In our series, it occurs in 2.6% of the cases, between the ages of 17-25 years. Left anterior hemiblock has been described to occur with closure or reduction in size of VSDs in 13.5% [17,18].

Closure occurs as a result of muscular growth around the VSD, ingrowth of border-forming proliferative fibrous tissue, or in the case of membranous defects, resulting from an aneurysm of the tricuspid valve leaflet adhering to the edge of the defect [17] as was seen in some of our patients.

Echocardiography confidently identified the morphologic features of the defect, including its size, type and associated defects⁶. It also provided an accurate hemodynamic assessment of the shunt, severity of volume overload, pulmonary stenosis, and PAH level [5,7].

Limitations

This is a non-randomized retrospective study from a single cardiovascular center.

Right heart cardiac catheterization was performed only in the 27.5% of patients.

VSD patients for SIT were not randomized. Although these limitations are present, it is the first study to report the best echocardiographic cut-off value of PAH categorized according to the VSD size for considering SIT. We also observed additional tools that help to better define VSD patients who showed evidence of post SIT regression of pulmonary vascular resistance-RV remodeling.

Conclusion

Ventricular septal defects can be symptomatic the majority of cases in adulthood. The mean survival depends on size of defect and the degree of PAH and is diminished in patients with a large perimembranous VSD associated with moderate to severe PAH. Patients with ES had a poor prognosis. The principal cause of death was right heart failure.

Echocardiography identified the morphologic features of the VSDs and allowed a hemodynamic assessment of the shunt, severity of volume overload and the degree of PAH.

The patients who underwent SIT had better survival when compared to those who only received medical treatment, where the 10-year survival decreased to 50%.

In order to better define the timing of SIT, the best echocardiography cut-off value of PAH categorized according to the VSD size was PASP below 65 mmHg.

References

1. Congenital heart disease (2000) In Nelson Loose-Leaf Medicine: Division of Cardiovascular Diseases and Internal Medicine. [MN55905]. Mayo Clinic USA, SW Rochester.
2. Martin GR, Perry LW, Ferencz C (1989) Increased prevalence of ventricular septal defect: epidemic or improved diagnosis. *Pediatrics* 83: 200-203.
3. Ventricular Septal Defect (2003) In: The Clinical recognition of Congenital heart Disease. 5th ed, 311. Philadelphia, W.B Saunders Company.

4. Galie N, Hoeper MM, Humbert M, Torbicki A, Vachiery JL, et al. (2009) Guidelines for the diagnosis and treatment of pulmonary hypertension: the Task Force for the Diagnosis and Treatment of Pulmonary Hypertension of the European Society of Cardiology (ESC) and the European Respiratory Society (ERS), endorsed by the International Society of Heart and Lung Transplantation (ISHLT). *Eur Heart J* 30: 2493-2537.
5. Garg A, Shrivastava S, Radhakrishnan S, Dev V, Saxena A (1990) Doppler assessment of pressure gradient across isolated ventricular septal defect. *Clin Cardiol* 13: 717-721.
6. Sutherland GR, Godman MJ, Smallhorn JF, Guiterras P, Anderson RH, et al. (1982) Ventricular septal defects. Two dimensional echocardiographic and morphological correlations. *Br Heart J* 47: 316-328.
7. Kurokawa S, Takahashi M, Katoh Y, Muramatsu J, Kikawada R (1988) Noninvasive evaluation of the ratio of pulmonary to systemic flow in ventricular septal defect by means of Doppler two-dimensional echocardiography. *Am Heart J* 116: 1033-1044.
8. Nadas AS, Thilenius OG, Lafarge CG, Hauck AJ (1964) Ventricular Septal Defect with aortic regurgitation: Medical and Pathologic Aspects. *Circulation* 29: 862-873.
9. Ludomirsky A, Huhta JC, Vick GW 3rd, Murphy DJ Jr, Danford DA, et al. (1986) Color Doppler detection of multiple ventricular septal defects. *Circulation* 4: 1317-1322.
10. Murphy DJ, Jr., Ludomirsky A, Huhta JC (1986) Continuous-wave Doppler in children with ventricular septal defect: noninvasive estimation of interventricular pressure gradient. *Am J Cardiol* 57: 428-432.
11. Marx GR, Allen HD, Goldberg SJ (1985) Doppler echocardiographic estimation of systolic pulmonary artery pressure in pediatric patients with interventricular communications. *J Am Coll Cardiol* 6: 1132-1137.
12. Neumayer U, Stone S, Somerville J (1998) Small ventricular septal defects in adults. *Eur Heart J* 19: 1573-1582.
13. Lewis AB, Takahashi M (1976) Echocardiographic assessment of left-to-right shunt volume in children with ventricular septal defect. *Circulation* 54: 78-82.
14. Clarkson PM, Frye RL, DuShane JW, Burchell HB, Wood EH, et al. (1968) Prognosis for patients with ventricular septal defect and severe pulmonary vascular obstructive disease. *Circulation* 38: 129-135.
15. Lupi-Herrera E, Sandoval J, Seoane M, Bialostozky D, Attie F (1982) The role of isoproterenol in the preoperative evaluation of high-pressure, high-resistance ventricular septal defect. *Chest* 81: 42-46.
16. Hopkins WE, Ochoa LL, Richardson GW, Trulock EP (1996) Comparison of the hemodynamics and survival of adults with severe primary pulmonary hypertension or Eisenmenger syndrome. *J Heart Lung Transplant* 15: 100-105.
17. Somerville J (1979) Congenital heart disease—changes in form and function. *Br Heart J* 41: 1-22.
18. Moe DG, Guntheroth WG (1987) Spontaneous closure of uncomplicated ventricular septal defect. *Am J Cardiol* 60: 674-678.