

# Value of Integrated Tracheal and Lung Sliding Ultrasonography for Affirmation of Proper Endotracheal Tube Placement in Patients Undergoing Intubation for General Anesthesia

Huda Fahmy<sup>1\*</sup> and Sayed Kinawy<sup>2</sup>

<sup>1</sup>Department of Anesthesiology, Aswan University, Aswan, Egypt

<sup>2</sup>Lecture of Chest diseases and tuberculosis, Faculty of Medicine, Aswan University, Aswan, Egypt

\*Corresponding author: Dr Huda Fahmy, Department of Anesthesiology, Aswan University, Aswan, Egypt; E-mail: [huda.fahmy@aswu.edu.eg](mailto:huda.fahmy@aswu.edu.eg)

Received date: August 06, 2019; Accepted date: August 16, 2019; Published date: August 22, 2019

Copyright: © 2019 Fahmy H, This is an open-access article distributed under the terms of the Creative Commons Attribution License, which permits unrestricted use, distribution, and reproduction in any medium, provided the original author and source are credited.

## Abstract

**Background:** integrated tracheal and lung sliding ultrasonography can distinguish tracheal, oesophageal, and endobronchial intubation.

**Aim of the work:** to estimate the accuracy and timelessness of integrated tracheal and lung sliding ultrasonography for realization of proper endotracheal tube placement in patients undergoing intubation for general anesthesia.

**Patients and methods:** This prospective, observational study was carried out in the operative theatre (OT) on 80 patients who required intubation for general anesthesia during elective surgeries. Combined tracheal and lung sliding ultrasonography were done immediately after intubation, a data collection form included the patients' age, gender, BMI, modified Cormack-Lehane score, capnography results, ultrasonography results and the elapsed time before tube position affirmation was collected.

**Results:** Waveform capnography was able to detect endotracheal intubation in 74 (92.5%) patients and oesophageal intubation in six (7.5%) patients. Tracheal ultrasonography (TUS) was able to detect endotracheal intubation in 72 (90%) patients and oesophageal intubation in 8 (10%) patients with 95.95% sensitivity, 83.33% specificity, 98.6 % PPV, 62.5% NPP, 95.00% accuracy. The ultra-sonographic sliding lung sign (SLS) was able to detect proper endotracheal intubation in 69 (86.3%) patients, oesophageal intubation in 6 (7.5%) patients and right main stem intubation in 5 (6.2%) cases with higher specificity, PPV (100% both), but with lower sensitivity, NPP (93.24%, 54.5% respectively) and the diagnostic accuracy was (93.75%). On combining TUS and SLS, the sensitivity and negative predictive values raised to 100% and the diagnostic accuracy rise to (98.75%). The overall duration of ultrasonography was considerably lower than that of capnography ( $P < 0.001$ ) with a mean difference of 5 seconds in favor of ultrasound.

**Conclusion:** The integration of tracheal and lung sliding ultrasonography provide a new protocol for more comprehensive affirmation of proper endotracheal tube position after general anesthesia. Anesthesiologists should be familiar with these procedures to prove both correct intubation and proper ventilation after general anesthesia.

**Keywords:** Tracheal ultrasonography; Ultrasonography sliding lung sign; Endotracheal tube; Endobronchial intubation

one lung intubations may pass undiagnosed by chest auscultation [2-3].

## Introduction

In operation theatre settings, endotracheal intubation is considered a fundamental procedure to preserve the airway during general anesthesia. Assurance of proper endotracheal tube (ETT) placement is crucial immediately after intubation as undiagnosed esophageal intubation can be catastrophic. Screening of anesthesia mortality discovered that 69% of the deaths were related to airway management [1]. Direct visualization of the ETT passing through the vocal cords is often used in practice, but it is not possible at all times, especially if laryngoscopy is difficult. The alternative methods of confirmation include observation of chest rising after intubation and auscultation of both lungs are varying in their degree of accuracy. Moreover, 55% of

Wave form capnography has been considered as the most reliable procedure for confirmation of proper ETT placement with (1.00) sensitivity and (1.00) specificity so that waveform capnography can be approved as the typical technique for the fundamental realization of ETT position [4]. Recent guidelines recommended continuous waveform CO<sub>2</sub> monitoring in addition to clinical evaluation as the most accurate measures to approve the accurate position of an endotracheal tube (ETT). However, End-tidal carbon dioxide (ETCO<sub>2</sub>) measurement requires a minimum of 5 "breathing cycles" for validation, which can lead to gastric insufflation and numerous complications if the ETT was falsely set in the oesophagus, also capnography can't discriminate between main tracheal and endobronchial placement of endotracheal tube [5].

Tracheal ultrasonography (TUS) has proven utility as a non-invasive tool for confirmation of ETT position that occurs in real time and provide appropriated results in patients undergoing general anesthesia. TUS discovers oesophageal intubation even before ventilating the patient, which prevents unnecessary forced ventilation to the stomach and its associated complications [6,7].

Unrecognized one lung intubation may lead to numerous complications. Ultrasonography of the pleura can provide through anatomic data of lung expansion and therefore of ventilation. In normal efficient, ventilated lungs, the 2 layers of pleura (parietal and visceral pleura) can be viewed by ultrasound as distinctive bright borders or echogenic lines. With ventilation, these two layers glide upon each other, this is commonly referred to as the sliding lung sign (SLS) [8], and this should specify endotracheal intubation so the physicians can be able to discriminate between right main stem bronchus and appropriate endotracheal intubation by observing for the lung sliding sign in both sides of chest, as a right main stem bronchus intubation induces absent lung sliding sign on the left lung [9,10].

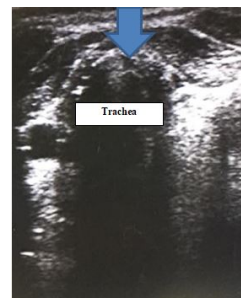
The primary purpose for this study was to determine the diagnostic power of the integrated tracheal and sonographic estimation of pleural sliding for the rapid verification of endotracheal tube location during general anesthesia with reference to CO<sub>2</sub> monitors (capnography) (the typical technique), also to evaluate the capability of SLS to discriminate between main tracheal and right main stem bronchial intubation. A secondary outcome was to determine the elapsed time before validation of endotracheal tube position.

## Patients and Methods

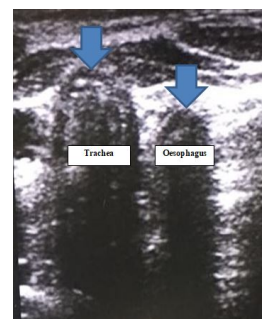
After approval of the ethical committee, this prospective observational study was carried out in the operative theatre (OT) in Aswan University Hospital between September 2018 and March 2019 on 80 patients who required intubation for general anesthesia during elective surgeries. Patients with age less than 18 years, history of difficult intubation, anatomic neck distortion, abnormal airway anatomy or lung pathologies that would affect the study technique were excluded from the study.

On admission to OT, monitors were connected and baseline heart rate, systolic, diastolic and mean arterial blood pressure, pulse oximetry, and ECG were collected. Intubations were done by the anesthesia residents and modified Cormack-Lehane score obtained by direct laryngoscopy based on the structures seen was documented for every intubation trial. Combined bedside ultra-sonography was carried out immediately after intubation by the examiner who was not concerned in the patients' care and not informed about the capnography results.

A SonoScape ultrasound (Model: A5, SonoScape (CHINA) CO, LTD) equipped with a 9-12 MHz linear transducer was used for tracheal and lung sliding ultrasonography. Immediately after intubation, the transducer was placed transversely on the anterior neck just above the suprasternal notch and then shifted to the left to scan whether the oesophagus was empty or distended by ETT (Figure 1). The ETT was defined as "endotracheal" if only a one hyperechoic air-mucosa (A-M) interface with a comet-tail artifact was observed or "intraesophageal" if a second A-M interface, imitating an additional airway (double-tract sign) was seen (Figure 2).



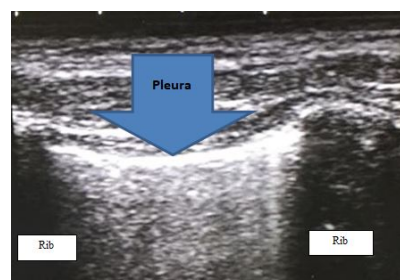
**Figure 1:** Tracheal ultrasonography shows one air-mucosa interface with comet-tail artifact in tracheal intubation.



**Figure 2:** Tracheal ultrasonography shows two air-mucosa interfaces with double-tract sign in oesophageal intubation.

To detect SLS over both lungs, the probe was placed horizontally on both sides; Images were taken within the third to fifth intercostal spaces in the midclavicular line and a positive SLS signified lung expansion with ventilation.

On the basis of the presence or absence of the sliding lung sign on both sides of the chest, a discrimination of endotracheal tube location was made, presence on both sides of the chest was presumed to imply tracheal intubation. SLS presence on the right but absence on the left was assumed to specify right main stem bronchial intubation. Finally, absence of SLS on either side was presumed to denote oesophageal intubation (Figure 3).



**Figure 3:** SLS in ultrasonography.

Subsequently, the correct position of the endotracheal tube was established by the anesthesia resident via the use a capnometer (Scio

Four, Drager, Germany), a positive result of capnography was defined as the finding of exhaled CO<sub>2</sub> (>4 mm Hg) after 5 breathing cycles with a distinctive CO<sub>2</sub> waveform.

An anesthesia technician using a stopwatch calculated the durations from the end of the endotracheal tube insertion to the time when the sonographer had interpreted the sonographic results and to the time of obtaining the results of capnography. A data collection sheet was written down to record the patients' age, gender, BMI, modified Cormack-Lehane score, capnography results, ultrasonography results and the time passed preceding tube position affirmation.

**Statistical analysis:**

Date analysis were done using SPSS (Statistical Package for Social Science) software program version 19.0 (SPSS Inc., Chicago, IL). Data were presented as number, percentage, mean and standard deviation. Pearson correlation was done to measure correlation between quantitative variables. ROC Curve was used to assess the accuracy of TUS, SLS and the combined TUS and SLS against wave form capnography as the standard criterion. P-value was considered statistically significant if <0.05.

**Results**

A total of 80 patients, 35 females (43.75%) and 45 males (56.25%) with mean age 50 years (range 20-74 years) required intubation for general anesthesia during elective surgeries were included in the study between September 2018 and March 2019.

Patients' demographic and clinical characteristics data were summarized in Table 1. Distribution of cases in relation to Modified

Cormack-Lehane score revealed that 70% of intubation attempts were easy, 22.5% were restricted and 7.5% were difficult.

Demographic variable		n=80
Age	Mean ± SD	50 ± 12.31
Gender	Male	45 (56.25%)
	Female	35 (43.75%)
BMI	Mean ± SD	25.62±1.79
ASA	I	26 (32.5%)
	II	54 (67.5%)
Modified Cormack-Lehane score	1	48 (60%)
	2a	8 (10%)
	2b	12 (15%)
	3	6 (7.5%)
	4	6 (7.5%)
Data are presented as mean ± SD; or number and percentage (%)		

**Table 1:** Demographic and clinical data of the studied patients.

A comparison of TUS and SLS results with the continuous capnographic waveform were shown in Table 2.

	Capnography results			
	Positive		Negative	
	No.	%	No.	%
TUS				
Positive	71	95.9	1	16.7
Negative	3	4.1	5	83.3
SLS				
Present (bilaterally)	69	93.2	0	0
Absent (either bilaterally or unilaterally)	5	6.8	6	100
TUS: tracheal ultrasonography; SLS: sliding lung sign; Data are presented as number and percentage (%)				

**Table 2:** A comparison of TUS and ultra-sonographic SLS results with the results of capnography.

Waveform capnography detected endotracheal intubation in 74 (92.5%) patients and oesophageal intubation in six (7.5%) patients. However, tracheal ultrasonography was able to detect endotracheal intubation in 72 (90%) patients and oesophageal intubation in 8 (10%) patients. TUS detected five oesophageal intubations from six cases detected by CO<sub>2</sub> detectors and one detected as positive (false positive), however it did not detect three out of 74 tracheal intubations (false negatives).

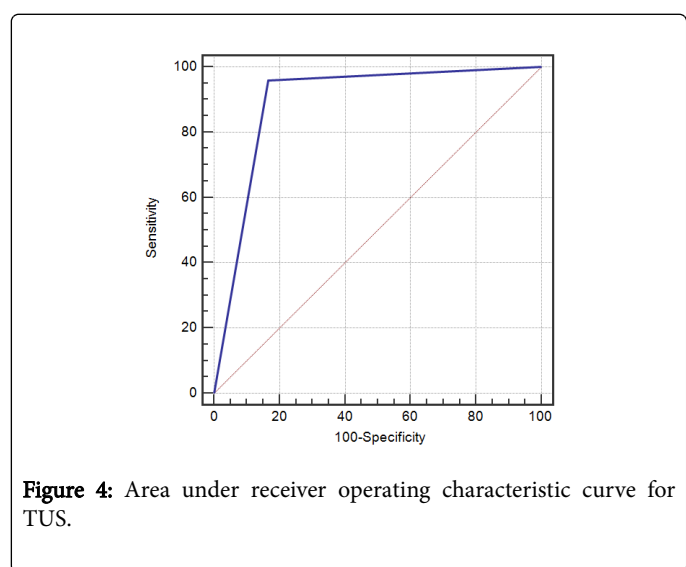
Ultra-sonographic SLS was able to detect proper endotracheal intubation in 69 (86.3%), oesophageal intubation in 6 cases (7.5%) and

right main stem bronchial intubation in 5 (6.2%) cases. SLS correctly detected all six oesophageal intubation; however its presence on the right side and absence on the left was noticed in 5 cases out of 74 tracheal intubations (false negatives) denoted right main stem intubation and ETT was taken out till positive lung sliding gained bilaterally. SLS accurately identified oesophageal placement, but was less accurate in identifying tracheal intubation compared to capnography (Table 3) (Figure 4, 5 and 6).

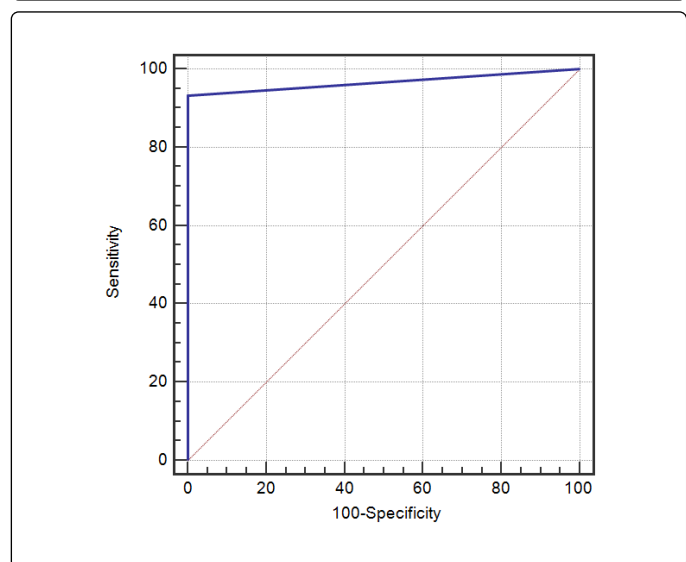
Diagnostic Validity	Sensitivity	Specificity	PPV	NPV	Accuracy	AUC
TUS	95.95	83.33	98.6	62.5	95	0.896
SLS	93.24	100	100	54.5	93.75	0.966
Combined TUS & SLS	100	83.33	98.7	100	98.75	0.917

TUS: Tracheal ultrasonography; SLS: Sliding lung sign; PPV: Positive predictive value; NPV: Negative predictive value; AUC: Area under receiving operating characteristic curve

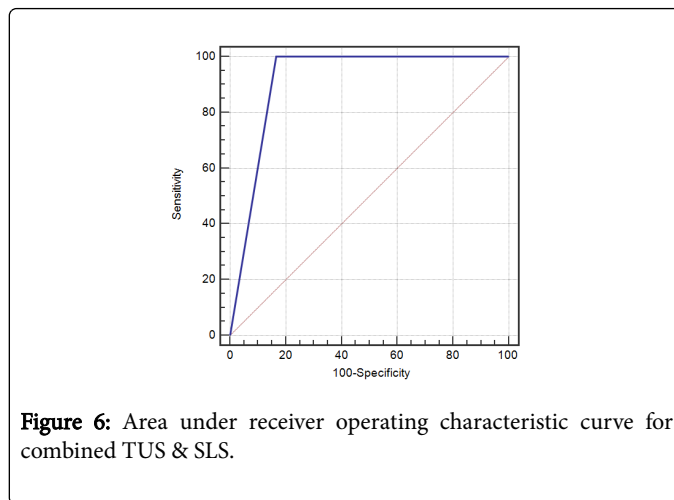
**Table 3:** The Diagnostic test performance of TUS and SLS.



**Figure 4:** Area under receiver operating characteristic curve for TUS.



**Figure 5:** Area under receiver operating characteristic curve for SLS.



**Figure 6:** Area under receiver operating characteristic curve for combined TUS & SLS.

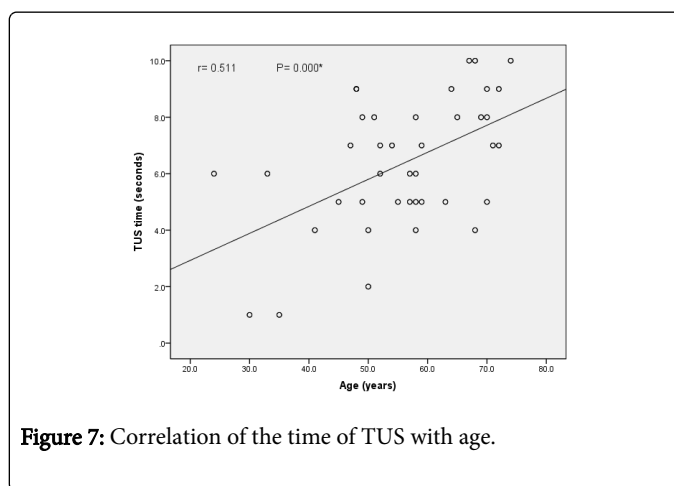
The operating time of TUS, SLS and total ultrasonography time are shown in table 4. The total ultrasonography time was considerably less than that of capnography ( $P \leq 0.001$ ) and the mean difference was 5 seconds in favor of ultrasound. Moreover, the time consumed for performing each of TUS and ultra-sonographic SLS was substantially lower than that of capnography ( $P \leq 0.0001$ , both).

	TUS Time (seconds)	SLS Time (seconds)	Total ultrasonography time (seconds)	Capnography time (seconds)
Mean $\pm$ SD	8.38 $\pm$ 2.29	10.63 $\pm$ 1.45	18.00 $\pm$ 2.99	23.25 $\pm$ 1.96

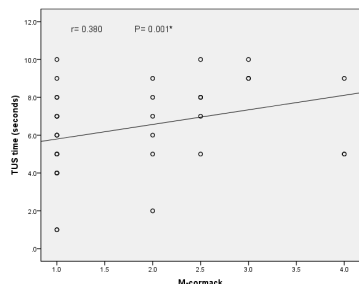
TUS: tracheal ultrasonography; SLS: sliding lung sign; Data are presented as mean  $\pm$  SD

**Table 4:** The elapsed time for the validation of endotracheal tube location.

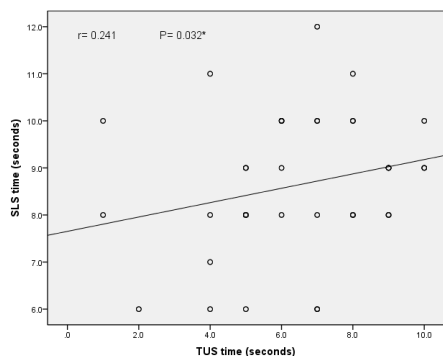
TUS time had substantial positive correlation with the other clinical parameters of our study population including age ( $P=0.0001$ ) and Modified Cormack-Lehane classification score ( $P=0.001$ ) as illustrated in figures 7, 8. Moreover, TUS time had substantial positive correlation with ultra-sonographic SLS time; the longer TUS time was associated with longer SLS time ( $P=0.032$ ) as illustrated in figure 9.



**Figure 7:** Correlation of the time of TUS with age.



**Figure 8:** Correlation of time of TUS with Cormack-Lehane classification score.



**Figure 9:** Correlation of time of TUS with the time of ultrasonographic SLS.

## Discussion

Major catastrophes during general anesthesia result from inability to intubate the trachea following administration of a muscle relaxant and failure to detect it in time [11]. The role of tracheal ultrasonography (TUS) in confirming appropriate endotracheal tube placement during general anesthesia has gained significance not only in the operating room but also in the intensive care unit and emergency department.

A systematic review and meta-analysis by Chou and his colleagues (2015) [12] involving 12 eligible studies together with another one done by Das et al., (2015) [13] included eleven studies and 969 intubations, supported that tracheal ultrasonography has high significance for approving endotracheal intubation and recognizing oesophageal intubation with a reasonable degree of sensitivity and specificity. Moreover, Osman and colleagues (2013) concluded that airway ultrasonography can replace waveform capnography in confirming ETT placement in centers without capnography with an overall accuracy 98.1% [14].

We found that TUS detected five oesophageal intubations from six cases detected by continuous wave form capnography and one detected as endotracheal (false positive) which explained as the esophagus was detected immediately posterior to the trachea in this patient rendering judgment difficult. Moreover, it did not detect three out of 74 tracheal intubations (false negatives), which may explained by that the accuracy of static assessments may possibly less than that of

the dynamic ones because better to visualize the motion artifact with the last technique [15]. In the current study, TUS achieved high sensitivity and PPV (95.95% and 98.6%) with 95.00% accuracy and AUC 0.896 for confirming ETT placement and the consumed time was faster than ETCO<sub>2</sub> time ( $P < 0.0001$ ), these results are in concordance with those obtained by previous studies [16-19].

Unfortunately, TUS and capnography cannot detect adequate endotracheal intubation which means that the tip of the ETT is placed in the trachea and does not proceed beyond the carina into the right main stem bronchus [20-21]. For this reason, TUS may be a good option for primary confirmation of ETT placement but one-lung intubation may be misdiagnosed. As a result, in our study, we integrated ultrasonographic lung sliding sign for secondary confirmation of ETT placement and to exclude right main stem intubation. In the present study, SLS has higher specificity, PPV (100% both) and AUC 0.966 compared to TUS but has lower sensitivity, NPP (93.24%, 54.5% respectively) and overall accuracy 93.75. We suggest that SLS accurately identified oesophageal intubation, but was less accurate in identifying tracheal intubation compared to capnography. On combining TUS to SLS, specificity and negative predictive value raised to 100%, the accuracy was highly precise (98.75%).

In harmony with our results, Sim et al., [22] in their study have described that the overall accuracy of ultrasonographic SLS for confirming ETT placement during emergency intubation was 88.7% with the positive predictive value was 94.7% in the non-cardiac-arrest group and 100% in the cardiac-arrest group. Additionally, in a previous study [23] on 30 patients admitted due to severe airway problems; the Sensitivity, specificity, PPV and NPV for confirming proper endotracheal intubation by transcricothyroid membrane ultrasonography were 96.3%, 100%, 100% and 75%, respectively and after verification by ultrasonographic SLS sensitivity, specificity, PPV and NPV were each 100%. Also, SLS efficacy in ensuring precise placement of the left-sided double lumen tubes is a useful tool as discussed in previous studies [24-26].

In the current study, the mean time elapsed for the confirmation of ETT location by SLS was 10.63 seconds which significantly less than capnography time ( $P < 0.0001$ ), moreover the total ultrasonography time was significantly less than that of capnography ( $P < 0.001$ ) and the mean difference was 5 seconds in favor of ultrasound. In concordance with our results, Pfeiffer et al. noted that the time consumed for performing bilateral lung ultrasound for confirming endotracheal intubation was faster than the standard method of auscultation and capnography in elective surgical patients [27].

## Limitation of the study

First, this study involved patients undergoing intubation for general anesthesia during elective surgeries, this limit the generalization of our results to the resuscitation and intensive care situations. Second, the number of patients is relatively small, so the authentication of our results with greater numbers of participants to decrease selection bias. Third, Ultra-sonography is identified to be operator dependable technique. To our knowledge, no study to date has investigated the role of sonographer experience in accurate documentation of ETT location. Finally, TUS may not be practical for each intubation attempt. The presence of a huge neck masses, abnormality in the upper airway anatomy, soft tissue air, or substantial neck edema can make visualization more difficult to detect ETT position.

## Conclusion

The integrated tracheal and lung sliding ultrasonography could be performed in a stepwise fashion to provide a more comprehensive affirmation of proper ETT position after general anesthesia. Moreover, we revealed a significant time advantage of ultra-sonography over capnography in authorizing appropriate endotracheal intubation.

## Acknowledgements

The author appreciated the anesthesia residents and the anesthesia technicians for their help in this research.

## Financial support and sponsorship

No fund was paid by any institution.

## Conflicts of interest

There were no conflicts of interest.

## References

1. Cook TM, Woodall N, Frerk C (2011) Fourth National Audit Project. Major complications of airway management in the UK: Results of the Fourth National Audit Project of the Royal College of Anaesthetists and the Difficult Airway Society. Part 1: Anaesthesia. *Br J Anaesth* 106: 617-631.
2. Salem MR (2001) Verification of endotracheal tube position. *Anesthesiol Clin North Am* 19: 813-839.
3. Sitzwohl C, Langheinrich A, Schober A, Krafft P, Sessler DI, et al. (2010) Endobronchial intubation detected by insertion depth of endotracheal tube, bilateral auscultation, or observation of chest movements: randomised trial. *BMJ* 341:c5943.
4. Grmec S (2002) Comparison of three different methods to confirm tracheal tube placement in emergency intubation. *Intensive Care Med* 28: 701-704.
5. Link MS, Berkow LC, Kudenchuk PJ, Halperin HR, Hess EP, et al (2015) Part 7: Adult advanced cardiovascular life support: 2015 American Heart Association guidelines update for cardiopulmonary resuscitation and emergency cardiovascular care. *Circulation* 132: S444-S464.
6. Chou EH, Dickman E, Tsou PY, Tessaro M, Tsai YM, et al. (2015) Ultrasonography for confirmation of endotracheal tube placement: A systematic review and meta-analysis. *Resuscitation* 90: 97-103.
7. Chou HC, Chong KM, Sim SS, Ma MHM, Liu SH, et al. (2013) Real-time tracheal ultrasonography for confirmation of endotracheal tube placement during cardiopulmonary resuscitation. *Resuscitation* 84: 1708-1712.
8. Lichtenstein D, Menu Y (1995) A bedside ultrasound sign ruling out pneumothorax in the critically ill: Lung sliding. *Chest* 108: 1345-1348.
9. Weaver B, Lyon M, Blaivas M (2006) Confirmation of endotracheal tube placement after intubation using the ultrasound sliding lung sign. *Acad Emerg Med* 13: 239-244.
10. Sim SS, Lien WC, Chou HC, Chong KM, Liu SH, et al. (2012) Ultrasonographic lung sliding sign in confirming proper endotracheal intubation during emergency intubation. *Resuscitation* 83: 307-312.
11. Takeda T, Tanigawa K, Tanaka H, Hayashi Y, Goto E, et al. (2003) The assessment of three methods to verify tracheal tube placement in the emergency setting. *Resuscitation* 56: 153-157.
12. Chou EH, Dickman E, Tsou P-Y, Tessaro M, Tsai Y-M, et al. (2015) Ultrasonography for confirmation of endotracheal tube placement: a systematic review and meta-analysis. *Resuscitation* 90: 97-103.
13. Das SK, Choupoo NS, Haldar R, Lahkar A (2015) Transtracheal ultrasound for verification of endotracheal tube placement: a systematic review and meta-analysis. *Can J Anaesth* 62: 413-423.
14. Adi O, Chuan TW, Rishya M (2013) A feasibility study on bedside upper airway ultrasonography compared to waveform capnography for verifying endotracheal tube location after intubation. *Crit Ultrasound J* 5: 7.
15. Gottlieb M, Holladay D, Peksa GD (2018) Ultrasonography for the confirmation of endotracheal tube intubation: a systematic review and meta-analysis. *Ann Emerg Med* 72: 627-636.
16. Kundra P, Mishra SK, Ramesh A (2011) Ultrasound of the airway. *Indian J Anaesth* 55:456-462.
17. Adi O, Chuan TW, Rishya MA (2013) Feasibility study on bedside upper airway ultrasonography compared to waveform capnography for verifying endotracheal tube location after intubation. *Crit Ultrasound J* 5: 7.
18. Abbasi S, Farsi D, Zare MA, Hajimohammadi M, Rezai M, et al. (2015) Direct ultrasound methods: A confirmatory technique for proper endotracheal intubation in the emergency department. *Eur J Emerg Med* 22: 10-16.
19. Muslu B, Sert H, Kaya A, Demircioglu RI, Gozdemir M, et al. (2011) Use of sonography for rapid identification of esophageal and tracheal intubations in adult patients. *J Ultrasound Med* 30: 671-676.
20. Geisser W, Maybauer DM, Wolff H, Pfenninger E, Maybauer MO (2009) Radiological validation of tracheal tube insertion depth in out-of-hospital and in-hospital emergency patients. *Anaesthesia* 64: 973-977.
21. Brown III Calvin A, Walls Ron M (2014) Airway. In: Marx John A, Hockberger Robert S (eds) *Rosen's emergency medicine: concepts and clinical practice* (1st edn), Springer, Philadelphia, Pennsylvania, pp. 3-22.
22. Sim SS, Lien WC, Chou HC, Chong KM, Liu SH, et al. (2012) Ultrasonographic lung sliding sign in confirming proper endotracheal intubation during emergency intubation. *Resuscitation* 83: 307-312.
23. Park SC, Ryu JH, Yeom SR, Jeong JW, Cho SJ (2009) Confirmation of endotracheal intubation by combined ultrasonographic methods in the emergency department. *Emerg Med Australas* 21: 293-297.
24. Álvarez-Díaz N, Amador-García I, Fuentes-Hernández M, Dorta-Guerra R (2015) Comparison between transthoracic lung ultrasound and a clinical method in confirming the position of double-lumen tube in thoracic anaesthesia. A pilot study. *Rev Esp Anesthesiol Reanim* 62: 305-312.
25. Sustic A, Protic A, Cicvaric T, Zupan Z (2010) The addition of a brief ultrasound examination to clinical assessment increases the ability to confirm placement of double-lumen endotracheal tubes. *J Clin Anesth* 22: 246-249.
26. Parab SY, Divatia JV, Chogle A (2015) A prospective comparative study to evaluate the utility of lung ultrasonography to improve the accuracy of traditional clinical methods to confirm position of left sided double lumen tube in elective thoracic surgeries. *Indian J Anaesth* 59: 476-481.
27. Pfeiffer P, Rudolph SS, Børglum J, Isbye DL (2011) Temporal comparison of ultrasound vs. auscultation and capnography in verification of endotracheal tube placement. *Acta Anaesthesiol Scand* 55: 1190-1115.