

Use of Negative Pressure Wound Therapy in Healing Below Knee Amputation in Patients with Chronic Venous Insufficiency and/or Charcot Disease

Brandon J Sumpio¹, Alfredo D Cordova¹, David Mahler² and Bauer E Sumpio^{2*}

¹Department of Surgery, Johns Hopkins University School of Medicine, Baltimore, USA

²Department of Vascular Surgery, Yale University School of Medicine, New Haven, USA

Abstract

Below-the-knee amputations in patients who have swollen lower extremities due to chronic venous insufficiency or Charcot disease are particularly vexing clinical problems. The purpose of this paper is to illustrate the role of Negative Pressure Wound Therapy (NPWT) in difficult Below Knee Amputation (BKA) stump closure.

Keywords: Below knee amputation; Peripheral vascular disease; Negative pressure wound therapy; Vascularity

Introduction

One of the oldest known surgical procedures [1,2], lower extremity amputation is still commonly performed, even in hospitals with aggressive revascularization programs for limb salvage. It is unavoidable in many cases of uncontrollable soft-tissue or bone infection, non-reconstructable arterial disease with persistent tissue loss, or unrelenting rest pain due to muscle ischemia.

Despite advances in technology and surgical and endovascular techniques, the number of amputations in the US is rising due to the increased incidence of diabetes and Peripheral Vascular Disease (PVD) in an aging population. In 2005 an estimated 1.6 million individuals were living with the loss of a limb; by the year 2050, it is estimated this number will more than double to 3.6 million [3].

Healing of postoperative below-the-knee wounds has always been a challenge, particularly in cases of compromised circulation. Reported primary healing rates for below-the-knee amputations vary widely, from 30% to 92%, with a re-amputation rate of up to 30% [1,4]. One study concerning lower limb amputation found that the most common residual limb related complications were wound infection and poor healing (70%), poorly fashioned stumps (20%) and phantom pain (10%) [5]. The effects of previous surgery, altered anatomy, muscle and bone atrophy and aerobic deconditioning are important variables in predicting the success of amputation surgery. Improvements in amputation surgical technique and surgical decision-making have resulted in fewer complications and better rehabilitation, but the optimal postsurgical dressing management system continues to be debated. In particular, there are a small but not insignificant proportion of patients who have concomitant chronic venous insufficiency and these extremities carry the additional burden of edematous subcutaneous tissues which impair stump healing. Likewise, the prevalence of Charcot disease has been documented from as low as 0.16% to as high as 29% in diabetic patients [6]. The characteristic edema and hypervascularity, that are characteristic in these patients, unfortunately also presents a challenge when they undergo lower extremity amputation.

In general when faced with the decision of a below-knee-amputation for an individual with large extremities due to chronic venous insufficiency and/or Charcot, negative pressure wound therapy (NPWT) can be a viable option to increase healing potential.

Methods

When considering a below-the-knee amputation in patients with satisfactory arterial perfusion but with moderate to severe swelling of the effected limb, then the use of vacuum therapy in the postsurgical dressing becomes a viable option.

Under general or epidural anesthesia, the below knee amputation is usually performed utilizing a posterior flap incision. The flap is well irrigated with antibiotic and normal saline solution. A large Jackson-Pratt drain or its equivalent is placed into the lateral aspect of the wound through a separate stab wound and the fascia is then closed using interrupted 2-0 Vicryl sutures. The subcutaneous wound is then irrigated with sterile normal saline with a pulse irrigation system to ensure removal of all contaminants, and local hemostasis is then achieved.

With the fascia closed, the skin is left open and the vacuum dressing is applied to the subcutaneous tissue over the closed fascia (Figure 1). The reticulated foam is trimmed so that it fits on the open wound and does not lie on the skin. An adhesive polyurethane drape is then placed over the foam dressing. A 1.5 cm diameter opening is cut in the adhesive drape and centered over the polyurethane foam. Atrac-pad connector is positioned over the drape opening with care taken so that the suction center of the connector does not touch the skin. A rigid prosthetic dressing is fitted over the entire dressing to protect the stump and to immobilize the knee in extension. Vacuum is then started to the desired pressure (recommended 125 mmHg). The dressing is changed every 48-72 hours, and the wound bed assessed. NPWT is usually continued until 90% granulation of tissue at the wound base has been achieved. Conventional dressings are then used until closure via secondary intention has been achieved.

***Corresponding author:** Bauer E Sumpio, Department of Vascular Surgery, Yale University School of Medicine, 333 Cedar St, New Haven, CT 06520-8062, USA, E-mail: bauer.sumpio@yale.edu

Received July 15, 2013; **Accepted** August 27, 2013; **Published** August 30, 2013

Citation: Sumpio BJ, Cordova AD, Mahler D, Sumpio BE (2013) Use of Negative Pressure Wound Therapy in Healing Below Knee Amputation in Patients with Chronic Venous Insufficiency and/or Charcot Disease. Angiol 1: 112. doi: 10.4172/2329-9495.1000112

Copyright: © 2013 Sumpio BJ, et al. This is an open-access article distributed under the terms of the Creative Commons Attribution License, which permits unrestricted use, distribution, and reproduction in any medium, provided the original author and source are credited.

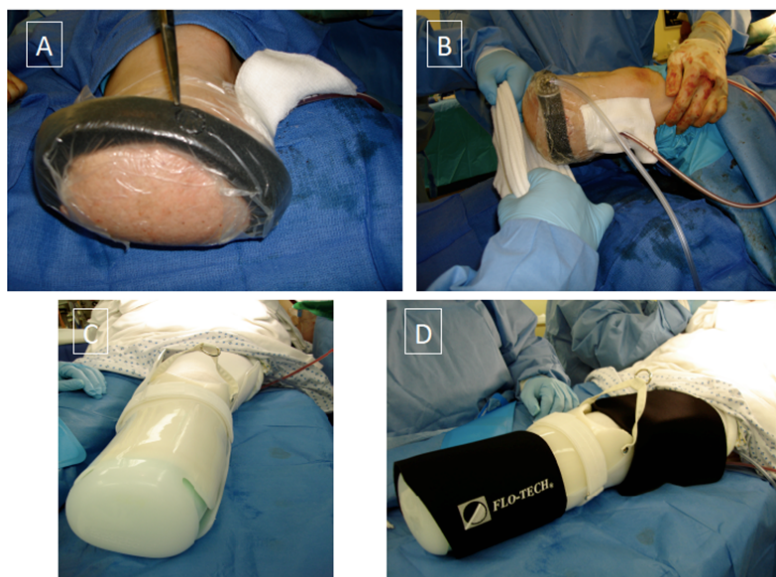


Figure 1: A patient with moderate chronic venous insufficiency that underwent below-knee amputation for non-salvageable foot ischemia. The vacuum dressing is applied to the stump wound with the black foam cut so that it fits on the area of the wound and not on the skin and the adhesive polyurethane drape placed over the foam (Figure 1A). A 1.5 cm diameter opening is cut on the adhesive drape centered over the polyurethane foam and atrac-pad connector inserted (Figure 1B). A rigid, protective dressing is then placed over the stump and secured (Figure 1C and 1D).

Results and Discussion

Prior to the 1960's, above-knee amputations were the most commonly performed lower extremity amputation for vascular disease. The proportion of below-knee amputations increased in the late 1960's and early 1970's because of a number of advancements. Incorporation of a posterior flap technique performed with a better vascular supply led to an improved healing rate of below knee amputations [1]. Clinicians were also beginning to determine the appropriate amputation level based on assessment of perfusion utilizing Doppler evaluation and measurement of transcutaneous PO₂ [7-9]. At the same time, revascularization techniques were being developed that resulted in salvage of threatened limbs or allowed a more distal level of amputation. Increased awareness of the benefits of distal amputation, relating decreased energy expenditure [1,10] and improved rehabilitation potential [11], promoted the trend toward more distal amputations. Other significant developments during this period include advances in the care of the diabetic amputee, and improved understanding of nutrition in stump healing [12].

The presence of large amounts of fluid in the subcutaneous tissues or hypervascularity from Charcot disease is a significant hindrance to the timely healing of the stump wound. In our experience, closure can be achieved in patients with moderate to severe swelling of the extremity with the use of NPWT. We did not opt for delayed sutured closure in the majority of the cases because after a relatively short duration of NPWT the wound becomes sufficiently granulated and contracted to avoid further surgical intervention. Although it's impossible to determine the exact mechanisms of action of our approach utilizing NPWT, we propose several contributing factors. Patients with arterial insufficiency who are already at risk for delayed wound healing, and have large legs due to venous congestion, the dynamic nature of the NPWT dressing system may play an important role by distributing equal pressure across the wound and constantly evacuating excess interstitial fluid. Since the majority of amputations are carried out because of ischemia, this patient population is particularly susceptible to the development

of tissue necrosis due to poor tissue perfusion. Unevenly distributed or excessive pressure from conventional dressings, when used in large edematous legs, can lead to further limb strangulation or tissue necrosis. Furthermore, if not evacuated, postoperative local accumulation of blood can distend the tissues enough to compromise local vascularity, cause pain, and form a nidus for infection. NPWT causes a decrease in soft tissue swelling, encourages essential inflow and outflow, and allows transport of oxygen and nutrition to the wound bed while clearing inhibitory factors [10-12]. The uniform mechanical stress applied to the wound has also been hypothesized to result in positive growth factor production needed during wound healing, and may stimulate proliferation of generative cells and granulation tissue formation to condition the wound for successful closure [13,14]. NPWT can also facilitate easier and less frequent dressing changes, which reduces pain and anxiety.

In the field of prosthetic technology major advances have had a major impact on surgical decision making and technique regarding lower extremity amputation level. There are major distinctions between above knee amputations and below knee amputations, including rates of healing and rehabilitation potential [1]. There is often a fine balance or compromise between increased rates of healing in above knee amputations versus more optimal rehabilitation results and better energy efficiency from below knee amputations. Of the patients who attained a healed residuum, approximately 80% of those with below knee amputation were eventually able to achieve ambulation. This is in contrast to only 38% to 50% of healed above knee amputation patients achieving regular prosthetic ambulation [13,14]. In addition the relative energy costs of ambulation above that of normal energy expenditure of an above knee amputation is 63% compared to that of a below knee amputation is 42% [1]. The maximum aerobic capacity and walking velocity are higher for patients with a below knee amputation than for those with an above knee amputation [15].

Although multiple factors are deserving of consideration when a limb amputation becomes necessary, preservation of the knee,

whenever possible, has a significant effect on a patient's future mobility and quality of life. While we have good clinical outcomes in a small number of patients, a more structured, controlled trial with a large group of patients still needs to be performed.

References

1. Tang PC, Ravji K, Key JJ, Mahler DB, Blume PA, et al. (2008) Let them walk! Current prosthesis options for leg and foot amputees. *J Am Coll Surg* 206: 548-560.
2. Murdoch G (1996) Principles of amputation. In: *Amputation: Surgical Practice and Patient Management*, Butterworth Heinemann Medical, Oxford, UK 7-13.
3. Ziegler-Graham K, MacKenzie EJ, Ephraim PL, Travison TG, Brookmeyer R (2008) Estimating the prevalence of limb loss in the United States: 2005 to 2050. *Arch Phys Med Rehabil* 89: 422-429.
4. Dormandy J, Heeck L, Vig S (1999) Major amputations: clinical patterns and predictors. *Semin Vasc Surg* 12: 154-161.
5. White SA, Thompson MM, Zickerman AM, Broomhead P, Critchley P, et al. (1997) Lower limb amputation and grade of surgeon. *Br J Surg* 84: 509-511.
6. Lee L, Blume PA, Sumpio B (2003) Charcot joint disease in diabetes mellitus. *Ann Vasc Surg* 17: 571-580.
7. Barnes RW, Shanik GD, Slaymaker EE (1976) An index of healing in below knee amputations. Leg blood pressure by Doppler ultrasound. *Surgery* 79:13-20.
8. Burgess EM, Matsen FA 3rd, Wyss CR, Simmons CW (1982) Segmental transcutaneous measurements of PO₂ in patients requiring below-the-knee amputation for peripheral vascular insufficiency. *J Bone Joint Surg Am* 64: 378-382.
9. Collins KA, Sumpio BE (2000) Vascular Assessment. In: *Clinics in Podiatric Medicine and Surgery*, Blume P (edn), W. B. Saunders, Philadelphia, PA, USA.
10. Pinzur MS, Gold J, Schwartz D, Gross N (1992) Energy demands for walking in dysvascular amputees as related to the level of amputation. *Orthopedics* 15: 1033-1036.
11. Fletcher DD, Andrews KL, Butters MA, Jacobsen SJ, Rowland CM, et al. (2001) Rehabilitation of the geriatric vascular amputee patient: a population-based study. *Arch Phys Med Rehabil* 82: 776-779.
12. Moore TJ, Barron J, Hutchinson F 3rd, Golden C, Ellis C, et al. (1989) Prosthetic usage following major lower extremity amputation. *Clin Orthop Relat Res* 219-224.
13. Francis W, Renton CJ (1987) Mobility after major limb amputation for arterial occlusive disease. *Prosthet Orthot Int* 11: 85-89.
14. Robinson K (1980) Amputation in vascular disease. *Ann R Coll Surg Engl* 62: 87-91.
15. Waters RL, Perry J, Antonelli D, Hislop H (1976) Energy cost of walking of amputees: the influence of level of amputation. *J Bone Joint Surg Am* 58: 42-46.