

## Use of Intravitreal Dexamethasone Implant (Ozurdex) Prior to Cataract Surgery in Uveitic Patients

Nur Azem<sup>1\*</sup>, Raz Gepstein<sup>2</sup> and Shiri Shulman<sup>1</sup>

<sup>1</sup>Ophthalmology Division, Tel Aviv Sourasky Medical Center, Tel Aviv University, Tel-Aviv, Israel

<sup>2</sup>Ophthalmology Department, Meir Medical Center, Kfar-saba, Israel

\*Corresponding author: Nur Azem, Department of Ophthalmology, Tel Aviv Medical Center, 6 Weizman Street, Tel Aviv 64239, Israel, Tel: +972-3-6973408; Fax: +972-3-6973867; E-mail: [nurazem4@gmail.com](mailto:nurazem4@gmail.com)

Received date: August 26, 2017; Accepted date: September 19, 2017; Published date: September 25, 2017

Copyright: ©2017 Azem N, et al. This is an open-access article distributed under the terms of the Creative Commons Attribution License, which permits unrestricted use, distribution, and reproduction in any medium, provided the original author and source are credited.

### Abstract

**Purpose:** To report the effect of preoperative use of Ozurdex implant, as a prophylactic treatment to cataract surgery in 5 patients with chronic uveitis.

**Methods:** A retrospective case reports.

**Results:** 5 patients with chronic uveitis were included in this study. All patients were treated with Ozurdex prior to cataract surgery. Patients showed significant improvement in visual acuity one month post-surgery and no recurrence of uveitis up to three months post-surgery. Only two patients showed recurrence of CME 3-4 months post Ozurdex injection, which is attributed to Ozurdex maximal effect as was shown in previous studies.

**Conclusions:** Intravitreal Ozurdex may serve as a perioperative anti-inflammatory treatment for uveitic patients undergoing cataract surgery.

**Keywords:** Ozurdex; Uveitis; Cataract surgery; Prophylaxis

### Introduction

Cataract is a common complication of uveitis. It is caused either by the inflammation itself, by the use of corticosteroid medications or by the combination of both [1,2].

Cataract surgery among uveitic patients is associated with various complications. Macular edema is the major cause of reduced postoperative vision encountered following surgery in uveitic patients, and it commonly occurs within the first postoperative weeks, with an incidence ranging from 18 to 56% [3]. It has been diagnosed in almost half of the eyes that underwent cataract surgery and is responsible for 80% of the eyes with less than 20/40 vision [4-9].

It has been reported that patients in which uveitis was quiet or mostly quiet for the 2 to 3 months preceding cataract surgery had good visual acuity outcomes compared with those in which uveitis was active. This was true for different surgical approaches and different subtypes of uveitis [10,11].

In eyes which are at risk of developing macular edema postoperatively, such as eyes with chronic anterior uveitis, eyes with previous episodes of CME and eyes with intermediate or posterior uveitis, steroid prophylaxis should be given perioperatively to protect

against recurrence of macular edema. Prophylactic treatment given peri-operatively may include oral steroids (1 mg/kg), starting 3 days preoperatively followed by tapering down of the dose, an orbital floor or sub-tenon's injection of depot steroid, such as triamcinolone acetonide (40 mg/1mL) and topical prednisolone acetate 1%, administered 2-3 days prior to surgery [7].

An intravitreal implant containing 700 mg dexamethasone (Ozurdex, Allergan, Irvine, California) has been approved by the U.S. Food and Drug Administration (FDA) for treatment of noninfectious uveitis as well as of macular edema in retinal vein occlusions and diabetic macular edema [8,12,13].

Recently, Ozurdex has been reported as a prophylactic perioperative treatment for patients with chronic uveitis [9,14]. We report five uveitic patients, with mean age 56.4 year, in which Ozurdex was successfully used as a prophylactic treatment prior to cataract surgery, with follow up of 1-12 months. We report the results up to 3 months post operation.

### Case Reports

We'll elaborate on each case while the Tables 1 and 2 are a summary of clinical features and follow up.

PT No.	Gender	Age years	Diagnosis	Treatment	Pre op VA	Operation	Post op Tx.
--------	--------	-----------	-----------	-----------	-----------	-----------	-------------

1	F	66	Anterior and intermediate uveitis d/t sarcoidosis Characterized with high IOP, CME development and epi-retinal membrane formation (ERM)	Actemra Methotrexate 10mg/d Pred forte X2/d Cosopt X2/d	1/12 PH 6/30	LE phaco+synechiolysis+PCIOL 01.2014	1% prednisolone acetate X6/d and ofloxacinone X6/d, with progressive tapering nepafenac X 3/d for a month dorzolamide hydrochloride-timolol maleate X2/d
2	M	44	Idiopathic intermediate uveitis without CME	Pred forte X2/d	6/20 PH NC	LE phaco+PCIOL+OCCI 05.2014	1% prednisolone acetate X6/d and ofloxacinone X6/d, with progressive tapering nepafenac X 3/d for a month
3	F	42	Idiopathic anterior +intermediate uveitis without CME	Prednisone 5 mg/d Cellcept 2 gr/d	6/30 PH 6/20	LE phaco+PCIOL 03.2016	1% prednisolone acetate X6/d and ofloxacinone X6/d, with progressive tapering
4	F	57	Birdshot chorioretinopathy	Remicade	6/30 PH 6/10--	LE phaco+PCIOL 02.2016	1% prednisolone acetate X6/d and ofloxacinone X6/d, with progressive tapering down
5	F	73	Anterior and intermediate uveitis d/t sarcoidosis	Without treatment	6/30	RE phaco+PCIOL 06.2014	1% prednisolone acetate X6/d and ofloxacinone X6/d, with progressive tapering

**Table 1:** Clinical features and follow up.

Pt no	Complications	Final Post op VA	Macular thickness before	Inflammation before	Macular thickness After 1 month	Macular thickness After 3 months	Inflammation after 3 months
1	PCO transient IOP elevation	6/8.5	420 microns	Haze +	406 microns	405 microns	Haze +
2	PCO	42892	310 microns	Haze +	306 microns	300 microns	Haze +
3	HypHEMA	42892	312 microns	Haze +	302 microns	316	None
4	CME 3 months post Ozurdex	42898	229 microns	None	306 microns	221 microns	None
5	CME 4 months post Ozurdex	42916	374 microns	Haze +	313 microns	528 microns	None

**Table 2:** Clinical complications.

### Case 1

A 66 year old female, with a medical history of hypothyroidism and rheumatic arthritis, was on follow up since 2011 due to anterior and intermediate uveitis which was characterized with high IOP, CME development and epi-retinal membrane formation (ERM).

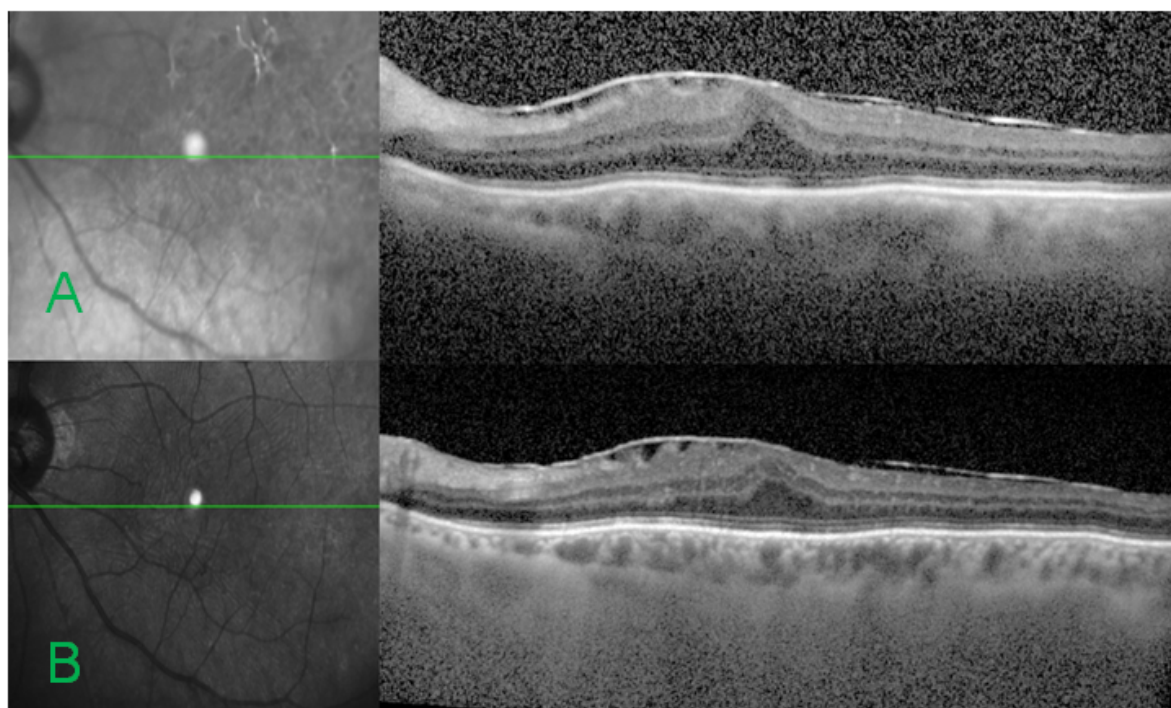
The patient was previously treated with various anti TNF agents for her joint disease, the last being Certolizumab which was ceased in 2012 due to deterioration of the uveitis. She was treated with topical 1% prednisolone acetate and dorzolamide hydrochloride-timolol maleate twice daily in both eyes.

She also underwent two periocular triamcinolone injections in both eyes due to vitritis and CME. During her follow up cortical and posterior sub-capsular cataract developed in the left eye (LE) with deterioration of VA. On ophthalmological examination of the LE her BCVA was 6/30 and IOP measured 20 mmHg. Slit-lamp biomicroscopy revealed a clear cornea, clear anterior chamber, posterior synechiae and moderate nuclear cataract with diffuse

posterior sub-capsular cataract. Posterior segment demonstrated few cells and minimal haze (+0.5) with ERM and mild macular thickening. Optical coherence tomography (Figure 1) demonstrated an ERM with mild CME with central macular thickness (CMT) of 420 microns.

Due to VA deterioration that was attributed to cataract the patient was referred to cataract removal and synechiolysis surgery. One month prior the surgery she underwent an Ozurdex implantation. During the operation posterior capsule opacification was seen, the surgery was uneventful with PCIOL implantation.

One day after the operation her VA was 6/120, IOP measured 22 mm Hg, with significant fibrinous anterior uveitis. Postoperative treatment included 1% prednisolone acetate drops starting from one drop 6 times daily, with progressive tapering to twice daily, nepafenac one drop 3 times daily for a month, topical ofloxacinone drop 6 times daily, with progressive tapering and dorzolamide hydrochloride-timolol maleate 1 drop twice daily.



**Figure 1:** Macular OCT of patient 2 months prior (A) and one month post (B) cataract surgery. ERM is evident without postoperative macular edema.

One month after the surgery anterior chamber examination showed no signs of active inflammation and few cells and minimal haze in the vitreous examination. Due to posterior capsule opacification she underwent an uneventful YAG capsulotomy.

The patient did not suffer any flare-up during the following months. IOP was measured on a monthly basis for 1 year after the initial surgery, during which period no measurement exceeded 14 mm Hg. A year after the initial surgery postoperative BCVA in the LE was 6/8.5. On examination there were no signs of active anterior uveitis with only few vitreous cells and minimal haze (+0.5). Optical coherence tomography (Figure 1) demonstrated an ERM with no signs of CME with CMT of 410 microns.

## Case 2

A 44 year old male was diagnosed with idiopathic chronic anterior and intermediate uveitis on 2008. His VA was preserved at 6/6 and without CME throughout his follow-up. He was treated with topical 1% prednisolone acetate. During the past year posterior sub-capsular cataract developed in the left eye (LE) with deterioration of VA. On ophthalmological examination of the LE, his best-corrected visual acuity (BCVA) was 6/20 and Intraocular pressure (IOP) measured 11 mm Hg. Slit-lamp biomicroscopy revealed a clear cornea, clear anterior chamber without cells and diffuse posterior sub-capsular cataract. Posterior segment examination demonstrated few vitreous cells and minimal haze (+0.5) without CME or retinal lesions.

The patient was referred to cataract surgery and two months prior to that he underwent an Ozurdex implantation. The surgery was uneventful with PCIOL implantation.

Postoperative treatment included 1% prednisolone acetate drops starting from one drop 6 times daily, with progressive tapering to twice daily, nepafenac one drop 3 times daily for a month, topical ofloxacinone drop 6 times daily, with progressive tapering down. On LE examination a day after the operation: VA 6/10. IOP measured 14 mm Hg. Anterior chamber showed +2 cells. One month after the surgery there were no signs of active inflammation with only few cells and minimal haze in the vitreous. Due to posterior capsule opacification he underwent an uneventful YAG capsulotomy. The patient did not suffer any flare-up during the following months.

IOP was measured on a monthly basis for 1 year after the initial surgery, during which period no measurement exceeded 15 mm Hg. Ophthalmological examination 1 year after the surgery showed a BCVA of 6/6, a clear anterior chamber, few cells and minimal vitreous haze (+0.5) without CME or other signs of inflammation.

## Case 3

A 42 year old female was diagnosed with chronic anterior and intermediate uveitis on 1996, suspected due to sarcoidosis. Since 2006 her treatment regimen included oral prednisone, Imuran which was substituted to cellcept during follow up and topical Pred forte X2/d in BE.

She also underwent orbital floor kenalog injections due to worsening of uveitis in her LE on 6/2014 and 11/2014 followed by ozurdex implantation on 8/2015. She was treated with topical cosopt due to increase of IOP in the LE post ozurdex implantation. During her follow up posterior sub-capsular cataract developed in the left eye (LE) with deterioration of VA. On ophthalmological examination of

the LE, her best-corrected visual acuity (BCVA) was 6/36 and Intraocular pressure (IOP) measured 17 mmHg. Slit-lamp biomicroscopy revealed a clear cornea, clear anterior chamber without cells, posterior synechiae and diffuse posterior sub-capsular cataract.

Posterior segment examination showed no signs of vitritis, CME or retinal lesions. The patient was referred to cataract surgery and one month prior to that she underwent a second Ozurdex implantation (7 months post her initial implant). The surgery was uneventful with PCIOL implantation.

Postoperative treatment included maxitrol drops starting from one drop 6 times daily, with progressive tapering to twice daily, topical ofloxacinone drop 6 times daily, with progressive tapering down. On LE examination a day after the operation: VA 6/21. IOP measured 27 mm Hg. Anterior chamber showed +3 cells, microhyphema and aniridia in suprio-temporal iris. Upon follow up three months post the surgery her VA was 6/6, there were no signs of active inflammation or hyphema, without vitreal haze or CME. The patient did not suffer any flare-up during the following months. IOP was measured on a monthly basis, during which period no measurement exceeded 15 mm Hg under topical treatment of cosopt.

#### Case 4

A 57 year old female was diagnosed with birdshot chorioretinopathy since 2012. She was treated with cellcept and prednisone. Due to recurrent macular edema she underwent multiple orbital floor kenalog injections in her LE (8/2013, 5,9/2014,3,8,12/2015). And cellcept was substituted to remecade.

During follow up posterior sub-capsular cataract developed in the left eye (LE) with deterioration of VA. On ophthalmological examination of the LE, her best-corrected visual acuity (BCVA) was 6/20 and Intraocular pressure (IOP) measured 14 mmHg. Slit-lamp biomicroscopy revealed a clear cornea, clear anterior chamber without cells and diffuse posterior sub-capsular cataract. Posterior segment examination demonstrated no vitreous cells or haze and without CME or retinal lesions. The patient was referred to cataract surgery and two months prior to that she underwent an Ozurdex implantation. The surgery was uneventful with PCIOL implantation.

Postoperative treatment included maxitrol drops starting from one drop 6 times daily, with progressive tapering to twice daily and topical vigamox 6 times daily, with progressive tapering down. On LE examination a day after the operation: VA 6/12-. IOP measured 12 mm Hg. Anterior chamber showed +2 cells. One month after the surgery there were no signs of active inflammation but showed worsening of CME on OCT exam. Therefore she was referred to another Ozurdex implantation; three months post the initial one with complete resolution of CME.

The patient did not suffer any flare-up during the following months. IOP was measured on a monthly basis, during which period no measurement exceeded 14 mm Hg. Ophthalmological examination 3 months after the surgery showed a BCVA of 6/8.5, a clear anterior chamber, without vitreous haze, CME or other signs of inflammation.

#### Case 5

A 73 year old female was diagnosed with bilateral anterior and intermediate uveitis due to sarcoidosis on 2014. During the follow up posterior sub-capsular and nuclear cataract developed in the right eye (RE) with deterioration of VA. On ophthalmological examination of

the RE, her best-corrected visual acuity (BCVA) was 6/30 and Intraocular pressure (IOP) measured 13 mm Hg. Slit-lamp biomicroscopy revealed a clear cornea, clear anterior chamber without cells and moderate nuclear sclerosis and diffuse posterior sub-capsular cataract. Posterior segment examination demonstrated few vitreous cells without haze and macular ERM without CME or retinal lesions.

The patient was referred to cataract surgery and two months prior to that he underwent an Ozurdex implantation. The surgery was uneventful with PCIOL implantation.

Postoperative treatment included 1% prednisolone acetate drops starting from one drop 6 times daily, with progressive tapering and topical ofloxacinone drop 6 times daily, with progressive tapering down. On RE examination a week after the operation: VA 6/15. IOP measured 15 mmHg. Anterior chamber was clear. One month after the surgery there were no signs of active inflammation with only few cells in the vitreous. The patient did not suffer any flare-up during the following months.

Ophthalmological examination 3 months after the surgery showed a BCVA of 6/30, a clear anterior chamber, without vitreous cells, haze or other signs of inflammation. But OCT showed recurrence of CME, therefore she was referred to another ozurdex injection (6 month post initial injection).

#### Discussion

The current publication included 5 uveitic patients who underwent Ozurdex implantation as prophylactic treatment prior to cataract surgery.

Only three studies were published regarding the use of Ozurdex implant as a mean of prophylactic treatment to cataract surgery among uveitic patients [9,14,15].

Cordero-Coma et al. published a case report of a 6 year old boy with a 4-year history of anterior uveitis associated with JIA, who suffered recurrent relapses and presented with an advanced cataract in his right eye and VA of 20/80. His therapeutic regimen included s.c.adalimumab [14].

Due to risk of developing amblyopia, he was referred to cataract surgery. And an intravitreal dexamethasone implant (Ozurdex) was placed 1 month prior to the uneventful cataract surgery.

The patient did not suffer any flare-up during follow up, IOP which was measured on a monthly basis, didn't exceed 15 mmHg. Ophthalmological examination 10 months after the cataract surgery showed no signs of active inflammation and postoperative BCVA in the RE was 20/25.

The second publication [9], studied the role of intraoperative intravitreal Ozurdex implant in patients of uveitis with cataract undergoing phacoemulsification.

This prospective study included 10 patients who were treated with intraoperative intravitreal Ozurdex implantation compared with 10 patients who were treated with postoperative oral steroids.

There was no statistically significant difference in BCVA between the two groups in the postoperative period. Visual acuity of less than 20/40 was found in only 3 of the 20 patients at the final follow-up visit. Two patients (2 eyes) had an ERM, while the other developed anterior capsular opacification for which the patient underwent surgical capsulotomy and regained good vision (6/9).

The mean IOP remained within the normal range in both the groups with no statistically significant difference; none of the patients in either group had raised IOP at the 6-month follow-up visit.

OCT showed that the CMT was comparable between both groups at the 1-, 3-, and the 6-month follow-up visit. CME occurred in 1 patient in each group and both patients were managed conservatively and kept under observation.

Anterior chamber inflammation decreased progressively in both the groups in a similar pattern. The anterior chamber was quiet in both groups at 3 months. Only one eye in the steroid group developed severe postoperative anterior chamber inflammation with fibrin. The case was managed with intensive topical steroids with complete resolution.

There was no drop in VA, CME or recurrence of uveitis in either group at 1-year follow-up.

The last publication included 17 eyes of 14 noninfectious uveitic patients with CME who underwent phacoemulsification within 4 months of ozurdex implantation.

Ozurdex was shown to prevent the recurrence or worsening of macular edema in uveitic patients with a history of CME who underwent phacoemulsification. The mean CMT decreased in the subset of eyes that received the implant within 4 weeks prior to cataract surgery.

In accordance with these two publications our patients showed promising results using Ozurdex implant as a prophylactic treatment prior to cataract surgery.

Previous studies show the effect of intravitreal ozurdex implant to be 4–6 months duration, in regard to treating noninfectious intermediate and posterior uveitis [16]. Our results demonstrate a shorter window of effectiveness in terms of preventing postsurgical macular edema among two patients. On the other hand, the majority of our patients showed good visual outcomes and excellent postoperative inflammation control over an extended period.

## In Conclusion

These published results imply that Ozurdex implant may be used as an effective and safe alternative for systemic corticosteroid prophylaxis among uveitic patients, thus avoiding the side effects of systemic steroids. Nevertheless, larger scale comparative studies are necessary to reaffirm these findings.

## Acknowledgements

The abstract was presented in the 13th congress of international ocular inflammation society. September 25-27 2015, San Francisco.

## References

1. Biswas J (2012) Cataract Surgery in Uveitis. *Int J Inflamm* 16.
2. Hooper PL, Rao NA, and Smith RE (1990): Cataract extraction in uveitis patients. *Surv Ophthalmol* 35:120-144.
3. Abela-Formanek C, Amon M, Schauersberger J, Schild G, Kolodjaschna J, Barisani-Asenbauer T, et al. (2002) Uveal and capsular biocompatibility of 2 foldable acrylic lenses in patients with uveitis or pseudoexfoliation syndrome. Comparison to a control group. *J Cataract Refract Surg*. 28: 1160-1172.
4. Alió JL, Chipont E, BenEzra D, Fakhry MA; International Ocular Inflammation Society, Study Group of Uveitic Cataract Surgery (2002) Comparative performance of intraocular lenses in eyes with cataract and uveitis. *J Cataract Refract Surg* 28: 2096-2108.
5. Antcliff RJ, Spalton DJ, Stanford MR, Graham EM, ffytche TJ, et al. (2001) Intravitreal triamcinolone for uveitic cystoid macular edema: an optical coherence tomography study. *Ophthalmology* 108:765-72.
6. Ganesh SK, Babu K, Biswas J (2004) Phacoemulsification with intraocular lens implantation in cases of pars planitis. *J Cat Refract Surg* 30: 2072-2076.
7. Heinzl, Becker M (2005) The treatment of uveitic cataract. In: *Essentials in ophthalmology, Cataract and refractive surgery*, pp: 133-151.
8. **Kuppermann BD, Blumenkranz MS, Haller JA, Williams GA, Weinberg DV, et al. (2007) Randomized controlled study of an intravitreal dexamethasone drug delivery system in patients with persistent macular edema. *Arch Ophthalmol* 125: 309-317.**
9. Gupta A, Ram J, Gupta A, Gupta V (2013) Intraoperative Dexamethasone Implant in Uveitis Patients with Cataract Undergoing Phacoemulsification. *Ocul Immunol Inflamm* 21: 462-467.
10. Mehta S, Linton MM, Kempen JH (2014) Outcomes of cataract surgery in patients with uveitis: as systematic review and meta-analysis. *Am J Ophthalmol* 158: 676-692.
11. Mehta S, Kempen JH (2015) Cataract surgery in patients with uveitis. *Int Ophthalmol* 55: 113-133.
12. Haller JA, Kuppermann BD, Blumenkranz MS, Williams GA, Weinberg DV, et al. (2010) Randomized controlled trial of an intravitreal dexamethasone drug delivery system in patients with diabetic macular edema. *Arch Ophthalmol* 128: 289-296.
13. Williams GA, Haller JA, Kuppermann BD, Blumenkranz MS, Weinberg DV, et al. (2009) Dexamethasone posterior drug delivery system in treatment of macular edema resulting from uveitis or Irvine-Gass syndrome. *Am J Ophthalmol* 147: 1048-1105.
14. Cordero-Coma M, Garzo I, Calleja S, Galán E, Franco M, et al. (2013) Preoperative cataract surgery use of an intravitreal dexamethasone implant (Ozurdex) in a patient with juvenile idiopathic arthritis and chronic anterior uveitis. *J AAPOS* 17: 632-634.
15. Laroche MB, Smith J, Dacey MS (2016) Dexamethasone intravitreal implant in the treatment of uveitic macular edema in the perioperative cataract setting: A case series. *Am J Ophthalmol* 166: 149-153.
16. Lowder C, Belfort R, Lightman S, Foster CS, Robinson MR, et al. (2011) Dexamethasone intravitreal implant for noninfectious intermediate or posterior uveitis. *Arch Ophthalmol*: 129: 545-553.