

## Ultrasound Guided Detection of an Aberrant Femoral Nerve in a Pediatric Patient

Debnath Chatterjee\*, Glenn R Merritt, Alan R Bielsky and Christopher L Ciarallo

Children's Hospital Colorado Aurora/University of Colorado School of Medicine, USA

### Abstract

We present a case report of an ultrasound-guided femoral nerve block in a seven-year-old patient with an aberrant femoral nerve. The utilization of ultrasonography enabled the identification and successful blockade of an aberrant femoral nerve within the belly of the iliopsoas muscle. A review of the literature regarding aberrant femoral nerve anatomy is included.

**Keywords:** Femoral nerve block; Ultrasound guided regional nerve block; Aberrant femoral nerve

### Introduction

A femoral nerve block is one of the most commonly performed peripheral nerve blocks in pediatric regional anesthesia. The femoral nerve is typically located lateral to the femoral artery, deep to the fascia iliaca and superficial to the iliopsoas muscle [1]. Utilization of ultrasonography has recently enabled the identification of an anomalous femoral nerve in an adult [2]. We report a case of an aberrant femoral nerve detected during an ultrasound-guided femoral nerve block in a pediatric patient.

### Case Description

A seven-year-old boy presented for an open reduction and internal fixation of his right femur fracture under general anesthesia. An ultrasound guided femoral nerve block was planned for post-operative analgesia. Upon scanning the femoral triangle with a linear high frequency transducer probe (GE Logiq e, 12 MHz frequency); we were unable to identify the femoral nerve in its usual anatomic position lateral to the femoral artery. Further scanning revealed a hyperechoic structure present within the belly of the iliopsoas muscle (Figure 1), along its entire course. Using a nerve stimulator, we elicited a strong quadriceps motor response. We injected 10 ml of 0.2% ropivacaine around this aberrant femoral nerve and a clinically successful block was achieved as evidenced by excellent postoperative analgesia. An ultrasound scan of the non-operative extremity revealed similar anatomy.

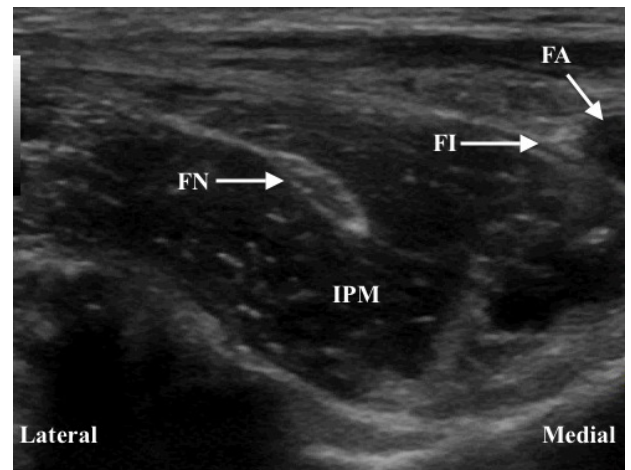
### Discussion

The femoral nerve is the largest branch of the lumbar plexus. It arises from the dorsal branches (posterior divisions) of the second to fourth lumbar ventral rami. It descends through psoas major and emerges on its lateral border to pass between psoas and iliacus. It enters the thigh below the inguinal ligament and lateral to the femoral sheath. In adults, it splits into anterior and posterior divisions in the femoral triangle about 2 cm distal to the inguinal ligament [1].

Anatomic variations of the femoral nerve are not rare. Cadaveric studies have reported anatomic variations of the femoral nerve in up to 35% of cadavers [3]. Most of these variations consisted of bifurcation of the femoral nerve into two or three slips, separated by psoas major muscle fibers before they rejoined prior to the femoral nerve exiting from the pelvic cavity. In another cadaveric study, muscular slips from

iliacus and psoas were found piercing or covering the femoral nerve in 7.9% of the specimens [4]. An anomalous higher branching pattern of the femoral nerve above the inguinal ligament has also been reported [5,6].

A femoral nerve block is frequently classified as a beginner level block because of its superficial location and consistent anatomic relationships. However, the use of ultrasound has allowed us to identify an anatomic variation that may contribute to block failure. The identification of abnormal anatomy and performing a thorough, systematic exam while performing ultrasound guided regional anesthesia, enables the anesthesiologist to alter the block plan and reduce the likelihood of complications [7].



**Figure 1:** Ultrasound image of aberrant femoral nerve within belly of iliopsoas muscle (FN-Femoral nerve, FA-Femoral artery, FI-Fascia iliaca, IPM-Iliopsoas muscle).

\*Corresponding author: Debnath Chatterjee, Children's Hospital Colorado Aurora, USA; E-mail: [debnath.chatterjee@childrenscolorado.org](mailto:debnath.chatterjee@childrenscolorado.org)

Received August 13, 2013; Accepted August 29, 2013; Published August 31, 2013

**Citation:** Chatterjee D, Merritt GR, Bielsky AR, Ciarallo CL (2013) Ultrasound Guided Detection of an Aberrant Femoral Nerve in a Pediatric Patient. J Anesth Clin Res 4: 348. doi:10.4172/2155-6148.1000348

**Copyright:** © 2013 Chatterjee D, et al. This is an open-access article distributed under the terms of the Creative Commons Attribution License, which permits unrestricted use, distribution, and reproduction in any medium, provided the original author and source are credited.

## Summary

We believe our patient had an aberrant femoral nerve located within the belly of the iliopsoas muscle based on the consistent ultrasound anatomy, appropriate quadriceps motor response on electrostimulation, and pattern of successful analgesia. The utilization of ultrasonography enabled the identification of an aberrant femoral nerve and allowed a safe and successful local anesthetic blockade. Clinicians should be aware of this anatomic abnormality, especially when dealing with the difficult or failed femoral nerve block attempt.

## Consent

Written permission was obtained from the patient's mother to publish this manuscript.

## References

1. Standing S (2008) *Gray's anatomy. The anatomical basis of clinical practice.* (40th Edn), Elsevier Churchill Livingstone, Spain, 1382-1383.
2. Chin KJ, Tse C, Chan V (2011) Ultrasonographic identification of an anomalous femoral nerve: the fascia iliaca as a key landmark. *Anesthesiology* 115: 1104.
3. Anloague PA, Huijbregts P (2009) Anatomical variations of the lumbar plexus: a descriptive anatomy study with proposed clinical implications. *J Man Manip Ther* 17: e107-e114.
4. Vázquez MT, Murillo J, Marañillo E, Parkin IG, Sanudo J (2007) Femoral nerve entrapment: a new insight. *Clin Anat* 20: 175-179.
5. Astik RB, Dave UH (2011) Anatomical variations in formation and branching pattern of the femoral nerve in iliac Fossa: A study in 64 human lumbar plexuses. *People's J Scient Res* 4: 14-19.
6. Das S, Vasudeva N (2007) Anomalous higher branching pattern of the femoral nerve: a case report with clinical implications. *Acta Medica (Hradec Kralove)* 50: 245-246.
7. Sites BD, Macfarlane AJR, Sites VR, Naraghi AM, Chan VWS, et al. (2010) Clinical sonopathology for the regional anesthesiologist. Part 1: Vascular and neural. *Reg Anesth Pain Med* 35: 272-280.