

Two Years Follow Up After Iris Claw Intraocular Lens Implantation for Correction of Aphakia

Omar M Said¹, Sarah A Saad¹, Mohamed A Abd El-Hafez¹, Asser A.E Abdel-Magid², Mohammed Iqbal³

¹Department of Ophthalmology, Fayoum University, Fayoum, Egypt

²Department of Ophthalmology, Cairo University, Cairo, Egypt

³Department of Ophthalmology, Sohag University, Sohag, Egypt

*Corresponding author: Omar Mohamed Said, Lecturer of Ophthalmology, Department of Ophthalmology, Faculty of Medicine, Fayoum University, Fayoum, Egypt. Tel: 084 6300587; E-mail: oms01@fayoum.edu.eg

Received date: October 12, 2019; Accepted date: November 20, 2019; Published date: December 03, 2019

Copyright: © 2019 Said OM, et al. This is an open-access article distributed under the terms of the Creative Commons Attribution License, which permits unrestricted use, distribution, and reproduction in any medium, provided the original author and source are credited.

Abstract

Aim: Aphakia with insufficient capsular support is a challenging situation that can be managed by multiple options. The purpose of this study is to evaluate iris claw IOL implantation as one available option as regards visual outcome and complications.

Methods: This was a prospective interventional study that included 26 eyes of aphakic patients with insufficient capsular support diagnosed preoperatively or acquired intraoperatively. Data analyzed included best corrected visual acuity (BCVA), intraocular pressure (IOP), central endothelial cell density (CECD) and anterior chamber angle depth by optical coherence tomography preoperatively and postoperatively for 24 months.

Results: 26 eyes of 17 patients received iris claw IOL implantation for correction of aphakia with insufficient capsular support. Mean age of the patients was 32.8 ± 20.9 , 13 patients (50%) underwent secondary implantation and the other 13 (50%) underwent primary implantation of iris claw IOL. The mean preoperative LogMAR BCVA was 1.11 ± 0.28 improved to 0.63 ± 0.18 at 9 months postoperatively p-value (<0.001). Preoperative IOP was 18.7 ± 4.9 mmHg, postoperative was 15.9 ± 3.5 mmHg. Preoperative CECD was 3337.6 ± 801.9 cell/mm² changed to 2837.4 ± 640.9 cell/mm² at 3 months then to 2676.1 ± 664.4 cell/mm² at 9 months postoperatively p-value (0.03) and then to 2636.6 ± 652.6 cell/mm² at 24 months postoperatively. Preoperative anterior chamber angle depth was 41.1 ± 4.4 and postoperative was 42.8 ± 2.9 .

Conclusion: Iris claw IOL implantation is a safe option in cases of aphakia with insufficient capsular support with significant improvement in final visual acuity and early loss of endothelial cell density.

Keywords: Iris claw IOL; Aphakia; Endothelial cell loss; Central endothelial cell density; Insufficient capsular support

Introduction

Following cataract surgery, best result is achieved with the implantation of an IOL in the capsular bag. However, several conditions can lead to aphakia in eyes with insufficient or absent capsular support. Among others, these include crystalline lens subluxation, IOL dislocation, and capsular loss during cataract extraction for congenital or juvenile cataract, complicated phacoemulsification for senile cataract and trauma [1,2]. The resulting aphakia can be corrected with aphakic spectacles, contact lenses, and implantation of aphakic IOLs [2,3].

Various IOLs, including angle-supported anterior chamber IOLs, scleral fixation posterior chamber intraocular lenses (SF-PCIOL), and, more recently, retropupillary iris-claw IOLs, have been implanted to correct aphakia [4,5].

The tendency in recent years has been to avoid an implantation of angle-supported anterior chamber lenses in these cases, because of long-term endothelial damage and the potential hazard of secondary

glaucoma induction [6,7]. Numerous authors have reported on complications following scleral fixation of a posterior chamber lens [6].

Previous studies have established that iris-claw Artisan IOL implantation is an effective method for the correction of aphakia with several advantages such as having fewer complications, with its easy placement and good visual outcome, when compared with the transscleral sutured IOLs and angle-supported anterior chamber IOLs [6].

Concerning the location of implantation of Artisan IOL, the data have conflicting results. Artisan IOLs could be applied to anterior chamber over the iris or retro-pupillary [8].

Materials and Methods

This study was a prospective cohort interventional study conducted in Fayoum University Hospital between 2015 and 2018 by one surgeon, included 26 eyes of 17 aphakic patients with insufficient capsular support, were corrected by implantation of Artisan Iris Claw Intraocular lens in the anterior chamber.

Patients with uncontrolled glaucoma, insufficient iris support, associated corneal opacities, uveitis, low visual potentials due to

macular, retinal, or optic disc pathologies, anterior chamber depth <3 mm and CECD < 2500 cells/mm³ were excluded.

The current study was approved by the local ethical committee of the faculty of Medicine, Fayoum University, Egypt. Tenets of the Declaration of Helsinki were followed. All patients signed an informed consent explaining the procedure and possible complications.

All patients were evaluated preoperatively for best corrected visual acuity by Snellen chart, Intraocular pressure assessment by Goldman Applanation Tonometry, Slit lamp examination for anterior chamber abnormalities, Dilated fundus examination, Biometry Was done using Carl Zeiss IOL master 700 to calculate IOL power choosing SRK-T formula and A- constant 115.0., Specular microscopy Using non-contact microscope Noncon Robo-P, Konan Medical, Anterior Segment OCT to assess anterior chamber angle before implantation for presence of synechia and anterior chamber angle measurement using RTvue XR- Optovue Inc.

Surgery was done under general or local anesthesia, After instillation of anesthetic eye drop, 5% povidone iodine was instilled before starting surgery, A 5.5 mm clear corneal incision was done and then 2 paracentesis opening at 10 and 2 o'clock, Intracameral pilocarpine was used to constrict the pupil, Sodium hyaluronate was injected intracameral, Introducing the iris claw IOL into the anterior chamber through main corneal incision then it was dialed to be placed horizontally over the pupil and centered. The IOL was held with the IOL forceps, and then through the paracentesis the enclavation needle was used to fixate the IOL to the iris. A peripheral iridectomy was performed using vitrectomy probe at 12 o'clock. The corneal wound was closed using 10/0 nylon sutures that was removed 6 weeks later then Sodium hyaluronate was washed from the anterior chamber using irrigation aspiration cannula. Subconjunctival injection of dexamethasone and garamycin at the end of the surgery.

For patients underwent lensectomy with primary iris claw; the lensectomy was performed to remove the subluxated lens with vitrectomy cutter through anterior approach or by irrigation aspiration, intracameral miotics and then iris claw as the secondary implantation.

All patients were followed at 1 day, 1week, 1 month, 3 months, 6 months, 9 months and 24 months. Examination included UCVA and BCVA with Snellen chart that was converted to logMAR for statistical purposes, Slit lamp examination for; anterior chamber reaction and pigment deposition and IOP measurement by Goldman Applanation Tonometry, Dilated fundus examination, Specular microscopy at 3, 9, 24 months and AC angle assessment by OCT at 9 months.

Statistical Analysis

Data were collected and coded to facilitate data manipulation and double entered into Microsoft Access and data analysis was performed using SPSS software version 18 in windows 7.

Simple descriptive analysis in the form of numbers and percentages for qualitative data, and arithmetic means as central tendency measurement, standard deviations as measure of dispersion for quantitative parametric data, and inferential statistic test:

For quantitative non parametric data

kruskalwallis test used in comparing more than two independent groups.

Mann-whitney test in comparing two independent groups.

The P-value ≤ 0.05 was considered the cut-off value for significance.

Results

Our study was a prospective cohort interventional study included 26 eyes of 17 patients, 5 females and 12 males. 13 of them had secondary implantation of anterior chamber iris claw (secondary aphakia) and the other 13 eyes anterior chamber iris claw implantation was in the same session of lens extraction (primary aphakia).

The mean age in the study group was (32.8 \pm 20.9) years ranged between 11 years old and 62 years old. The study group included 13 eyes with secondary aphakia and the other 13 were primary subluxated lenses: 3 of them microspherophakia, 3 congenital subluxation and 7 traumatic subluxation. Figures 3 and 4 show the pre and postoperative appearance of a patient with microspherophakia.

Statistical analysis of BSCVA revealed the mean preoperative BSCVA was (1.11) \pm (0.28) logMAR. At first week postoperative BSCVA were (0.63) \pm (0.18) logMAR indicating highly significant improvement of BSCVA p-value(<0.001) and then values were stable as the change was non-significant over the next follow up visits as shown in Figure 1.

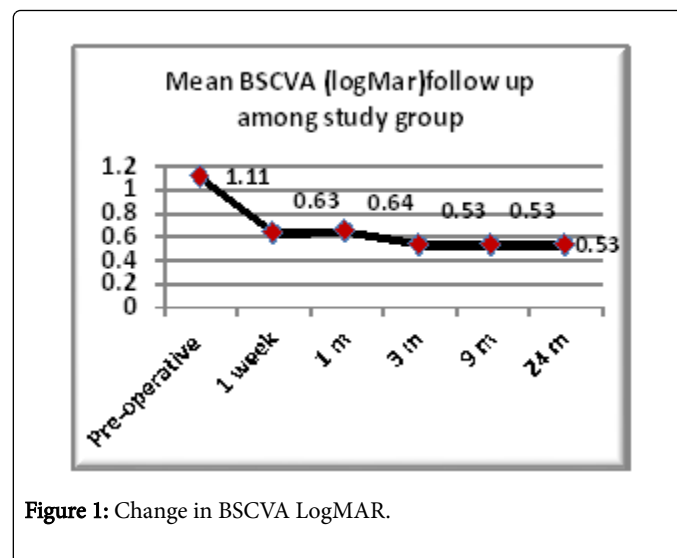


Figure 1: Change in BSCVA LogMAR.

IOP measurement was not changed significantly throughout the follow up period.

The mean endothelial cell count preoperative was (3337.6) \pm (801.9). In the first follow up visit at 3 months mean ECC (2837.4) \pm (640.9) showing non-significant reduction p-value (0.15). Then to 2676.1 \pm 664.4 cell/mm² at 9 months postoperatively p-value (0.03) and then to 2636.6 \pm 652.6 cell/mm² at 24 months postoperatively.

There were a significant decrease between preoperative mean ECC and the 9 months follow-up visits with p-value (0.03). There were a non-significant decrease between the first and the second follow up visits with p-value (0.9) and a non-significant decrease between the second and the third follow up visits with p-value (0.4) as illustrated by Figure 2.

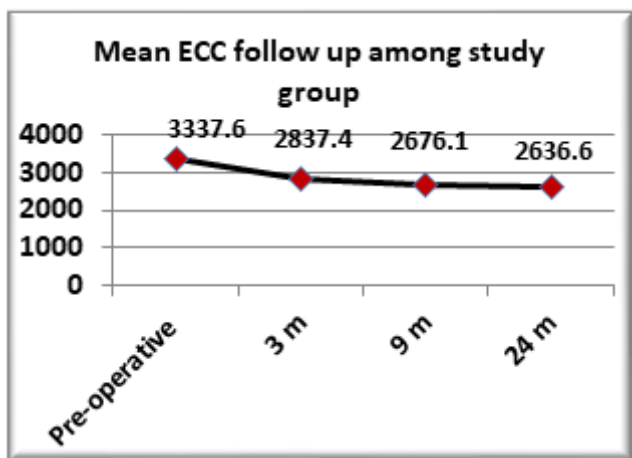


Figure 2: illustrates ECC change in the study group.

Our study showed that there is a non-significant change in the anterior chamber angle as assessed by optical coherence tomography (OCT) pre and postoperative as shown in Table (1).

Follow up	OCT		p-value	Sig.
	Mean	SD		
Pre-operative	41.10	4.40	0.24a	NS
9 months post-op.	42.80	2.90		

Table 1: Illustrates the change in anterior chamber angle.

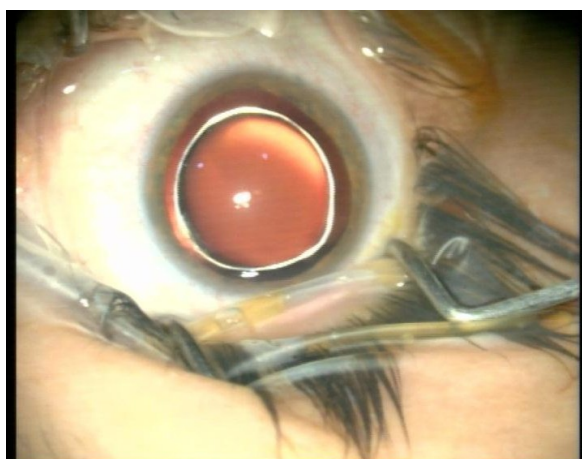

Figure 3: A case of microspherophakia.

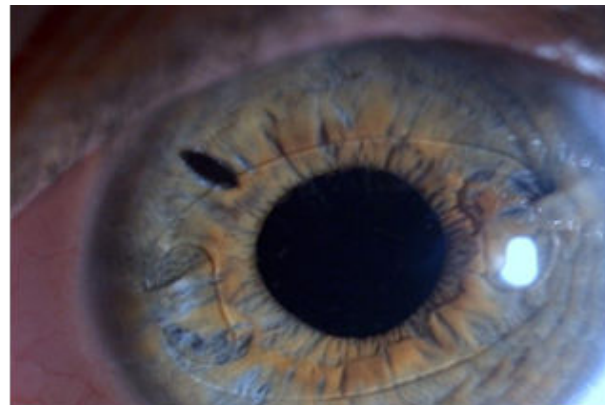

Figure 4: 2 years postoperative picture.

As regards post-operative complication there were 2 eyes presented with mild anterior uveitis that improved on topical steroids after one week, 2 eyes with pigmented deposits on lens surface, and 2 eyes, 2 eyes had ovalization of the pupil and one case of cystoid macular edema.

Also we found that one patient had mild lens decentration but no case had slipped or dropped IOL.

Discussion

Artisan aphakia lenses have been successfully implanted in the anterior chamber and fixated to the anterior surface of the iris in aphakic eyes that had undergone lensectomy [4]. Retropupillary implantation of the Artisan iris-claw lens after lensectomy has also been reported [9].

Our results showed significant improvement in BCVA postoperatively as compared to preoperative measures. This improvement was noticed in the first week postoperative and then remained almost stable throughout the follow up visits.

IOP was not significantly affected in our cases comparing pre and postoperative values.

A major concern about using the iris claw lenses in the anterior chamber is the long term effect on endothelial cell count due to its proximity to the corneal endothelium. Our study showed that there is significant decrease with p-value (0.03) between preoperative values that was $(3337.6) \pm (801.9)$ and at 9 months visit values was $(2676.1) \pm (664.4)$. Most of this decrease is probably attributed to the post-operative period. As there was a non-significant decrease between preoperative and at 3months visit with a p-value (0.15) and between 3 and 9 months readings with a p-value (0.9), and between 9 and 24 months readings with a p-value (0.4) denoting more stability in the corneal endothelial cells on consecutive visits and that means that most of endothelial cell count decrease was attributed to the surgical procedure not to the presence of the IOL.

Our study agree with the recent study by Catala-Mora et al, which revealed favorable results with using the iris claw IOL in the anterior chamber. This study was performed in a pediatric cohort and concluded that; in 21 eyes of 12 patients with non-traumatic ectopia lentis the mean follow-up was 39.3 ± 13.0 months. BSCVA

(mean \pm SD) improved from 0.91 ± 0.29 logMar preoperatively to 0.18 ± 0.23 logMar at final follow-up ($p < 0.0001$). Postsurgically, CECC loss was $5.04\% \pm 9.58\%$ with an annual CECC loss rate of $3.16\% \pm 4.46\%$ [10].

In 2016 Faria et al, conducted a study included 66 eyes with aphakia due to posterior dislocation of the lens who underwent iris claw lens implantation found that the mean preoperative best corrected logMAR visual acuity was 1.260 ± 0.771 . The mean age of the patients was 66.26 ± 21.8 years (range, 22-84 years). The mean follow-up period was 23 months (range, 6-48 months). At the end of the follow-up period, the mean postoperative best corrected logMAR visual acuity was 0.351 ± 0.400 . In this study, elevated IOP was observed in twelve cases, and all were medically managed. Peripheral iridectomies were not performed, and no cases of pupillary block occurred [11].

Our results were also comparable to the study performed by Gawdat et al, 2015 on anterior chamber artisan iris claw lens in aphakia which was done on pediatric age group, the study showed the mean preoperative logMAR best-corrected visual acuity for traumatic aphakic patients was 0.95 ± 0.36 ; for patients with subluxation, 0.7 ± 0.26 . Values improved at 1 year to 0.38 ± 0.15 ($P < 0.002$) and 0.3 ± 0.2 ($P < 0.0001$), respectively. As regards ECC, The mean preoperative CECD was 3573 ± 468 cells/mm², which decreased significantly by the 12 months' follow-up to 2892 ± 441 cells/mm² ($P < 0.0001$), with a mean CECD loss of 19%. There was a significant reduction ($P < 0.02$) in the 12-month postoperative CECD compared to CECD at 1 month after surgery (3081 ± 495 cells/mm²), with a mean CECD loss of 6.1%. Regarding intraocular pressure (IOP) changes, there were no significant differences in the IOP measurements throughout the study [12].

Some studies reported higher incidence of endothelial cell loss with the iris claw IOL implanted in the anterior chamber than the retropupillary approach as Gicquel et al. showed a significant difference in the mean endothelial cell loss between 6 months and 1 year after penetrating keratoplasty and ICIOL implantation, comparing a group of eyes that underwent implantation of iris claw lenses in the AC (on the iris) and another group that underwent retropupillary implantation (19% vs 3.7%) [13]. Although the sample size was small (27 eyes) and the results of the study were limited, this difference appeared to favor retropupillary implantation compared with fixation on the anterior face of the iris regarding changes in the corneal endothelium [14].

In the context of endothelial cell loss, a study performed by Teng and Zhang on 45 population divided into 2 groups one of them implanted iris claw lens in the anterior chamber and the other implanted posterior sulcus fixated sclera fixation they found that no statistically significant difference in endothelial cell loss rate was noted between two groups at any time point ($P > 0.05$) [15].

In our study we found that there is no significant statistical difference between the pre and postoperative measures of the anterior chamber angle with p-value 0.24, this result is similar to those found by Koss and Kohnen, 2009 who also compared the anterior chamber depth in the presence of the IOL in the anterior chamber and concluded that the Anterior fixation of iris claw IOL is safe and effective but should be reconsidered in short eyes [16].

Our study and all the previously mentioned studies confirmed the feasibility of inserting the iris claw IOLs and the short surgical time compared to other IOL implantation procedure and the actual surgical

time was estimated by Teng and Zhang to be (11.23 ± 1.54) minutes [15].

As regards complications, in our study there was no significant intraoperative or postoperative complications except for 2 eyes presented with mild anterior uveitis that improved on topical steroids after one week, 2 eyes with pigmented deposits on lens surface, and 2 eyes, 2 eyes had ovalization of the pupil and one case of cystoid macular edema. But other studies mentioned some complications as IOL de-enclavation that was most serious and difficult with the retropupillary approach as reported by Sezer et al, 2016. 17 this was not the case with the anterior fixation approach as reported by Barbra et al, 2016. 18 and Gawdat et al, 2015. 12 both studies have traumatic de-enclavation in one eye.

Conclusion

The anterior fixation of an artisan aphakia iris claw lens is a safe and effective measure in correcting aphakia with insufficient capsular support as regards visual outcome, IOP, ECC, Anterior chamber angle and postoperative complications.

References

- Schallenberg M, Dekowski D, Hahn A, Laube T, Steuhl KP, et al. (2014) Aphakia correction with retropupillary fixated iris-claw lens (Artisan)-long-term results. *Clin Ophthalmol* 8: 137-141.
- Chen Y, Liu Q, Xue C, Huang Z, Chen Y (2012) Three-year follow-up of secondary anterior iris fixation of an aphakic intraocular lens to correct aphakia. *J Cataract Refract Surg* 38: 1595-1601.
- Lambert SR, Buckley EG, Drews-Botsch C, DuBois L, Hartmann E, et al. (2010) The infant aphakia treatment study: Design and clinical measures at enrollment. *Arch Ophthalmol* 128: 21-27.
- Acar N, Kapran Z, Altan T, Kucuksumer Y, Unver YB, et al. (2010) Secondary iris claw intraocular lens implantation for the correction of aphakia after pars plana vitrectomy. *Retina* 30: 131-139.
- Miyata K, Miyai T, Minami K, Bissen-Miyajima H, Maeda N, et al. (2011) Limbal relaxing incisions using a reference point and corneal topography for intraoperative identification of the steepest meridia. *J Refract Surg* 27: 339-344.
- Dick HB, Augustin AJ (2001) Lens implant selection with absence of capsular support. *Curr Opin Ophthalmol* 12: 47-57.
- Hara T, Hara T (2004) Ten-year results of anterior chamber fixation of the posterior chamber intraocular lens. *Arch Ophthalmol* 122: 1112-1116.
- Güell JL, Verdaguer P, Elies D, Gris O, Manero F, et al. (2014) Secondary iris-claw anterior chamber lens implantation in patients with aphakia without capsular support. *Br J Ophthalmol* 98: 658-663.
- Rufer F, Saeger M, Nolle B, Roider J. (2009) Implantation of retropupillary iris claw lenses with and without combined penetrating keratoplasty. *Graefes Arch Clin Exp Ophthalmol* 247: 457-462.
- Català Mora J, Cuadras D, Díaz Cascajosa J, Castany Aregall M, Prat Bartomeu J, et al. (2017) Anterior iris-claw intraocular lens implantation for the management of nontraumatic ectopia lentis: Long-term outcomes in a paediatric cohort. *Acta Ophthalmol* 95: 170-174.
- Faria MY, Ferreira NP, Pinto JM, Sousa DC, Leal I, et al. (2016) Retropupillary iris claw intraocular lens implantation in aphakia for dislocated intraocular lens. *Int Med Case Rep J* 29: 261-265.
- Gawdat GI, Taher SG, Salama MM, Ali AA (2015) Evaluation of artisan aphakic intraocular lens in cases of pediatric aphakia with insufficient capsular support. *J AAPOS* 19: 242-246.
- Gicquel JJ, Guigou S, Bejjani RA, Briat B, Ellies P, et al. (2007) Ultrasound biomicroscopy study of the verisyse aphakic intraocular lens combined with penetrating keratoplasty in pseudophakic bullous keratopathy. *J Cataract Refract Surg* 33: 455-464.

-
14. Gonnermann J, Amiri S, Klamann M, et al. (2014) Endothelial cell loss after retropupillary iris-claw intraocular lens implantation. *Klin Monatsblätter für Augenheilkd* 231: 784-787.
 15. Teng H, Zhang H (2014) Comparison of artisan iris-claw intraocular lens implantation and posterior chamber intraocular lens sulcus fixation for aphakic eyes. *Int J Ophthalmol* 7: 283-287.
 16. Koss MJ, Kohnen T (2009) Intraocular architecture of secondary implanted anterior chamber iris-claw lenses in aphakic eyes evaluated with anterior segment optical coherence tomography. *Br J Ophthalmol* 93: 1301-1306.
 17. Sezer H, Demirdüzen S, Öksüz H (2016) Iris-claw intraocular lens implantation: Anterior chamber versus retropupillary implantation. *Indian J Ophthalmol* 64: 45-49.
 18. Barbara R, Rufai SR, Tan N, Self JE (2016) Is an iris claw IOL a good option for correcting surgically induced aphakia in children? A review of the literature and illustrative case study. *Eye* 30: 1155-1159.