

Twin Pregnancy in a Bicornuate Bicervical Uterus Relating to a Case at CHU-MEL in Cotonou Benin and Literature Review

Bagnan JT¹, Obossou AAA², Lokossou MSHS³, Atade R¹, Lokossou A¹ and Perrin RX¹

¹Lagoon University Teaching Hospital for Mother and Child (CHU-MEL), Cotonou, Benin

²Borgou/Alibori Regional University Teaching Hospital (CHUD-B/A), Parakou, Benin

³Oueme/Plateau Regional University Teaching Hospital (CHUD-O/P), Porto Novo, Benin

*Corresponding author: Obossou AAA, Assistant Professor, Faculty of Medicine (Obstetrician-Gynecologist), University of Parakou, Republic of Benin, Tel: (229) 95853279/97067852; E-mail: awadefr2000@yahoo.fr

Received date: January 10, 2017; Accepted date: January 24, 2017; Published date: January 30, 2017

Copyright: © 2017 Bagnan JT, et al. This is an open-access article distributed under the terms of the Creative Commons Attribution License, which permits unrestricted use, distribution, and reproduction in any medium, provided the original author and source are credited.

Abstract

We report a case of twin pregnancy in a malformed uterus incidentally discovered during an emergency caesarean section relating to a primigravida at CHU-MEL in Cotonou. The patient is a 25-year-old woman referred from a neighbourhood center, without particular antecedents, admitted there because of an acute fetal distress at 38 weeks of amenorrhea +1 day. The objective examination presents two hemi-vaginas and two hemi-cervixes. The Acute fetal distress diagnosis is confirmed. By means of a caesarean section on 10th June 2016, two male twins have been removed by the cephalic pole from a bicornuate bicervical uterus, J2 being mature and weighing 2700 g and J1 the other presenting signs of prematurity and weighing 1200 g. Referred to the neonatal unit, J2 is allowed to leave after 24 hours of hospitalization and J1 after 5 days of hospitalization. Postoperative care has been simple for the mother and the new-born babies are healthy. Both mother and children are allowed to leave the 5th day after operation.

Keywords: Twin pregnancy; Bicornuate bicervical uterus

Introduction

Uterine malformations are relatively frequent since they affect 3 to 4% of the female population [1,2]. Most congenital malformations are detectable at birth; some are diagnosed in the antenatal period and others later at puberty or adulthood. The latter may not be noticed for a long time and are only discovered incidentally during an exploration.

Here, we report the case of a twin pregnancy of different age, in a bicervical, bicornuate uterus, relating to a primigravida referred because of a stationary dilatation at 38 weeks of amenorrhea +1 day in a level 3 maternity hospital.

Study Framework

This is a case of a twin pregnancy in a bicervical bicornuate uterus admitted to the Centre Hospitalier Universitaire de la Mère et de l'Enfant-Lagune (CHU-MEL) [Teaching Hospital for Mothers and Children] in Cotonou in 2016.

Clinical Observation

K.V a 25 years old, working as a nursing assistant, nulliparous, referred to CHU-MEL on June 10th, 2016 because of a stationary dilatation for a twin pregnancy of 38 weeks of amenorrhea +1 day according to the ultrasound of March 26th, 2016 which estimated the pregnancy to be of 27 weeks of amenorrhea +3 days.

The patient interview revealed that it was her first pregnancy. She was offered medical treatment in a neighborhood maternity hospital with 5 antenatal consultations and only one ultrasound carried out at 27 weeks of amenorrhea +3 days. The ultrasound disclosed a

dichorionic diamniotic twin pregnancy. The two fetuses one of which was breeched and the other cephalichad biometric data of 27 weeks of amenorrhea +3 days and 23 weeks of amenorrhea +1 day respectively.

No indication of high blood pressure prior to the pregnancy diagnosed before 20 weeks of amenorrhea was found. The date of the last menstrual period was not specified. Rubella serology and toxoplasmosis one was carried out and was normal.

She was offered a preventive intermittent treatment of malaria and an iron supplementation. Moreover, the pregnant woman had no indication of miscarriage and the other antecedents had no particularities.

When admitted, the female patient complained of lumbo-pelvic pain and headaches. The examination showed a good general condition, and colored palpebral mucous membranes. The temperature was 37.2°C, the blood pressure was 170/110 mmHg and the pulse was 96 bpm.

Proteinuria was positive with 3 crosses, the abdomen was smooth, and the uterus had a big longitudinal axis with a big heart-shaped upper end.

The palpation of the uterus clearly showed two fetuses with a 5 cm space between the fetuses. Two contractions lasting 30-32 seconds were noticed in 10 mins. The fundal height was 38 cm the two fetuses were cephalic at delivery.

The fetal heart sounds were perceived from two spots: 80 heartbeats per minute for J1 and 110 heartbeats for J2.

The vulva was edematous with swelling covering the front 2/3 of the vulvar opening.

The vagina examination showed two openings of the cervix:

- On the right the cervix was thick and two fingers could be put into the two openings, the membranes were ruptured, the presentation was cephalic, mobile and the finger cot brought back meconium-stained amniotic fluid.
- On the left, the cervix was edematous dilated to 8 cm, the membranes were ruptured, the presentation was cephalic, the pelvis was clinically normal and the finger cot brought back meconium-stained amniotic fluid.

In the light of the above information, it was an acute fetal distress relating to a twin pregnancy of 38 weeks of amenorrhea +1 day in a context of severe pre-eclampsia concerning a primigravida (Figure 1).

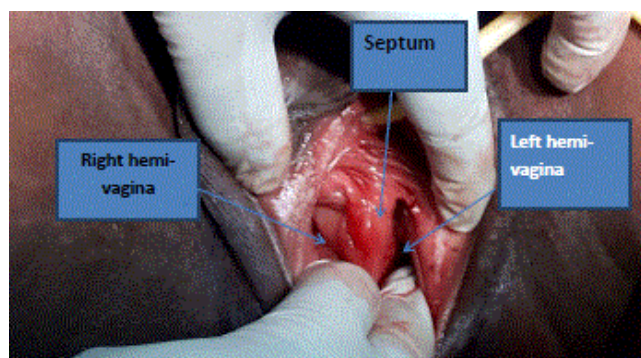


Figure 1: Post-operative observation allowing the two hemi-vaginas and the vaginal septum to be seen.

The indication for caesarean section was established; carried out, it enabled to remove from the right by the cephalic pole J1 weighing 1200 g and from the left J2 weighing 2750 g.

Both have a normal external morphology. The fetus presented signs of prematurity namely a thin, transparent, reddened wrinkled skin covered with downy hairs. It has much but woolly hair, a poor tonus, a soft cartilage (abnormal hemmed ears).

The pre-operative exploration of the patient's internal genital organs showed:

- A bicornuate uterus whose left hemi uterus seems a bit bigger than the right hemi uterus. The hemi cervixes were joined together like two parallel shotgun barrels.
- A rupture of the left horn with a large edema on the lower segment on the same side and the sides are ecchymotic. All this is in correlation with a large hematoma of the left adnexa.
- The right horn comprised a lot of varicose veins.
- Each horn has on its side a tube and an ovary which are apparently healthy.
- A thorough examination of the vagina when cleaning it revealed two hemi vaginas partitioned by a solid septum and each hemi vagina ended in a different uterine cervix.
- No particularity was noticed during the general examination of the patient (Figure 2).

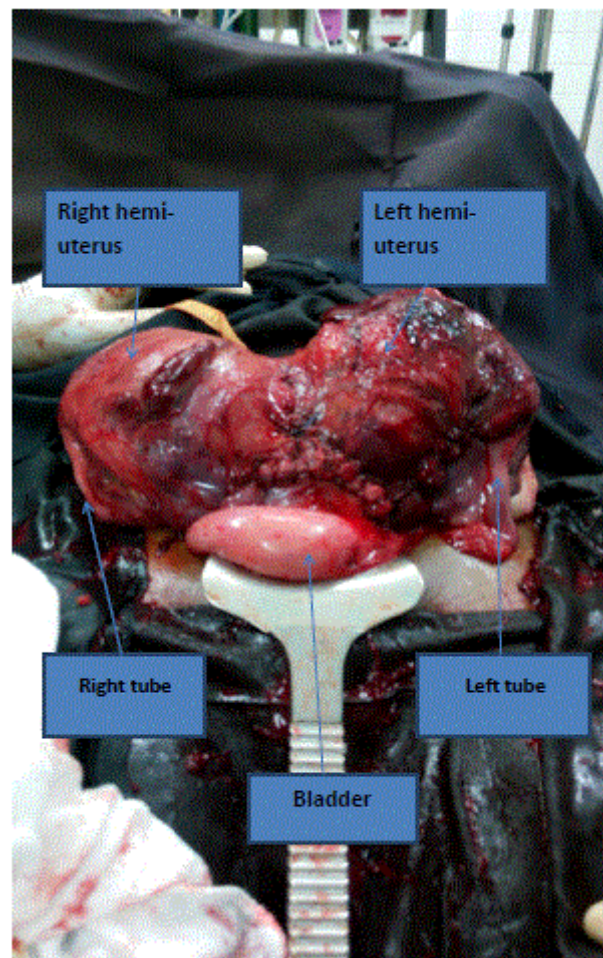


Figure 2: Per-operative observation allowing the two hemi-uteruses, the tube and the bladder to be seen.

Discussion

The patient has a bicornuate bicervical uterus. In literature according to Rudigo et al., a distinction has to be made on the obstetrical level, between three big classes of uterine malformations:

- Septate uterus whose gynecological-obstetrical prognosis would be more severe.
- Bicornuate unicervical or bicervical uterus, which can be related to cervico-vaginal septa or to a unilateral menstrual retention.
- Unicornuate or pseudo-unicornuate or rudimentary uterine horns can be places for a pregnancy evolving as an ectopic pregnancy revealed late [3].

Incidence of uterine malformations

The prevalence of congenital uterine anomalies in population is estimated between 1 and 4% according to studies [4,5]. For Funk 1 to 2% of women have an abnormal uterine development due the non-fusion of mullerian ducts during embryonic life [6]. Actually, the real incidence of these malformations remains unknown. And as evidence, the diagnosis is often established among female patients for infertility,

repeated miscarriages or premature deliveries. In this case, the patient was asymptomatic during her genital lifetime and during her pregnancy. The diagnosis was established during the clinical examination when she was admitted for medical treatment due to her full term delivery.

Diagnosis and means of investigation

For the assessment of a genital malformation, the different techniques used are the 2D or 3D ultrasound, hysterosonography, MRI, hysteroscopy and laparoscopy [7]. These different techniques can be combined with each other. 3D ultrasound and MRI are currently the techniques giving better outcomes in terms of sensitivity and specificity [8,9].

The assessment of uterine malformations must be completed by a renal imaging to detect the malformations of urinary tract which are frequently associated with it. The ultrasound must always be carried out, because it is the only exploration which makes possible a precise endo and exo uterine assessment. In practice, its sensitivity is not very important (30% to 40%) and it is directly related to the experience of the sonographer. De Crespigny, et al. think that if diagnostic pitfalls are avoided by a careful attention, hysterosonography with a saline solution is a new and powerful means of gynecological investigation namely when exploring congenital uterine anomalies [10]. The patient was not offered any means of investigation. The diagnosis was not made before and during the pregnancy and no indicative sign was noticed.

Uterine malformations and obstetrical prognosis

The obstetrical prognosis of uterine malformations remains very poor [3]. For Maione et al., recurrent spontaneous abortions were the most frequent among 50% of couples whose wives had uterine malformations [11].

- As for Mishel, in his study he finds 0.5% recurrent spontaneous abortions [12].
- A study carried out by Heinomen among 71 pregnancies in a didelphic uterus (76% of which on the right, 24% on the left) reveals 21% early miscarriages, 14% late miscarriages, 11% intrauterine growth restrictions (IUGR), 24% prematurity, 75% live births, 5.3% perinatal mortality and 84% Cesarean sections [13].
- In our case, the pregnancy evolves normally; she was offered 5 antenatal consultations with no indication of pathology requiring neither hospitalization nor tocolysis. J1 in the right hemi uterus was premature and weighed 1200 grams whereas J2 in the left hemi uterus was full term and weighed 2750 grams. Likewise, one of the new born babies is premature whereas the second presents signs of maturity.

Ways to give birth in case of uterine malformations

As for the way to give birth, the incidence of cesarean sections is significantly higher in case of uterine malformations, with rates between 27.5% and 83% according to authors. This can be accounted by the fact that uterine malformations are often associated with dystocic presentations, but they are also associated with a more frequent contractility anomalies during labor in about 50% of cases, such as cervical and dynamic dystocias [14-16].

Concerning our patient, emergency cesarean section was indicated due to fetal distress after a long and dystocic labor in a neighborhood

center. The vaginal delivery was attempted by a medical staff ignoring the existence of a uterine malformation.

Ways to give births in case of malformed scarred uteruses

In a cohort of 1813 female patients, Ravisia et al. studied the risk of uterine rupture during labor pain among patients having a uterine malformation (bicornuate, unicornuate and septate uterus) and a history of cesarean section [17]. They estimated this risk at 8% (2/25), comparable to the risk of corporeal scars. However, these outcomes have to be interpreted with precaution because in this study, both cases of uterine rupture among the patients having a uterine malformation took place after a cervical ripening by PGE2 gel. In our patient's case, a rupture of the left horn with a large edema on the lower segment with ecchymotic sides and a large edema on the left adnexa. There was no rupture at the level of the right horn but the presence of several varicose veins could be noticed.

However, Bujold et al., in a more recent study on 165 labor pains among patients having an uterine malformation and a history of cesarean section give no indication of uterine rupture [18].

These outcomes give us arguments to try vagina delivery with our patients having uterine malformations if the requirements of vagina delivery are met. For our case, since a rupture of the left horn happened, an iterative cesarean section will be carried out for the next pregnancy.

Conclusion

Uterine malformations are frequent in general population but the consequences on reproduction vary according to the type of malformation. The obstetrical prognosis among women having a permeable bicornuate bicervical uterus often seems to be very good. Nevertheless, the obstetrical ultrasound of the first quarter which enables to diagnose the intra uterine pregnancy but also to check the absence of uterine malformation must be systematically proposed to all pregnant women during antenatal consultations.

References

1. Saravelos SH, Cocksedge KA, Li TC (2008) Prevalence and diagnosis of congenital uterine anomalies in women with reproductive failure: a critical appraisal. *Hum Reprod Update* 14: 415-429.
2. Troiano RN, McCarthy SM (2004) Mullerian duct anomalies: imaging and clinical issues. *Radiology* 233: 1934.
3. Rudigoz RC, Gaucherand P, Dargent D (1989) Impact obstetric uterine malformations. *J Gynecol Obstet Biol Reprod* 18: 185-191.
4. Raga F, Bauset C, Remohi J (1997) Reproductive impact of congenital Mullerian anomalies. *Hum Reprod* 12: 2277-2281.
5. Nahum GG (1998) Uterine anomalies: How common are they, and what is their distribution among subtypes? *J Reprod Med* 43: 877-887.
6. Funk A, Fendel H (1988) Ultrasonic diagnosis of congenital uterine abnormalities. *Z Geburtshilfe Perinatol* 192: 77-82.
7. Deutch TD, Abuhamad AZ (2008) The role of 3-dimensional ultrasonography and magnetic resonance imaging in the diagnosis of mullerian duct anomalies: a review of the literature. *J Ultrasound Med* 27: 41323.
8. Salim R, Woelfer B, Backos M, Regan L, Jurkovic D (2003) Reproductibility of three-dimensional ultrasound diagnosis of congenital uterine Anomalies. *Ultrasound Obstet Gynecol* 21: 578-582.
9. Woelfer B, Salim R, Banerjee S (2001) Reproductive outcomes in women with congenital uterine anomalies detected by three-dimensional ultrasound screening. *Obstet Gynecol* 98: 1099-1103.

10. De Crespigny L, Kuhn R, Mc Ginnes D (1997) Saline infusion sonohysterosalpingography: An underutilized technique. *Aust NZ J Obstet Gynaecol* 37: 206-209.
11. Maione S, Lambert L, Alovise C, Armellino F (1995) Retrospective study of couples with a history of recurrent spontaneous abortion. *Acta Eur Fertil* 26: 95-100.
12. Mishel DR Jr (1993) Recurrent abortion. *J Reprod Med* 38: 250-259.
13. Heinonen PK (2000) Clinical implications of the didelphic uterus: long-term follow-up of 49 cases. *Eur J Obstet Gynecol Reprod Biol* 91: 183-190.
14. Savey L, Le Tohic A (2003) Malformations utérines. *EMC-Gynécologie* 123: A10.
15. Zhang Y, Zhao Y, Qiao J (2010) Obstetric outcome of women with uterine anomalies in China. *Chin Med J* 123: 418-422.
16. Shuiqing M, Xuming B, Jinghe L (2002) Pregnancy and its outcome in women with malformed uterus. *Chin Med Sci J* 17: 242-245.
17. Ravisia DJ, Brain PH, Pollard JK (1999) Incidence of uterine rupture among women with mullerian duct anomalies who attempt vaginal birth after cesarean delivery. *Am J Obstet Gynecol* 181: 877-881.
18. Bujold E, Gauthier RJ (2010) Risk of uterine rupture associated with an interdelivery interval between 18 and 24 months. *Obstet Gynecol* 115: 1003-1006.