

Tuberculosis of Glans Penis: A Case Report

El Anzi Ouiam^{1*}, Maouni Safae¹, Boualaoui Imad², Zenati Kaoutar³, Meziane Mariam¹, Hassam Badredine¹

¹Department of Dermatology-Venereology, Ibn Sina University Hospital, Mohammed V University, Rabat, Morocco

²Department of Urology A, Ibn Sina University Hospital, Mohammed V University, Rabat, Morocco

³Department of Anatomopathology, Ibn Sina University Hospital, Mohammed V University, Rabat, Morocco

*Corresponding author: El Anzi Ouiam, Department of Dermatology-Venereology, Ibn Sina University Hospital, Mohammed V University, Rabat, Morocco, Tel: +00 212 6 24 60 41 05; E-mail: elanzi.ouiham@gmail.com

Received date: September 27, 2018; Accepted date: October 17, 2018; Published date: October 22, 2018

Copyright: ©2018 Ouiam EA, et al. This is an open-access article distributed under the terms of the Creative Commons Attribution License, which permits unrestricted use, distribution, and reproduction in any medium, provided the original author and source are credited.

Abstract

Tuberculosis of penis is a very rare entity. It may present as primary or secondary to Pulmonary TB. We present the case of a 43-year-old male patient who presented to us with ulcerative growth over glans penis, biopsy of the lesion showed evidence of tuberculosis.

Keywords: Penile Tuberculosis; Genital ulcer rare; Anti-tuberculous therapy.

Introduction

Tuberculosis is a bacterial infectious disease in Mycobacterium tuberculosis. Genitourinary tuberculosis (TB) is a common site for extra pulmonary tuberculosis. But tuberculosis of the penis is an extremely rare entity with few cases described in the literature.

Clinical case

A 43-year-old man presented with complaint of painless and non-healing lesion over his genitalia for last 13 months. He had no history of any loss of weight in the recent past and He denied extramarital sexual contact or dysuria.

The patient had tried different treatment modalities without any response.

Dermatological examination of the penis found multiple ulcers, some of them confluent, with jagged edges and indurated base.

The rest of the clinical examination objectified bilateral, sensitive and mobile inguinal lymph nodes. Haematological and biochemical examination did not reveal any abnormality.

A Laboratory test for syphilis, serology for HIV and Viral Hepatitis B and C were negative. The histological examination of the ulceration revealed intense granulomatous infiltrate with Langhans giant cells and caseation necrosis, first evoking tuberculosis. Radiological investigations including X-ray chest and ultrasound of the abdomen, to find any collateral evidence of TB, were normal. The patient was treated with anti-bacillary drugs: rifampicin (R), isoniazid (H), pyrazinamide (Z) and ethambutol (E) during two months relayed by a dual therapy combining R and H during four months (Figure 1). The healing of genital ulcer was complete.

Comments

TB of the genitourinary tract is the most common site for extra pulmonary disease [1]. But TB of the penis is extremely rare. Very few

cases have been described worldwide with less than 1% of all genital TB cases reported [2].

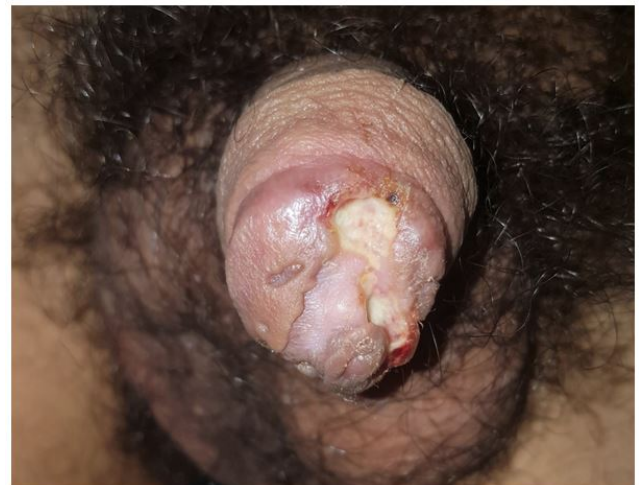

Figure 1: Multiple ulcers with well-defined irregular margins present all around the glans penis

It is classically contracted during a traditional circumcision. Sexual intercourse with a partner with genital or pulmonary tuberculosis has been recently described. Inoculation from contaminated clothing is rare.

The main differential diagnosis is penile carcinoma should be removed by histological examination.

The diagnosis of tuberculosis is based on a bundle of clinical, histological, bacteriological and immunological arguments [3,4]. Localization far from the meatus eliminates an urogenital or periorificial form. Lupus vulgaris is evolving very slowly and is accompanied by progressive tissue destruction (Figure 2).

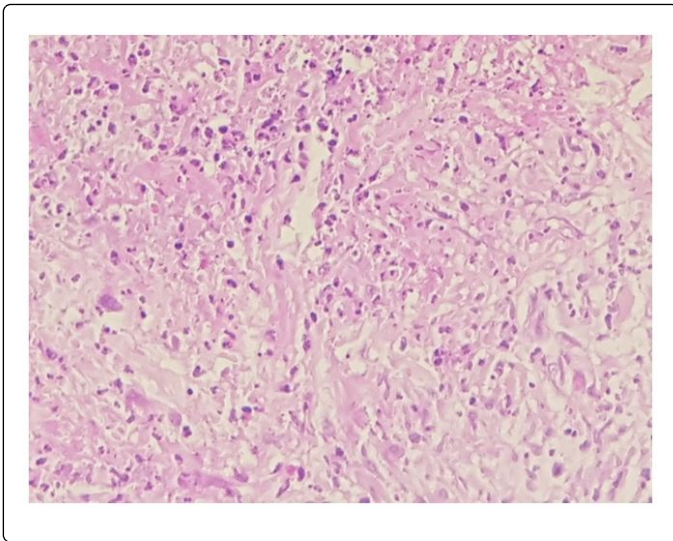


Figure 2: Cutaneous histology (HES, G x 100), epithelioid granuloma with central area of necrosis surrounded by lymphocytes.

Histologically, there is a tuberculoid granuloma but gaseous necrosis is rarely found. The treatment of cutaneous tuberculosis is the same as that of pulmonary tuberculosis using the RHZE association for two months then RH for four months.

Conclusion

Any chronic non-healing ulcer over the penis should arouse a suspicion of tuberculosis, especially in an endemic country like Morocco.

References

1. Gangalakshmi C, Sankaramahalingam (2016) Tuberculosis of Glans Penis- A Rare Presentation. J Clin Diagn Res 10: PD05-PD06.
2. Khan D, Choudhary A, Dutta A, Khan I (2016) Tuberculosis of the glans penis mimicking as carcinoma. Int J Mycobacteriol 5: 341-342.
3. Venyo AK (2015) Tuberculosis of the penis: a review of the literature. Scientifica 2015: 601624.
4. Stockamp NW, Paul S, Sharma S, Libke RD, Boswell JS, et al. (2013) Cutaneous tuberculosis of the penis in an HIV-infected adult. Int J STD AIDS 24: 57-58.