

Case Report

Open Access

Triple Ectopic Thyroid: A Case Report and Review of Literature

Kuramoto R¹, Oikawa K¹, Fujita K¹, Oridate N^{2,3*} and Fukuda S²

¹Department of Otolaryngology, Tenshi Hospital, Sapporo, Japan

²Department of Otolaryngology-Head and Neck Surgery, Hokkaido University Graduate School of Medicine, Sapporo, Japan

³Department of Otolaryngology-Head and Neck Surgery, Yokohama City University Graduate School of Medicine and School of Medicine, Yokohama, Japan

Abstract

Ectopic thyroid is an embryological abnormality resulting from the aberrance or failure of thyroid gland descent. We present a case of triple ectopic thyroid in a 10-year-old girl. Plain computed tomography and Tc-99m scans showed three ectopic thyroids located near the hyoid bone with no normally positioned thyroid. The patient was euthyroid at presentation, but hypothyroidism was observed five months later. On treatment with levothyroxine (75 µg/day), FT4 and TSH returned to normal ranges. Cases of multiple ectopic thyroid are rare, with the present case being only the third case of triple ectopic thyroid presented. A careful follow-up is required because the incidence of malignancies associated with ectopic thyroid can be as high as 10%. Surgical treatment should be considered when the patient shows symptoms such as dysphagia, dysphonia, bleeding or dyspnea.

Keywords: Multiple Thyroid Ectopy; Malignancy

Case Report

A 10-year-old girl was admitted with a 1-month history of neck swelling. The lesion was a 20 mm × 15 mm soft, movable mass in the midline of the neck (Figure 1). Ultra sonography showed a solid midline mass, and plain computed tomography (CT) scans demonstrated three high-density masses around the hyoid bone near the base of tongue, pre hyoid region and pre-tracheal region, respectively (Figure 2). No normally positioned thyroid gland was observed. Laryngeal fiber scopic examination revealed a mass with a smooth surface at the base of tongue (Figure 3). The patient did not present with any airway obstruction or dysphagia. Tc-99m scans showed uptake in the region of the three masses. No uptake was seen in the normal thyroid (pre-tracheal) position (Figure 4). Serum FT3, FT4 and thyroid-stimulating hormone (TSH) levels were within normal ranges at presentation, although the thyroglobulin (Tg) level was elevated (218.7 µIU/L), and other laboratory tests were also within normal limits. Decreased FT4 (0.7 ng/dl), increased TSH (5.71 µIU/L) and further increased Tg (376.2 µg/L) levels were observed five months after the initial examination. The patients had screening test for congenital hypothyroidism and the abnormality was not pointed out. The patients have no the mental

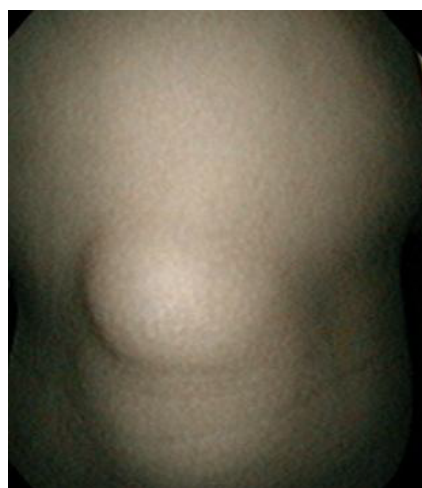

Figure 1: A 20 mm x 15 mm soft movable mass can be observed in the middle neck.

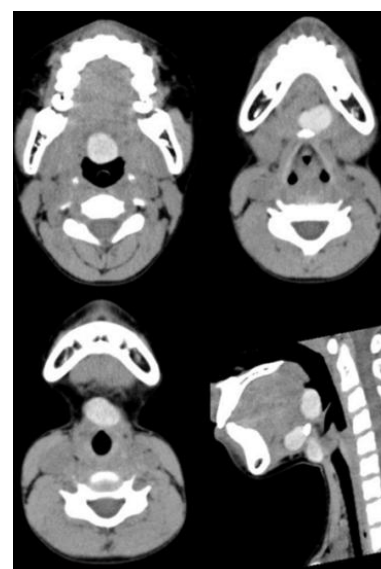


Figure 2: CT image (axial and sagittal section) showing a triple ectopic thyroid (base of the tongue, sub mandibular region and pre-tracheal region) without any normal thyroid.

disability. A thyrotropin-releasing hormone (TRH) stimulation test was performed to evaluate the function of the pituitary gland. TSH level peaked 15 minutes after an intravenous bolus of TRH with the result within normal limits (Table 1). Although the reason why the patient became slightly hypothyroidism within five months was unknown, we

***Corresponding author:** Nobuhiko Oridate, Department of Otolaryngology-Head and Neck Surgery, Yokohama City University Graduate School of Medicine and School of Medicine, Fukuura 3-9, Kanazawa-ku, Yokohama 236-0004, Japan; Tel: +81-45-787-2687; Fax: +81-45-783-2580; E-mail: noridate@yokohama-cu.ac.jp

Received June 24, 2013; **Accepted** August 05, 2013; **Published** August 08, 2013

Citation: Kuramoto R, Oikawa K, Fujita K, Oridate N, Fukuda S (2013) Triple Ectopic Thyroid: A Case Report and Review of Literature. *Thyroid Disorders Ther* 2: 126. doi:10.4172/2167-7948.1000126

Copyright: © 2013 Kuramoto R, et al. This is an open-access article distributed under the terms of the Creative Commons Attribution License, which permits unrestricted use, distribution, and reproduction in any medium, provided the original author and source are credited.

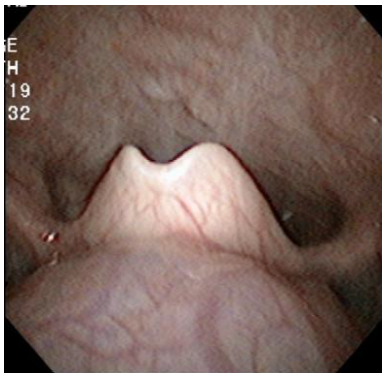


Figure 3: Endoscopic image showing a solid, spherical mass covered with intact mucosa at the base of the tongue.

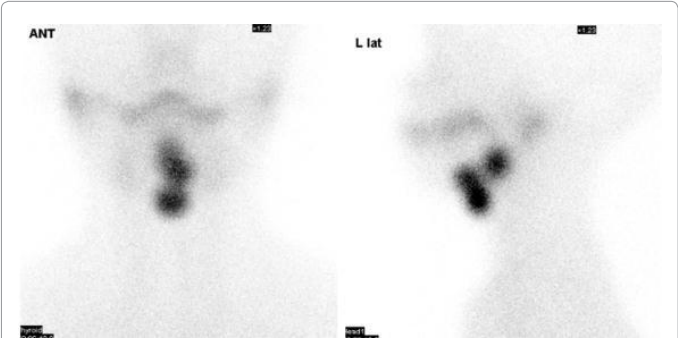


Figure 4: A thyroid scans showing a triple ectopic thyroid without any normal thyroid.

Time(min)	0	15	30	60	90	120
TSH(μ U/ml)	2.8	29.9	25.1	15.1	9.1	5.6

Table 1: TSH values after stimulation by TRH.

decided to give levothyroxine to the patient because the swell of the ectopic thyroid and Tg elevation might be compensatory reaction for hypothyroidism. Treatment with levothyroxine (75 μ g/day) resulted in FT4 and TSH levels returning to normal ranges together with a gradual decrease in Tg level.

Discussion

Ectopic thyroid, which was first reported in 1869 by Hickman, is an embryological abnormality [1]. The thyroid gland descends from the foramen caecum of the tongue to its final pre-tracheal position through the thyroglossal duct by 7 weeks gestation [2]. Ectopic thyroid arises from an aberrance or failure of its descent. Ectopic thyroid tissue usually occurs between the foramen caecum and the mediastinum.

Lingual thyroid (ectopic thyroid occurring at the base of tongue) is the most common type, accounting for 90% of all ectopic thyroids [3]. Other sites, all rare, include under the tongue, above the hyoid bone, in front of the larynx, the mediastinum, duodenum, esophagus, lungs and so on. A few cases of dual ectopic thyroid have been reported [4-5]. In most dual thyroid cases; the lesion is lingual and subhyoid. Only two cases of triple ectopic thyroid have been reported [6-7], with the present case being the third case.

The prevalence of ectopic thyroid varies between 1:100000 and 1:300000 and its clinical incidence is reported to range from 1:4000

to 1:10000. A male to female ratio of 1:4 is documented [8]. In 25% of cases, orthotropic thyroid tissue is also observed at the normal pre-tracheal position [2].

Most patients with ectopic thyroid are asymptomatic [9]; however, symptoms such as dysphagia, dysphonia, bleeding or dyspnea may occur as the ectopic thyroid (especially in cases of lingual thyroid) grows [10-11]. Thyroid function is either hypothyroid or euthyroid in most cases. About 33-62% of the patients with ectopic thyroid showed hypothyroidism with increased levels of TSH [12]. A few cases of hyperthyroid have also been reported [13].

Thyroid scanning using technetium Tc-99m is the most useful tool for definitive diagnosis [8]. Thyroid scanning detects the presence of thyroid tissue in other sites. Additional CT scans or MRI may help in defining the extent or location of the ectopic thyroid gland. Differential diagnosis includes angioma, adenoma, fibroma, lipoma, lymphangioma and cysts in the neck [8], with thyroglossal duct cysts, which arise from epithelial remnants of the thyroglossal duct, also representing a major differential diagnosis. Thyroglossal duct cysts present as low-density masses on plain CT, whereas ectopic thyroid shows a high density as in our case [7].

Management of ectopic thyroid is controversial. If the patient is both asymptomatic and euthyroid, no treatment is required. The main concern is the risk of thyroid carcinomas, in most cases papillary carcinomas [14], arising from the ectopic thyroid tissue. Jarvis et al. reported that the risk of malignancies in cases of ectopic thyroid was 1% in 1969 [15]. This figure was quoted from a review published in 1934. Massine et al. reviewed 28 case reports of lingual thyroid carcinoma [16] and, in review of the English literature, we found that 33 cases of ectopic thyroid carcinoma has been reported in approximately 400 cases of ectopic thyroid (Table 2). This indicates that the potential for malignancy is as high as 10%. The reason for the very high incidence

Case no	Author	Date	Pathology
1	Stith JA	1981	Papillary adenocarcinoma
2	Laing MR	1988	Mixed papillary-follicular carcinoma
3	Michigishi T	1991	Papillary carcinoma
4	Zink A	1991	Papillary carcinoma
5	Satta MA	1991	Papillary carcinoma
6	Hoffmann R	1991	Papillary carcinoma
7	Betkowski A	1993	Follicular carcinoma
8	Cervera-Paz FJ	1994	Papillary carcinoma
9	Jayaram G	1995	Papillary carcinoma
10	Sand J	1996	Papillary carcinoma
11	Subramony C	1997	Follicular carcinoma
12	Hirnle T	1997	Follicular carcinoma
13	See AC	1998	unknown
14	Tucci G	1999	Follicular carcinoma
15	Casella A	1999	Papillary carcinoma
16	Hari CK	1999	Tall cell variant of papillary carcinoma
17	Massine RE	2001	Papillary carcinoma
18	Kao SY	2002	Papillary carcinoma
19	Pérez JS	2003	Papillary carcinoma
20	Ling L	2004	Papillary carcinoma
21	Lee HY	2004	Papillary carcinoma
22	Miller RS	2005	Papillary carcinoma
23	Ling L	2005	Follicular variant of papillary carcinoma
24	Shah BC	2007	Follicular variant of papillary carcinoma
25	Yaday S	2008	Medullary carcinoma

26	Choi JY	2008	Metastatic papillary thyroid carcinoma
27	Kandogan T	2008	Follicular variant of papillary carcinoma
28	Hari CK	2009	Follicular variant of papillary carcinoma
29	Adotey JM	2009	Papillary adenocarcinoma
30	Cordes S	2010	Papillary carcinoma
31	Sevinç AI	2010	Papillary carcinoma
32	Wang YJ	2010	Papillary carcinoma
33	Borges A	2010	Papillary thyroid microcarcinoma

Table 2: Reported cases of carcinomas arising from ectopic thyroid

malignancy (10%) in ectopic thyroid tissue that we found in the literature is unknown. One possible reason is that ectopic thyroid tissue only calls medical attention when there is an enlargement due to infection, tumors etc. Asymptomatic lingual thyroid glands were found in as much as 10% of the autopsies. Therefore, ectopic thyroid glands are probably much more common than it is reported. In this sense the rate malignancy may be probably much lower than 10%. Even though, careful follow-up for cases of ectopic thyroid is necessary. In our case, fine needle aspiration cytology would be needed when the ectopic gland has more enlarged.

It should be also kept in mind that, even if the patient is euthyroid, the patient could later develop hypothyroidism as in our case. If the patient is hypothyroid with an elevated TSH, thyroid hormone therapy might prevent enlargement or malignant transformation of the ectopic thyroid [9,17]. Surgical treatment should be considered when the patient is symptomatic [18]. Also, cervical ectopic thyroids may be removed surgically for cosmetic reasons. Several external or trans-oral surgical approaches have been described [19].

References

- Hickman W (1869) Congenital tumor of the base of the tongue, causing death by suffocation. *Trans Pathol Soc London* 20: 160–163.
- Batsakis JG, El-Naggar AK, Luna MA (1996) Thyroid gland ectopias. *Ann Otol Rhinol Laryngol* 105: 996-1000.
- Basaria S, Westra WH, Cooper DS (2001) Ectopic lingual thyroid masquerading as thyroid cancer metastases. *J Clin Endocrinol Metab* 86: 392-395.
- Baik SH, Choi JH, Lee HM (2002) Dual ectopic thyroid. *Eur Arch Otorhino laryngol* 259: 105-107.
- Ulug T, Ulubil SA, Alagol F (2003) Dual ectopic thyroid: report of a case. *J Laryngol Otol* 117: 574-576.
- Barai S, Bandopadhyaya GP, Kumar R, Malhotra A, Halanaik D (2004) Multiple ectopic thyroid masses in a hypothyroid child. *Pediatr Radiol* 34: 584.
- Jain A, Pathak S (2010) Rare developmental abnormalities of thyroid gland, especially multiple ectopia: A review and our experience. *Indian J Nucl Med* 25: 143-146.
- Noussios G, Anagnostis P, Goulis DG, Lappas D, Natsis K (2011) Ectopic thyroid tissue: anatomical, clinical, and surgical implications of a rare entity. *Eur J Endocrinol* 165: 375-382.
- Toso A, Colombani F, Averono G, Aluffi P, Pia F (2009) Lingual thyroid causing dysphagia and dyspnoea. Case reports and review of the literature. *Acta Otorhino laryngol Ital* 29: 213-217.
- Mussak EN, Kacker A (2007) Surgical and medical management of midline ectopic thyroid. *Otolaryngol Head Neck Surg* 136: 870-872.
- Katz AD, Zager WJ (1971) The lingual thyroid. Its diagnosis and treatment. *Arch Surg* 102: 582-585.
- Yoon JS, Won KC, Cho IH, Lee JT, Lee HW (2007) Clinical characteristics of ectopic thyroid in Korea. *Thyroid* 17: 1117-1121.
- Abdallah-Matta MP, Dubarry PH, Pessey JJ, Caron P (2002) Lingual thyroid and hyperthyroidism: a new case and review of the literature. *J Endocrinol Invest* 225: 264-267.
- Shah BC, Ravichand CS, Juluri S, Agarwal A, Pramesh CS, et al. (2007) Ectopic thyroid cancer. *Ann Thorac Cardiovasc Surg* 13: 122-124.
- Jarvis JF (1969) Lingual thyroid: a report of three cases and discussion. *S Afr Med J* 43: 8-12.
- Massine RE, Durning SJ, Koroscil TM (2001) Lingual thyroid carcinoma: a case report and review of the literature. *Thyroid* 11: 1191-1196.
- Farrell ML, Forer M (1994) Lingual thyroid. *Aust N Z J Surg* 64: 135-138.
- Rahbar R, Yoon MJ, Connolly LP, Robson CD, Vargas SO, et al. (2008) Lingual thyroid in children: a rare clinical entity. *Laryngoscope* 118: 1174-1179.
- Hafidh MA, Sheahan P, Khan NA, Colreavy M, Timon C (2004) Role of CO₂ laser in the management of obstructive ectopic lingual thyroids. *J Laryngol Otol* 118: 807-809.