

Treatment of Developmental Dysplasia of the Hip: Short and Mid-term Outcome in Alnoor Specialized Hospital

Salem Jafar Bajuifer, Mohamed Hassan Shaalan* and Ashraf Dawood

Orthopaedic Department, AlNoor Specialized Hospital Makkah, Saudi Arabia

*Corresponding author: Mohamed Hassan Shaalan, Orthopaedic Department, AlNoor Specialized Hospital Makkah, Saudi Arabia, Tel : + 353894483263; E-mail: shalan_6@yahoo.com

Received date: August 19, 2018; Accepted date: September 07, 2018; Published date: September 14, 2018

Copyright: © 2018 Bajuifer SJ, et al. This is an open-access article distributed under the terms of the Creative Commons Attribution License, which permits unrestricted use, distribution, and reproduction in any medium, provided the original author and source are credited.

Abstract

Objective: To review the presentation and outcome of developmental dysplasia of the hip (DDH) cases in the last 10 years managed in Alnoor specialized hospital.

Methodology: We retrospectively reviewed the presentation as well as short and mid-term outcome of 208 children (296 hips) with DDH seen and treated from 2005 to 2015. Treatment was either with closed or open reduction depending on age at presentation and the individual needs of each patient. Adductor tenotomy done for all patients either closed or open reduction.

Results: The average age at presentation was 31.1 months, and the male to female ratio was 1:3.6. Eighty patients (42.6%) presented early (less than 6 months old) while 62 patients (33%) presented between 6-24 months and 46 patients (24.4%) presented late than two years. After a period of skin traction average 10 days, in these patients closed reduction under anesthesia was initially utilized for treatment depending on age, and open reduction was used after failure of closed reduction and for those presented late. Average age at the time of closed reduction was 13 months, and 3 years for those underwent open reduction. The average period of follow up for all patients was 29.4 months. The final outcome was successful with good functional results in 214 hips (72.3%) in 134 patients.

Conclusion: Late presentation of DDH is still common in Saudi Arabia, which necessitates more complex management and more frequent occurrences of unfavorable results. The overall results of either closed or open reduction was good.

Keywords: Developmental dysplasia of the hip; DDH; Femoral osteotomy; Hip spica

Introduction

Congenital dislocation of the hip (CDH) refers to an abnormal configuration of, or relationship between, the femoral head and the acetabulum. It is a continuum of disorders that ranges from shallowness of the acetabulum, to instability and subluxation of the femoral head, to frank dislocation, the term congenital implies that a condition existed at birth. In the paediatric orthopaedic literature, the long standing terminology of congenital dislocation of the hip has been progressively replaced by the use of dysplasia or developmental dysplasia of hip (DDH) [1].

Developmental dysplasia of the hip (DDH) refers to abnormality in size, shape, orientation and organization of femoral head, acetabulum or both anatomical structures.

In 2% of cases the hip dislocation is not evident at birth but manifest in first few months of the life [2].

The true incidence of DDH cannot be estimated because there is no "gold standard" for diagnosis. Most developed countries report an incidence of 1.5 to 20 cases of DDH per 1000 births, depending in part on the methods of screening used [3].

The etiology of DDH is multifactorial involving genetic, hormonal and intra-uterine factors. Several recent studies have focused on the

genetic etiology of DDH. Certain genetic markers have been identified for DDH but these are not yet diagnostic [4].

In order to obtain normal function and development of the hip, an anatomical reduction is necessary. It should be stated that a certain proportion of patients with a good reduction still do not achieve normal function, with possibility of osteoarthritis development in later life [5].

The aim of this study is to evaluate the result of the management of DDH either closed or open in Alnoor specialist hospital over a period of time of 10 years. The indication of open reduction is late presentation and failure of closed reduction.

Patients and Methods

From 2004 to 2014, 188 patients (296 hips) had managed at the Orthopaedic department, Alnoor specialist hospital, Saudi Arabia, representing the senior author's first ten years' experience of this procedure. Patients admitted 10 days prior to the procedure for Galos traction most of the time all over 24 hours, all patients received general anaesthesia, all patient underwent adductor tenotomy and trial of closed reduction, if reduced easily and safety zone within the accepted range then bilateral hip spica applied for 3 months, indications for open reduction was failed closed reduction, or the patient age more than 3 years. Open reduction was proceeded under general anaesthesia, after prep and drape, through pikiini incision, tenotomy of the sartorius and straight head of rectus femoris, exposing the capsule with

tomy of the tendinous part of the iliopsoas muscle, splitting of the iliac apophysis, subperiosteal dissection of the outer iliac bone to mobilize the capsule from the pseudo acetabulum and reflect it down, the opening the capsule T-shaped, follow the ligamentum teres to the true acetabulum then excised with the transverse acetabular ligament, cleaning of the acetabulum from the pulvinar, test the ease of reduction of the hip joint, if difficult then consider femoral shortening osteotomy to be fixed with 4 holes plate and screws, the point is to reduce the hip easily to minimize the pressure on the femoral head so keep viability of the head, the femoral osteotomy was needed in 53 patients including 71 hips, if the acetabulum is shallow, salter innominate osteotomy done which was indicated in 6 patients including 6 hips, the capsule is reflected down subperiosteally to create shelf like to aid to the coverage of the femoral head, capsulorrhaphy done and sutured by two stitches, reattachment of the rectus femoris and sartorius, repositioning of the iliac apophysis and lastly the skin sutured subcuticular, application of bilateral hip spica for total period of 3 months. In case of bilaterality two weeks gap between the two procedures.

We noticed changes of the articular cartilage of the femoral head at the time of open reduction areas of erosions and denuded cartilage which might explain the occurrence of AVN in certain cases (Figures 1-5).

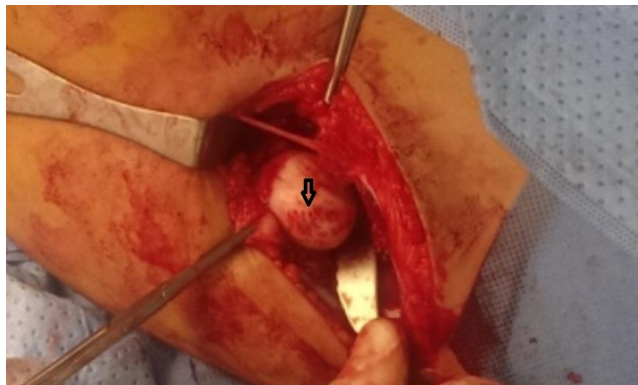


Figure 1: Postoperative X-rays both hips for all patients managed by open reduction but for all patients managed by closed reduction CT both hips is done for evaluation of the accuracy of concentric reduction.

Results

182 hips in were treated by closed reduction (61.5%) and 114 hips were treated with open reduction (38.5%).

There were no post-operative infections and concentric reduction was obtained at the time of operation in all hips. Number of patients required subsequent surgery for recurrence after closed reduction 9 hips in 9 patients (3%), no recurrence of dislocation after open reduction, one patient only need change of spica because of dirty and broken spica, one patient developed pressure sore which resolve completely after removal of spica. At the final follow-up, the clinical results were rated as excellent in 182 hips, good in 32 hips and fair in 82 hips (Table 1).

Avascular necrosis of the femoral head was observed 23 hips (7.8%) of closed reduction and 18 hips (6.1) of open reductions. Acetabular irregularity was noted in one hip of open reduction and a mild coxa

valga deformity in two although Shenton's line was normal. Leg lengthening of less than 1 cm was present in 9 hips (3%) of closed reduction and 13 hips (4.4%) of open reduction hips at the final follow-up, but gait was normal and the Trendelenburg test negative. Femoral shortening derotation osteotomy was needed in 71 hips due to difficult reduction, salter innominate osteotomy was required in 6 hips.

| Grade | | Number | % |
|-------------|---|--------|------|
| I Excellent | Stable, painless, no limp, negative Trendelenburg, full range of movement | 182 | 61.5 |
| II Good | Stable, painless, slight decrease hip movement, negative Trendelenburg | 32 | 10.8 |
| III Fair | Minimal pain, moderate stiffness, positive Trendelenburg | 82 | 27.7 |
| IV Poor | Unstable, painful or both, positive Trendelenburg | 0 | 0 |

Table 1: Clinical results according to modified McKay criteria.

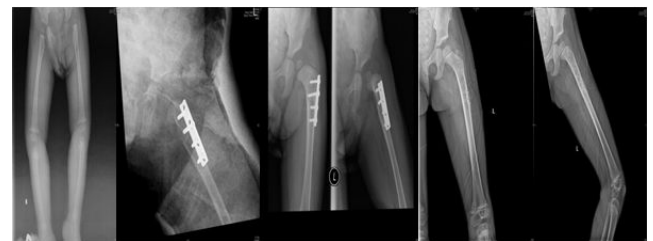

Figure 2: 4 years old female patient presented at the age of 1.5 years with unilateral DDH, patient operated after 3 months (two years follow up).

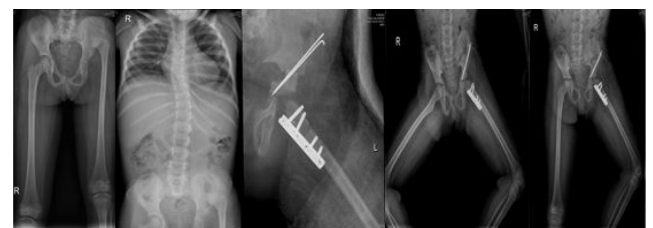

Figure 3: 9 years old female patient presented at the age of 6 years with unilateral DDH, patient operated after 4 months (3years follow up).

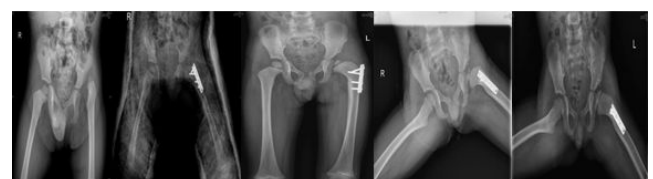

Figure 4: 8 years old male patient presented at the age of 5 years with unilateral DDH operated after 5 months (3years follow up).

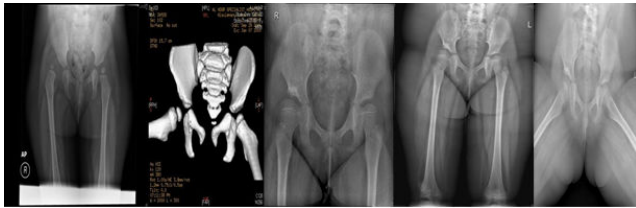

Figure 5: 8 years old male patient presented at the age of one year and eight months age with unilateral DDH operated after 3 months (six years follow up).

Discussion

The aim of treatment in developmental dysplasia of the hip is to achieve stable concentric reduction as early as possible. This study showed according to clinical and radiographic results in the final follow-up, were rated as excellent in 182 hips, good in 32 hips and fair in 82 hips, at an average of 5.1 years of follow-up. The results were compared to what was published in literature.

Berkeley et al reported a series of 51 dislocated hips in patients between 12 and 36 months. They performed a derotational femoral osteotomy in 85% of the hips and a femoral shortening osteotomy in only two hips. They found excellent radiographic results in 57% and good results in 35% [6]. Galpin et al. reported a series of 33 dislocated hips in patients older than two years of age who were treated with a one-stage open reduction, femoral shortening, and pelvic osteotomy. They found satisfactory results clinically in 85% of hips and radiographically in 75% [7]. Nakamura et al. reported long term results after one-stage treatment in children with an average age of 2 years and 1 month. They found satisfactory results clinically in 73% and radiographically in 45% [8]. El-Sayed reported on 55 children (71 hips) with neglected DDH who had a one-stage combined operation between the ages of 2 and 4. They found satisfactory results clinically in 87% and radiographically in 83% [9].

Avascular necrosis of the femoral head is still a serious complication in treatment of DDH. Femoral head AVN does not occur in untreated hips. Therefore, there is no doubt that it is an iatrogenic complication [10].

Conclusion

- Late presentation of DDH is still common in Saudi Arabia, which necessitates more complex management and more frequent occurrences of unfavorable results.
- The overall results of either closed or open reduction was good.
- Early discovery of DDH is essential for successful treatment
- Developmental hip dysplasia is a major Dilemma if neglected
- The early the management the best will be the result regarding hip function and growth of the joint
- Skin traction we consider its effectiveness and aid for successful reduction
- Reduction of the hip should be with ease in order to reduce the risk of avascular necrosis otherwise femoral shortening is indicated
- The need for salter osteotomy is less frequent

References

1. Tredwell SJ (1992) Neonatal screening for hip joint instability. Its clinical and economic relevance. *Clin Orthop Relat Res* 281: 63-8.
2. Iqbal J (2009) Congenital Dislocation of the Hip. *Nishtar Medical Journal* 1: 4.
3. Bache CE, Clegg J, Herron M (2002) Risk factors for developmental dysplasia of the hip in the neonatal period. *J Pediatr Orthop B* 11: 212-21.
4. Bhaskar A (2011) Developmental Dysplasia of the Hip Joint (DDH) Diagnosis and Management. *Ortho front* : 34-7.
5. Brdar R, Petronic I, Nikolic D, Lukac M, Cirovicet D, et al. (2013) Walking quality after surgical treatment of developmental dysplasia of the hip in children. *Acta Orthop Belg* 79: 60-63.
6. Berkeley ME, Dickson JH, Cain TE, Donovan MM (1984) Surgical therapy for congenital dislocation of the hip in patients who are twelve to thirty-six months old. *J Bone Joint Surg* 66: 412-420.
7. Galpin RD, Roach JW, Wenger DR, Herring JA, Birch JG (1989) One-stage treatment of congenital dislocation of the hip in older children, including femoral shortening. *J Bone Joint Surg* 71: 734-741.
8. Nakamura M, Matsunaga S, Yoshino S, Toshiyukia O, Masarub H, et al (2004) Long-term result of combination of open reduction and femoral derotation varus osteotomy with shortening for developmental dislocation of the hip. *J Pediatr Orthop* 13: 248-253.
9. El-Sayed MM (2009) Single-stage open reduction, Salter innominate osteotomy, and proximal femoral osteotomy for the management of developmental dysplasia of the hip in children between the ages of 2 and 4 years. *J Pediatr Orthop* 18: 188-196.
10. Aksoy MC (2007) Closed reduction in the treatment of developmental dysplasia of the hip. *Acta Orthop Traumatol Turc* 41: 25-30.