

Transvesicoscopic Repair of Vesicovaginal Fistula: Short Term Follow-Up

Ajay Kumar Guntaka*, Rajendra Nerli, Mallikarjuna Reddy and Hiremath MB

Kles Kidney Foundation, Kle University's Jn Medical College, Belgaum, Karnataka, India

Abstract

Introduction: We report our series of patients with VVF treated by transvesicoscopic approach. We analyzed the outcome of this repair in women of reproductive age group.

Materials and methods: Patients of reproductive age group with VVF formed the study group. Only single fistulas which were <10 mm in diameter and situated in the supratrigonal region were included. Patients were randomized to undergo either laparoscopic transperitoneal or transvesicoscopic repair.

Results: During the study period Jan 2009 to Dec 2012, 15 women underwent laparoscopic repair of VVF. Eight of these women underwent laparoscopic transperitoneal repair, whereas the remaining seven underwent transvesicoscopic repair.

Conclusions: Transvesicoscopic as well as laparoscopic transperitoneal repair of VVF carries all the advantages of laparoscopy including minimal invasiveness, less morbidity, shorter hospital stay, early recovery, and better cosmetic appearance. Women in the reproductive age group return to early sexual activity and have a decreased incidence of urinary voiding dysfunction at 6 months follow-up.

Keywords: Vesicovaginal fistula; Urinary tract; Transvesicoscopic repair

Introduction

Vesicovaginal Fistulae (VVF) is the most common acquired fistula of the urinary tract and has been known since ancient times [1]. The physical and psychological impact of constant urinary leakage from a VVF can be overwhelming due to the burden of continual wetness, undesirable odor, vaginal and bladder infections and their related discomfort. The goal of treatment of VVF is the rapid cessation of urinary leakage with return of normal and complete urinary and genital function [1]. Traditionally VVF have been repaired either through a transvaginal or transabdominal (transvesical) approach. Each approach has its own merits depending on the particular circumstances of the fistula, and is associated with excellent outcomes.

Minimally invasive surgical techniques have gradually been introduced in the management of VVF and today they offer an alternative to the classical open approach. Compared with the O'Conor trans abdominal approach, laparoscopic repair is reported to be associated with less surgical trauma, shorter convalescence, and lower morbidity [2-4]. Laparoscopic VVF repair would appear more useful and convenient in certain scenarios such as in the setting of a high VVF in which a vaginal operation would be anatomically challenging. Nerli and Reddy [4] reported on the feasibility, safety and effectiveness of the transvesicoscopic approach. This approach had the additional advantage of not needing to enter the peritoneal cavity. Melamud et al. [5] were the first to report on successful robotic VVF repair in 2005, and since then several small case series have been subsequently reported [6,7]. Advantages to the robotic technique include three-dimensional visualization, wristed instrumentation reducing the severe angulation required for laparoscopic VVF repair, and technically simpler intracorporeal knot tying.

We report our series of patients with VVF treated by transvesicoscopic approach. We analyzed the outcome of this repair in women of reproductive age group (Figure 1).

Materials and Methods

Patients of reproductive age group with VVF formed the study group. A detailed history was noted and examination was done in all

patients. A three-swab test was done to confirm the clinical suspicion. A routine ultrasonography of kidney, ureters, and bladder region was done in all. Imaging studies included Cystograms and Intravenous urogram. Magnetic resonance imaging was done whenever felt necessary and appropriate. Cystoscopy was done to identify the fistula and note its size, position, and surroundings. At the same instance vaginoscopy was done to observe the other end of the fistula. The inclusion criteria included patients in the reproductive age group, who were sexually active prior to the occurrence of VVF. Women with a history of malignancy or having undergone surgery/radiation for malignancy previously were excluded from the study. Only single fistulas which

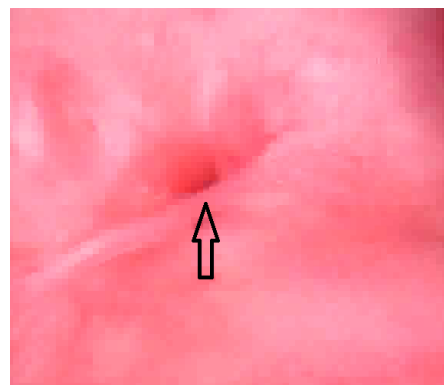


Figure 1: Cystoscopy showing 8 mm vesicovaginal fistula.

*Corresponding author: Ajay Kumar Guntaka, KLES Kidney Foundation, Department of Urology, Kle University's JN Medical College, Belgaum-590010, Karnataka, India, Tel: 91-0831-24737; E-mail: drajay707@gmail.com

Received March 10, 2014; Accepted March 30, 2014; Published April 05, 2014

Citation: Guntaka AK, Nerli R, Mallikarjuna Reddy, Hiremath MB (2014) Transvesicoscopic Repair of Vesicovaginal Fistula: Short Term Follow-Up. J Women's Health Care 3: 156. doi:10.4172/2167-0420.1000156

Copyright: © 2014 Guntaka AK, et al. This is an open-access article distributed under the terms of the Creative Commons Attribution License, which permits unrestricted use, distribution, and reproduction in any medium, provided the original author and source are credited.

were <10 mm in diameter and situated in the supratriangular region were included. Patients were randomized to undergo either laparoscopic transperitoneal or transvesicoscopic repair, *Surgical Technique of transvesicoscopic repair*. The patient was placed in modified lithotomy position. An initial cystoscopy was performed using insufflation of gas and the fistula inspected in detail. The bladder was fixed to the anterior abdominal wall under cystoscopic guidance. The bladder was fixed using 1/0 prolene and placed by using a technique of looping the suture material into the bladder with the help of a spinal needle and then hooking it with the same suture through a neighboring site.

A 5 mm endoscopic port was placed into the bladder under cystoscopic guidance in the midline, halfway between the umbilicus and pubic symphysis. Two more working/instrument ports were placed 5cm laterally and inferior to the endoscopic port on either side. Once the ports were in place the cystoscope was withdrawn and the urethra catheterised. The vagina was packed with betadine packs so as to prevent gas leak. The fistula was once again inspected. A circum-fistula incision was made and the bladder dissected away from the underlying vagina. The edges of the fistula were excised. Once adequate dissection was achieved, the vagina was sutured vertically and the bladder edges sutured horizontally. The bladder was closed using 4/0 vicryl. The two ureteric orifices were catheterised using 5F infant feeding tubes and brought outside the bladder for drainage. The bladder was also catheterised. The infant feeding tubes were removed after one week and the catheter removed after two weeks.

All patients underwent three-swab test, on table cystograms and cystoscopy in the follow-up period. All patients were reassessed six months after surgery. They all were requested to answer a questionnaire related to their act of micturition, satisfaction with the outcome of their surgery, and sexual performance.

Results

During the study period Jan 2009 to Dec 2012, 15 women underwent laparoscopic repair of VVF. The cause of VVF was post hysterectomy in all the 15 women. Eight of these women underwent laparoscopic transperitoneal repair, whereas the remaining seven underwent transvesicoscopic repair. The characteristics of the patients are as shown in table 1.

Outcome assessed by questionnaire at the end of 6 months following surgery included voiding symptoms, urinary incontinence and sexual activity. Clinical data of women of similar parameters but who had undergone open repair of VVF in the past 5 years was used for comparison. The results of the same were as shown in table 2.

Discussion

VVFs that result from operative injury can be repaired with a success rate of 75-97%. A failure rate of 10% has been reported with recurrent fistulas [2,8,9]. Controversy still exists over the timing, ideal surgical approach and need for adjuvant measures. Laparoscopic VVF repair attempts to achieve success rates similar to those of transabdominal repair and avoids the morbidity of open surgery [10]. The advantages of a minimally invasive procedure include magnification during the procedure, hemostasis, decreased abdominal pain and a shorter hospital stay with quicker recovery and early return to work. In addition to providing excellent exposure, the laparoscopic approach allows easy mobilization of the omentum for interposition. Laparoscopic VVF repair adheres to the principles of transabdominal VVF repair while decreasing morbidity and improving cosmesis. Laparoscopic VVF repair is a feasible and efficacious approach with a

successful outcome in a majority of the patients. However laparoscopic forehead intracorporeal suturing can be a challenging task [10,11].

Porpiglia et al. [12] reported their experience with laparoscopic transperitoneal repair of VVF in four patients. Mean operative time was 103 minutes and no complications were recorded. Average length of hospital stay was 3 days, Foley catheter remained indwelling on an average of 8 days. All patients were cured, after a mean of 14.5 months no recurrence was recorded and no patient referred urinary symptoms. They concluded that laparoscopic VVF repair was feasible, safe and effective and it was a viable alternative to the traditional open procedure. Similarly Ou et al. [13] described a methodology for laparoscopic repair of vesicovaginal fistula and compared with open repairs. A total of 16 patients were diagnosed with post-hysterectomy VVF. All patients were first managed conservatively with continuous drainage via a Foley catheter until dry. In 2 of the 16 cases (12.5%) the fistulae healed spontaneously with conservative management. After 4-12 weeks, the remaining 14 patients underwent surgical repair of their fistulas; 2 (14%) by laparoscopy, 6 (43%) by Trans-Abdominal Open Repair (TAOR), and 6 (43%) by Trans-Vaginal Repair (TVR). Fistula repair was successful in laparoscopy cases, all 6 TAOR cases, and 5 of 6 TVR cases (86%). They concluded that laparoscopic VVF repair was feasible and resulted in lower morbidity, shorter hospital stay, and quicker recovery than the abdominal or transvaginal approaches. Nerli et al. [14] reported on 24 women with VVF, of which 19 underwent laparoscopic transperitoneal repair, whereas 5 underwent laparoscopic transvesicoscopic repair. No major complications were noted and the entire fistula healed well. They opined that minimally invasive approaches to repair VVF was feasible, safe and associated with minimal morbidity.

Flynn et al. [15] assessed the post-operative sexual and urinary function of 40 consecutive subjects undergoing vaginal cuff scar excision for VVF. Post-operatively, 100% of subjects were evaluated at 3 weeks when the suprapubic catheter was removed and 93% were

	Laparoscopic transperitoneal repair	Transvesicoscopic repair	p value
No of Patients	8	7	
Age	42.75 ± 1.83	43.28 ± 1.97	0.000
Operating time	169	186	0.05
Success rate	100%	100%	
Intraoperative complications	Nil	Nil	

Table 1: Characteristics of the Patients.

	Laparoscopic Transperitoneal repair	Transvesicoscopic repair	Open VVF repair
No of patients	8	7	10
Voiding dysfunction			
Stress Incontinence	-	-	1 (10%)
Urge Incontinence	-	-	3 (30%)
Mixed Incontinence	-	-	1 (10%)
Frequency, Urgency			4 (40%)
Sexual activity after 12 weeks	100%	100%	2 (20%)
Sexual activity 12 – 24 weeks	-	-	5 (50%)
No sexual activity	-	-	50%
Dyspareunia	2 (25%)		50%

Table 2: Clinical data of women who had undergone open repair of VVF in the past 5 years.

evaluated at 3 months or later. All subjects were cured of their fistulae at last contact. At 3 months postoperatively, 94% denied any urinary dysfunction and 85% had resumed sexual intercourse. Two sexually active subjects reported mild deep dyspareunia. Kapoor et al. [16] presented their experience in 52 patients for the repair of VVF. Three patients failed repair giving a success rate of 94.2%. At a mean follow-up of three years 48 women were sexually active, of these 10 (19.2%) complained of mild to moderate dyspareunia. Umoyioho et al. [17] studied the effect of successful VVF repair on affected women's quality of life. Of the 150 women studied, 90% felt satisfied with their general state of health and quality of life following successful repair.

Our study has shown that women in reproductive age group return to sexual function within 12 weeks following successful laparoscopic/vesicoscopic repair of VVF. This could probably be due to decreased morbidity associated with minimally invasive techniques. This could also explain decreased voiding dysfunctions/symptoms associated with open surgical techniques. It could be possible that open surgery may involve damage to nerves, as well as shortening of the vagina. Komesu et al. [18] studied the effect of posterior repair on sexual function. They opined that the positive effect of surgery on incontinence and prolapse may overshadow the smaller, potentially detrimental effects of repair on sexual function (Figure 2- 4).

Conclusions

Transvesicoscopic as well as laparoscopic transperitoneal repair of VVF carries all the advantages of laparoscopy including minimal invasiveness, less morbidity, shorter hospital stay, early recovery, and better cosmetic appearance. Women in the reproductive age group return to early sexual activity and have a decreased incidence of urinary voiding dysfunction at 6 months follow-up.

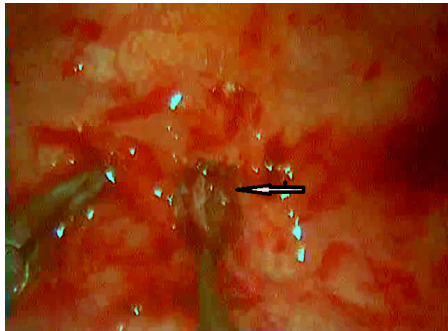


Figure 2: Transvesicoscopic view showing the vesicovaginal fistula.

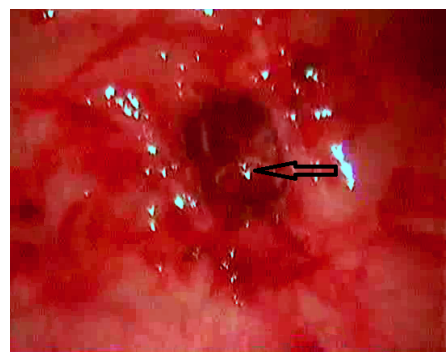


Figure 3: Transvesicoscopic view showing closure of the vagina.

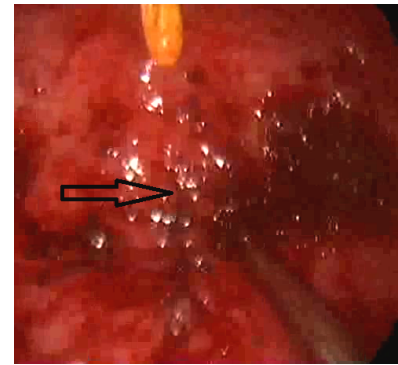


Figure 4: Transvesicoscopic view showing closure of the bladder.

References

1. Rovner ES (2012) Urinary Tract Fistulae. In: Wein AJ (Edr.) Campbell-Walsh Urology. (10th Edn.), Saunders-Elsevier, Philadelphia, p: 2223.
2. von Theobald P, Hamel P, Febbraro W (1998) Laparoscopic repair of a vesicovaginal fistula using an omental J flap. Br J Obstet Gynaecol 105: 1216-1218.
3. Ou CS, Huang UC, Tsuang M, Rowbotham R (2004) Laparoscopic repair of vesicovaginal fistula. J Laparoendosc Adv Surg Tech A 14: 17-21.
4. Nerli RB, Reddy M (2010) Transvesicoscopic repair of vesicovaginal fistula. Diagn Ther Endosc 2010: 760348.
5. Melamud O, Eichel L, Turbow B, Shanberg A (2005) Laparoscopic vesicovaginal fistula repair with robotic reconstruction. Urology 65: 163-166.
6. Sundaram BM, Kalidasan G, Hemal AK (2006) Robotic repair of vesicovaginal fistula: case series of five patients. Urology 67: 970-973.
7. Hemal AK, Eun D, Tewari A, Menon M (2004) Nuances in the optimum placement of ports in pelvic and upper urinary tract surgery using the da Vinci robot. Urol Clin North Am 31: 683-692, viii.
8. Hilton P (2001) Vesico-vaginal fistula: new perspectives. Curr Opin Obstet Gynecol 13: 513-520.
9. Hilton P, Ward A (1998) Epidemiological and surgical aspects of urogenital fistulae: a review of 25 years' experience in southeast Nigeria. Int Urogynecol J Pelvic Floor Dysfunct 9: 189-194.
10. Modi P, Goel R, Dodia S (2006) Laparoscopic repair of vesicovaginal fistula. Urol Int 76: 374-376.
11. Kumar S, Kekre NS, Gopalakrishnan G (2007) Vesicovaginal fistula: An update. Indian J Urol 23: 187-191.
12. Porpiglia F, Fiori C, Morra I, Ragni F, Vaccino D, et al. (2009) Laparoscopic vesico-vaginal fistula repair: our experience and review of the literature. Surg Laparosc Endosc Percutan Tech 19: 410-414.
13. Ou CS, Huang UC, Tsuang M, Rowbotham R (2004) Laparoscopic repair of vesicovaginal fistula. J Laparoendosc Adv Surg Tech A 14: 17-21.
14. Nerli RB, Reddy MN, Shishir D, Hiremath MB (2010) Laparoscopic approach to vesicovaginal fistula : our experience . Recent Res Sci Technol 2: 35-38.
15. Flynn MK, Peterson AC, Amundsen CL, Webster GD (2004) Functional outcomes of primary and secondary repairs of vesicovaginal fistulae via vaginal cuff scar excision. Int Urogynecol J Pelvic Floor Dysfunct 15: 394-398.
16. Kapoor R, Ansari MS, Singh P, Gupta P, Khurana N, et al. (2007) Management of vesicovaginal fistula: An experience of 52 cases with a rationalized algorithm for choosing the transvaginal or transabdominal approach. Indian J Urol 23: 372-376.
17. Umoyioho AJ, Inyang-Etoh EC, Abah GM, Abasiattai AM, Akaiso OE (2011) Quality of life following successful repair of vesicovaginal fistula in Nigeria. Rural Remote Health 11: 1734.
18. Komesu YM, Rogers RG, Kammerer-Doak DN, Barber MD, Olsen AL (2007) Posterior repair and sexual function. Am J Obstet Gynecol 197: 101.