

Transient Complete Atrioventricular Block Resulted from Cardiac Anaphylaxis Caused by Sugammadex

Motoyo Iwade*, Asami Ohashi, Miyabi Kamiya and Makoto Ozaki

Department of Anesthesiology, Tokyo Women's Medical University School of Medicine, Tokyo, Japan

Abstract

The present report describes an elderly man undergoing surgery who subsequently developed complete atrioventricular block following sugammadex administration. Cardiac anaphylaxis due to sugammadex was considered to be the most likely cause. The onset of anaphylaxis may trigger severe heart block, attributable to the direct actions on the heart of chemical mediators.

Keywords: Anaphylaxis; Sugammadex; Atrioventricular block; Cardiac arrest

Abbreviations: AVB: Atrio Ventricular Block; ECG: Electro Cardio Gram

Introduction

There is substantial evidence that the heart is a primary target organ in anaphylactic reactions involving the release of chemical mediators. Sinus tachycardia, atrioventricular conduction block, increased ventricular automaticity and vasoconstriction of coronary vessels are characteristic features of cardiac anaphylaxis [1]. Among these features, coronary spasms are well known to be characteristic of anaphylactic angina; however, atrioventricular block (AVB) is not a widely recognized feature of cardiac anaphylaxis.

We describe an elderly man undergoing surgery who subsequently developed complete AVB following sugammadex administration. Cardiac anaphylaxis due to sugammadex was considered to be the most likely cause.

Case Presentation

Written informed consent was obtained from the patient's family for publication of this Case report and any accompanying images.

A 78-year-old man was admitted to undergo thoracic endovascular aortic repair for an aneurysm of the distal portion of a thoracic aortic graft. He had a history of general anesthesia for grafting of the thoracic descending aorta, coronary artery bypass grafting and sigmoid colon resection. All of these operations had been performed before sugammadex became available for use in Japan. He also had hypertension and chronic atrial fibrillation. His baseline medications were cilnidipine, eplerenone, olmesartan, atorvastatin and warfarin. He had no known drug allergies. Preoperative electrocardiogram (ECG) showed atrial fibrillation and right bundle branch block with normal axis deviation. Preoperative echocardiography showed normal left ventricular function (fractional shortening was 0.27) and Holter ECG showed no arrhythmias other than atrial fibrillation (heart rate: 54–92 beat/minute) and monofocal premature ventricular contractions (35 beat/day). He had no symptoms of angina, and no new significant coronary artery stenosis after a coronary artery bypass graft procedure. Laboratory investigations confirmed mild anemia and mild renal dysfunction. Warfarin was stopped 3 days before the operation, and other baseline medication was not administered on the day of surgery.

General anesthesia was induced with administration of 3 mg of midazolam, 0.3 µg/kg/min continuous infusion of remifentanyl, followed by 0.6 mg/kg of rocuronium to facilitate intubation. After tracheal intubation, anesthesia was maintained using sevoflurane

and remifentanyl. Ampicillin was administered before the start of the operation, while heparin and protamine were administered intraoperatively. Ten milligrams of rocuronium were added once intraoperatively.

The operation was completed uneventfully in 2.5 hours. Postoperatively, after recovery of the train of four ratio, a 2 mg/kg dose of sugammadex was administered by slow intravenous injection. Two minutes later, sudden cardiac arrest occurred. Cardiac resuscitation was immediately initiated with chest compression and administration of 0.5 mg of epinephrine and 0.5 mg of atropine. He quickly recovered, within 1 minute, to the sinus rhythm. Then, the skin of his trunk and thighs showed erythema. Anaphylaxis caused by sugammadex was highly suspected. The patient was again sedated with a 3 mg dose of midazolam and received a continuous 0.03 µg/kg/min infusion of epinephrine to maintain systolic blood pressure above 80 mmHg. Transthoracic echocardiography, chest X-ray and 12-lead ECG which were taken several minutes after recovery from cardiac arrest, showed no significant change compared to the preoperative. Arterial blood gas analysis and blood sugar values showed no significant abnormalities. The patient was transferred to the intensive care unit. Eight hours later, his erythema was almost disappeared. Continuous infusion of epinephrine was stopped and he was extubated uneventfully.

The ECG monitor in the operating room during cardiac arrest showed small f waves and no QRS waves (Figure 1). Therefore, complete AVB had apparently occurred suddenly after sugammadex administration. Postoperatively, MB-CPK was not increased, nor did Holter ECG reveal heart block. The patient was discharged from the hospital 9 days later without problems. Skin testing was planned more than 4 weeks after this episode, but the patient unfortunately died due to a ruptured aneurysm before these skin tests could be performed.

Discussion

The present patient was considered to have transient complete AVB during anaphylaxis triggered by sugammadex administration. Because

***Corresponding author:** Motoyo Iwade, Department of Anesthesiology, Tokyo Women's Medical University School of Medicine, 8-1 Kawatacho Shinjuku Tokyo 162-8666, Japan, Tel: +81-3-3353-8111; Fax: 81-3-5269-7331; E-mail: miwade@mrj.biglobe.ne.jp

Received June 27, 2018; **Accepted** July 10, 2018; **Published** July 17, 2018

Citation: Iwade M, Ohashi A, Kamiya M, Ozaki M (2018) Transient Complete Atrioventricular Block Resulted from Cardiac Anaphylaxis Caused by Sugammadex. Emergency Med 8: 370. doi:10.4172/2165-7548.1000370

Copyright: © 2018 Iwade M, et al. This is an open-access article distributed under the terms of the Creative Commons Attribution License, which permits unrestricted use, distribution, and reproduction in any medium, provided the original author and source are credited.

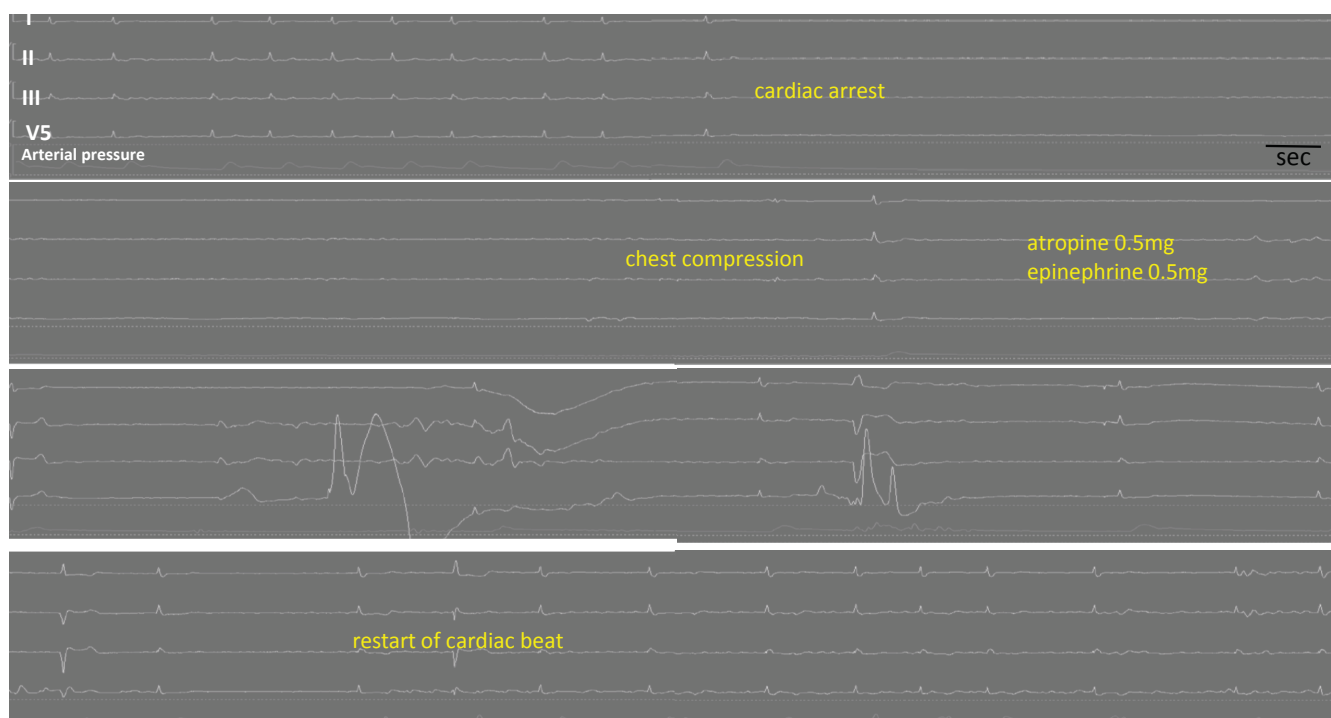


Figure 1: Electrocardiogram (ECG) during cardiac event 2 minutes after administration of sugammadex. Sudden cardiac arrest occurred. After cardiac resuscitation, the patient showed rapid circulatory recovery. ECG showed small f waves and no QRS waves. Complete AVB had occurred suddenly after sugammadex administration.

cardiovascular disturbance and skin erythema occurred immediately after sugammadex administration, these signs are the first evidence of anaphylaxis [2]. Although biochemical measurements and skin test was not done, anaphylaxis caused by sugammadex was suspected most from the clinical course. Anaphylaxis caused by a clinical dose of sugammadex has already been reported [3], but there are no reports of cases such as ours with complete AVB. Among symptoms and signs of cardiac anaphylaxis, there are few reports describing delay of atrioventricular conduction during anaphylaxis [4], and this feature of cardiac anaphylaxis is not widely recognized.

Since our patient had a history of major vascular surgery and coronary artery bypass grafting, the perioperative risk for cardiac events might have been high as compared to patients with no past history of cardiovascular disease. However, coronary event was denied from postoperative ECG, value of MB-CK and echocardiography. It was not found atrioventricular block in the holter ECG pre- and postoperatively. However, whether the occurrence of AVB, as a feature of cardiac anaphylaxis, was related to patient-specific risk remains uncertain.

On the other hand, sugammadex itself also might have the possibility of change of the tonus of the autonomic nervous system. Neuromuscular relaxants may have bound to muscarinic receptors in the atria, bronchial smooth muscle and parasympathetic nerves in the lung. Rocuronium has also been reported to have affinities for these muscarinic receptors, and its affinities are lower than those of pancuronium, such that binding does not occur in the range of concentrations achieved with clinical use [5]. Rocuronium has been reported to block nicotinic acetylcholine receptors at the superior cervical ganglia of rats [6], and it has thus been suggested that the effects of rocuronium on the autonomic nervous system cannot be assumed to be negligible. Therefore, when rocuronium disappears rapidly following the administration of sugammadex, it is no wonder

that sympathetic or parasympathetic hyperactivity might occur as a reaction. If parasympathetic hyperactivity occurs, severe heart block, as in our present case, may occur. However, this is speculative at present, and it is also unknown whether the impact in this case.

Furthermore, in our present case, since skin erythema developed after the recovery of circulation, a hypersensitivity reaction was strongly suspected.

Conclusion

Our complete AVB immediately after the administration of sugammadex was considered to have been caused by direct actions of chemical mediators on the heart in a process of anaphylactic reaction.

Conflict of Interest Statements

The authors declare that they have no competing interests.

Authors' Contributions

MI, AO and MN provided the anaesthetic care. ST collected the patient's data. MI, AO and MN drafted the manuscript. MO helped to draft the manuscript and revised it critically. All authors read and approved the final manuscript.

Acknowledgements

None.

References

1. Heller LJ, Regal JF (1988) Effect of adenosine on histamine release and atrioventricular conduction during guinea pig cardiac anaphylaxis. *Circ Res* 62: 1147-1158.
2. Dewachter P, Mouton-Fivre C, Emala CW (2009) Anaphylaxis and Anesthesia: Controversies and new insights. *Anesthesiology* 111: 1141-1150.
3. Menendez-Ozcoidi L, Oritiz-Gomez JR, Olanguibel-Ribero JM, Salvador-Bravo MJ (2011) Allergy to low dose sugammadex. *Anesthesia* 66: 217-219.
4. Mohamed A, Andrade J, Bayliss M, Wong GC (2008) Transient 2:1

-
- atrioventricular block following anaphylactic reaction to low-ionic strength computed tomography contrast agent. *Can J Cardiol* 24: e96-e98.
5. Hou VY, Hirshman CA, Emala CW (1998) Neuromuscular relaxants as antagonists for M2 and M3 muscarinic receptors. *Anesthesiology* 88: 744-750.
 6. Zhang C, Wang Z, Zhang J, Qiu H, Sun Y, et al. (2014) Competitive inhibition of the nondepolarizing muscle relaxant rocuronium on nicotinic acetylcholine receptor channels in the rat superior cervical ganglia. *J Cardiovasc Pharmacol* 63: 428-433.