

Case Report

Open Access

# Tracheo-Esophageal Continuous Positive Airway Pressure (CPAP)?

Sahin Takci\* and Murat Y

Hacettepe University Ihsan Dogramaci Childrens' Hospital, Neonatology Unit, Ankara, Turkey

## Abstract

We present an infant diagnosed with type IV laryngeal-tracheal-esophageal cleft. Instead of the lacking naso-pharyngeal continuous positive airway pressure treatment (CPAP), tracheo-esophageal CPAP was effectively performed for respiratory distress.

**Keywords:** Continuous positive airway pressure; Laryngeal-tracheal-esophageal cleft; Neonate

## Tracheo-Esophageal Continuous Positive Airway Pressure (CPAP)?

A 2340 g female infant was born at 36 weeks gestation to a healthy mother by caesarean section at Hacettepe University in Ankara. In prenatal ultrasound examination polyhydramnios was present and gastric bubble could not be identified. The Apgar scores were 6 and 7 at 1 and 5 minutes respectively. Positive pressure ventilation was performed in the delivery room. The chest radiograph showed presence of gastric gas and the orogastric tube placed at the level of gastric bubble. The infant was placed on a naso-pharyngeal CPAP (NPCPAP) for respiratory distress. On the second day of life endotracheal intubation was required for respiratory acidosis and hypoxia. The infant followed in conventional mechanical ventilation with low positive inspiratory and end-expiratory pressure. During intubation epiglottis and vocal cords could not be identified and only esophagus was seen. The

endoscopy demonstrated a type IV laryngeal-tracheal-esophageal cleft (LTEC) ending just above the carina. On day 4, the infant extubated and managed with NPCPAP with 7 cm H<sub>2</sub>O pressure. On the following day the infant could not tolerate NPCPAP. It was decided to try tracheo-esophageal CPAP with 5 cm H<sub>2</sub>O in this case (Figure 1). Tracheo-esophageal CPAP was clinically effective and well tolerated until the corrective surgery.

The optimum CPAP method and pressure for infants with various anomalies such as LTEC and lung disease remains uncertain. The choice of CPAP methods differs between centers depending on birth weight, cost effectiveness, adverse effects and many other conditions [1]. Difficulties of application, difficulties of setting right pressure limits and special circumstances like nasal septum erosions forces investigators to find new CPAP methods. Carlisle et al. [2] reported oral CPAP delivery in an extremely premature infant with severe nasal septum erosion.

It is known that the pressure decreases in the lower airway system because of the total airway resistance which is transmitted from the CPAP system [3]. In our case firstly naso-pharyngeal tube was established for delivering CPAP because of being safe, easy and cheap method. However we could not maintain respiratory stability by the reason of LTEC. Low CPAP pressure (5 cm H<sub>2</sub>O) was sufficient to maintain respiratory stability after performing tracheo-esophageal CPAP. Infants' condition and individualized treatment must be considered when choosing the ideal CPAP method.

## References

1. Diblasi RM (2009) Nasal continuous positive airway pressure (CPAP) for the respiratory care of the newborn infant. *Respir Care* 54: 1209-35.
2. Carlisle HR, Kamlin CO, Owen LS, Davis PG, Morley CJ (2010) Oral continuous positive airway pressure (CPAP) following nasal injury in a preterm infant. *Arch Dis Child Fetal Neonatal* Ed 95: 142-3.
3. De Paoli AG, Lau R, Davis PG, Morley CJ (2005) Pharyngeal pressure in preterm infants receiving nasal continuous positive airway pressure. *Arch Dis Child Fetal Neonatal* Ed. 90: F79-81.

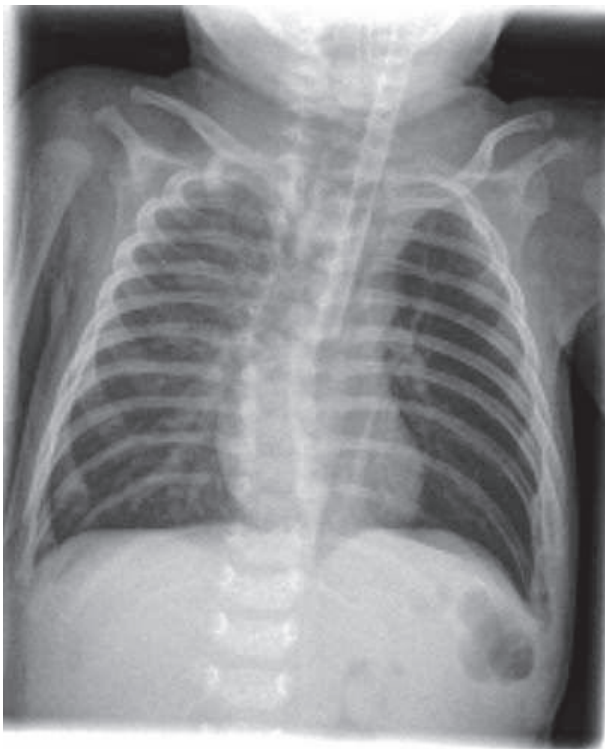


Figure 1: Plain chest X-ray showing tracheo-esophageally settled CPAP tube.

\*Corresponding author: Sahin Takci, Hacettepe University Ihsan Dogramaci Childrens' Hospital, Neonatology Unit 06100, Ankara, Turkey, Tel: 90 312 305 1390, Fax: 90 312 310 5509, E-mail: [stakci@gmail.com](mailto:stakci@gmail.com)

Received April 30, 2013; Accepted May 10, 2013; Published May 14, 2013

**Citation:** Takci S, Murat Y (2013) Tracheo-Esophageal Continuous Positive Airway Pressure (CPAP)? *J Med Diagn Meth* 2: 110. doi:10.4172/2168-9784.1000110

**Copyright:** © 2013 Takci S, et al. This is an open-access article distributed under the terms of the Creative Commons Attribution License, which permits unrestricted use, distribution, and reproduction in any medium, provided the original author and source are credited.