

## Total Hip Replacement after Failed Internal Fixation of Trochanteric Femoral Fractures

Yousuf Mohammad Khira\*

Faculty of Medicine, Orthopedic Surgery Department, Zagazig University, Egypt

\*Corresponding author: Yousuf Mohammad Khira, Faculty of Medicine, Orthopedic Surgery Department, Zagazig University, Egypt, Tel: 20-553668921; E-mail: [yousufmmkh@gmail.com](mailto:yousufmmkh@gmail.com)

Received date: June 06, 2016; Accepted date: June 30, 2016; Published date: July 07, 2016

Copyright: © 2016 Khira YM. This is an open-access article distributed under the terms of the Creative Commons Attribution License, which permits unrestricted use, distribution and reproduction in any medium, provided the original author and source are credited.

### Abstract

**Background:** Failure of fixation of trochanteric fractures of the femur results in great disability and pain. Hip arthroplasty is a helpful reconstructive procedure in patients with poor bone stock, avascular necrosis of the femoral head, associated with damaged acetabular articular cartilage.

**Objective:** This prospective study is to evaluate clinically and radiologically, the early results of total hip arthroplasty in a group of patients with failed internal fixation of trochanteric femoral fractures.

**Patients and Methods:** Total hip replacement was done for fifty patients with failed treatment of proximal femoral fractures, only forty two patients 29 males and 13 females completed the follow up and eight were lost. The procedure was carried out through a lateral exposure in all cases. Harris Hip Score (HHS) was used for clinical evaluation preoperatively, postoperatively. Radiographic evaluation comprising anteroposterior radiographic views of the pelvis and femur and a lateral view of the femur were performed at follow-up visits.

**Results:** The mean time of follow up was 42 months (range from 30-72 months). The mean Harris Hip Score was improved from a mean of 24 points preoperative to 88 points at final follow up. Pain relief and gait correction were noted at the final follow up. Thirty patients (72%) could freely walk outdoors using a cane or elbow crutch; eight patients (19%) had a limited walking ability using two axillary crutches, and four patients (9%) were able to walk indoors only.

**Conclusion:** Total hip arthroplasty is an accepted procedure after failed internal fixation of trochanteric femoral fractures. Individualization of the implant selection according to patient age, level of activity, the bone stock of proximal femur, and the condition of the acetabulum.

**Keywords:** Total hip; Replacement; Trochanteric fracture; Failure of fixation

### Introduction

Stable trochanteric femoral fractures can be treated by internal fixation methods with union rates as high as 100% when optimal implant and good reduction have been achieved. Failure rates have been reported in literature due to comminution, osteoporosis and suboptimal fixation [1]. Functional disability and pain are the end result of failed fixation of trochanteric femoral fractures. Failure rates may be due to failure of the device (3-12%); device penetration in (2% and 12%), nonunion (2-5%) and malunion with varus deformity in (5-11%). Certain unstable fracture patterns have been reported to have failure rates as high as 56% [2-6]. Revision of internal fixation for nonunited trochanteric fractures of the femur has been reported to have good results in younger patients with good bone stock [6-10].

Total hip arthroplasty is considered as a salvage procedure for older patients, patients with poor bone stock, avascular necrosis of the femoral head, associated with damaged acetabular articular cartilage [7]. There are many technical difficulties during conversion hip

arthroplasty such as extraction of implants, bone deformity, bone loss, poor bone quality and associated trochanteric nonunion [11-13].

The purpose of this prospective study is to evaluate clinically and radiologically, the early results of total hip arthroplasty in a group of patients with failed internal fixation of trochanteric femoral fractures.

### Patients and methods

All patients included in this study have given informed written consent for participating in the research before operation.

This prospective study was conducted at Zagazig University Hospitals, after approval of our ethical committee for research in accordance with the ethical standards laid down in the 1964 declaration of Helsinki and its later amendments.

From January 2004 to December 2010, fifty patients with failed treatment of proximal femoral fractures were treated by total hip replacement as a salvage procedure. Only forty two patients available for this study and eight patients were lost during the period of follow up. The mean age of the patients was 52 years (range: 44-68 years) and the sex distribution was 29 males and 13 females (Table 1). The type of fracture was intertrochanteric in 30 patients and subtrochanteric in 12

patients. The implants used to treat these fractures primarily were: Dynamic Hip Screw in (DHS: 33 cases), proximal femoral nail in (PFN: 6 cases), dynamic condylar screw in (DCS: 3 cases). The mean time from primary fixation to the salvage arthroplasty was 22 months (range, 9 to 36 months).

Mean Age (range)	52 (44-68) years
Sex	Male: 29
	Female: 13
Side affected	Right: 17
	Left: 25
Implant in first operation	*DHS: 33
	**PFN:6
	***DCS: 3
Mean duration between first operation and salvage	22 (9-36) months
Type of prosthesis (fixation method)	Cement less: 32
	Cemented: 5
	Hybrid: 5
Stem used	Standard stem: 34
	Long stem: 8
Bearing surfaces	Metal on polyethylene : 42 cases
*(dynamic hip screw) **(proximal femoral nail) *** (dynamic condylar screw)	

**Table 1:** All patients data preoperative.

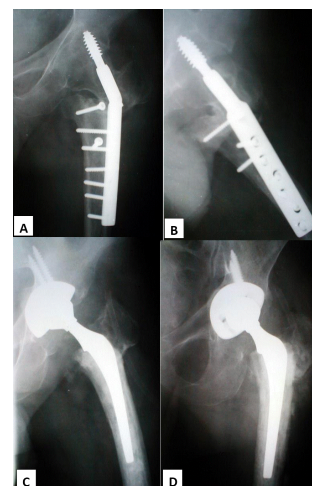
Intraoperative cultures did not grow organisms in thirty four patients and positive in 8 patients were operated on in two stages. One stage revision was done in 34 cases with aseptic failure (Figure 1A and 1B), and two stages in eight cases where infection was the cause of nonunion and implants failure (Figure 2A and 2B). The inclusion criteria of patients included in this study were either one or a combination of the following:

- Nonunion and or loss of fixation with avascular necrosis of the femoral head,
- Screw penetration of the acetabulum,
- Chondrolysis or hip incongruity.

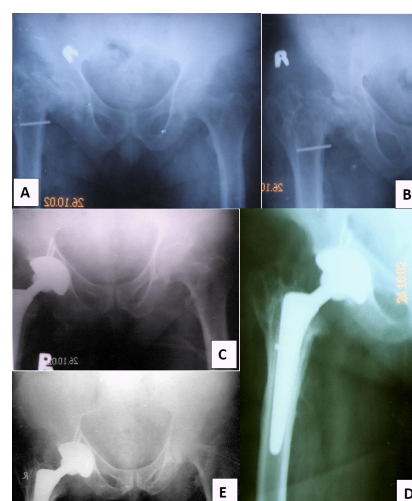
Patients with implant failure with normal acetabulum were excluded as bipolar prosthesis was done, also cases with active infection not done until debridement and cure of infection at least nine months after skin closure and no sinuses then second stage was done for them after laboratory investigations to ensure no microbial activity.

The selection of the implant type depended on patient age and bone quality with intraoperative evaluation according to bone stock after removal of implant. Hybrid prosthesis was used in 5 hips (Cementless cup and cemented stem) (Figure 1C and 1D), cementless prosthesis was used in 32 hips (Figure 2C,2D and 2E), and cemented prosthesis in 5 hips and (Figure 3A and 3B). A 28 mm metal head was used in all cases. In cemented stem the principle of Patterson et al. [14] was used

to avoid cement extrusion through the screw holes which may cause subsequent fracture through this stress riser.

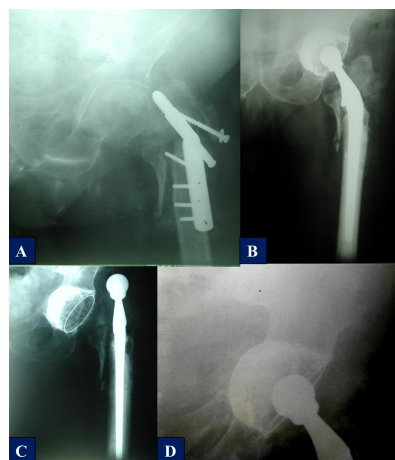


**Figure 1:** Female patient 62 years old (Case No. 12): A&B) preoperative X-ray with screw penetration and hip ankylosis; C&D) postoperative X-ray with hybrid THR (cementless cup and cemented stem).



**Figure 2:** Male patient 58 years old (Case No. 3): A&B) preoperative X-ray 9 months after metal extraction; C&D) postoperative X-ray (cementless THR); E) 2 years postoperative.

Harris Hip Score (HHS) [15] was used for clinical evaluation preoperatively, postoperatively and at last follow up. The score has a maximum of 100 points (best possible outcome) covering pain (1 item, 0-44 points), function (7 items, 0-47 points), absence of deformity (1item, 4points) and range of motion (2 items, 5points). The score of (90-100 points) HHS is excellent, good (80-90), fair (70-80), and poor (below 70 points) [16]. Limb length measurement. Preoperative clinical examination and, hematological investigations as complete blood count, Erythrocyte Sedimentation Rate (ESR) and C-Reactive Protein (CRP) were done for all patients regarding occult infections.



**Figure 3:** Male patient 68 years old (Case No. 18): A) preoperative X-ray with implant failure; B) postoperative X-ray with cemented THR; C) postoperative dislocation 3 weeks postoperative; D) X-ray after closed reduction.

Radiographic evaluation comprising anteroposterior radiographic views of the pelvis and femur and a lateral view of the femur were performed at follow-up visit. The femoral stems were evaluated using the system of Engh et al. [17]. The bone-prosthesis interface was evaluated for radiolucencies and recorded according to the zonal system described by Gruen et al. [18]. Acetabular evaluation was performed using the criteria described by DeLee and Charnley [19]. Acetabular inclination was measured using the interteardrop line as a reference point. Acetabular inclination between 35° and 55° was considered accepted. Cementless cup loosening was defined as implant migration, a complete radiolucent line at the implant bone interface, or fixation screws breakage [20]. Heterotopic ossification was graded according to the system described by Brooker et al. [21], and classes III and IV were considered clinically important.

### Operative procedure

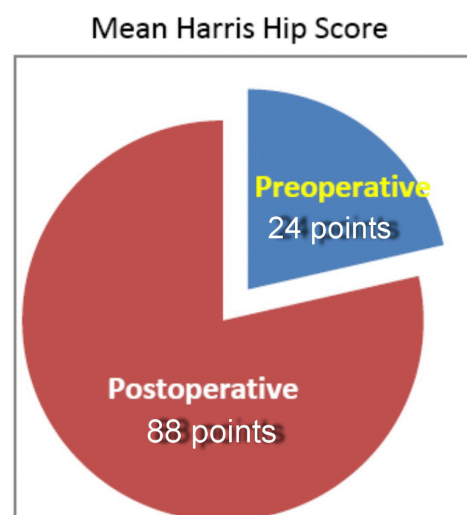
All operations were performed under spinal anesthesia. All patients were operated on by one mean surgeon in the same institution using Hardinage approach in lateral position. The skin incision included the previous scar in 10 patients and new incision not related to previous scar in 32 patients. The hip was dislocated before removing the implant to avoid intraoperative femoral shaft fracture, as the hip was quite stiff and the bone was of poor quality in 16 cases, complete removal of the implant before dislocation in 10 cases, and neck osteotomy in situ in 8 cases, and the implants were extracted in a previous sitting in 8 cases. Twelve patients were having nonunion of greater trochanter and stainless steel wire was used for reattachment after insertion of the stem; and eight patients had malunion of greater trochanter (five with valgus and three with varus deformity). And seven patients had screw cut out. Reaming of the femoral canal was difficult in most cases due to new bone formation, deformity of proximal femur and fibrosis. Initial drilling was formed using flexible reaming on a guide wire to ream the canal. Patients with intramedullary nails had great difficulty in canal reaming due to the old entry and bone sclerosing.

In all cases Image intensifier was prepared routinely. Stem selection for patients depended upon available bone quality and stability of trial

on table. Intraoperative fracture extension or new fracture occurred in 6 patients, in four cases calcar replacement stem was used, and plate fixation in two cases as the fracture was distal to the stem end. Prophylaxis for Deep Vein Thrombosis (DVT) using medical and mechanical methods was done for all patients. Clexane 40 units subcutaneous were used 24 hours preoperative and from second day through 3 weeks postoperative in all patients. Closure of the wound over suction drains which kept in situ for 2 days. Patients stay in hospital ranged from 8 to 17 days. After removal of stitches by 2 weeks regular monthly visits for six months, and every six months up to the end of follow up.

### Results

The mean time of follow up was 42 months (range from 30-72 months). The operative time ranged from 130 to 210 minutes (Average 150), with a mean blood loss of 1000 ml (range from 600 to 2000 ml). The minimum follow up period was 2.5 years (ranged from 2.5 to 6 years). Forty two patients only were available at the end of follow up as eight patients were lost during follow up. The mean preoperative Harris Hip Score (HHS) was 24 points with poor score in all patients, and improved significantly to a mean of 88 points (range: 75-96 points) at the latest follow up (Figure 4). At the end of follow up, eighteen patients had excellent results (43%); fourteen with good results (33.5%), eight hips (19%) with fair results and two hips (4.5%) had poor results. When comparing the mean HHS in cases with cemented stem (10 stems) and cases with cementless stem (32) there was no significant difference (Figure 5).

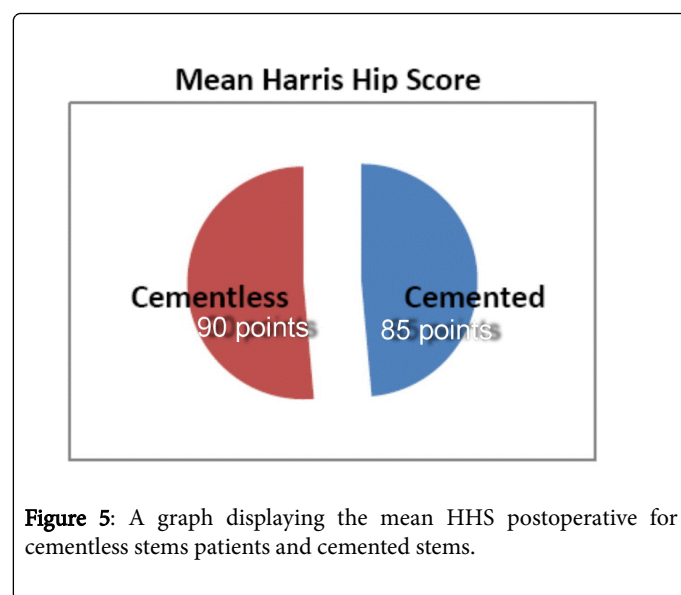


**Figure 4:** A graph displaying the mean HHS (Harris Hip Score) preoperative and postoperative.

Pain relief and gait correction were noted at the final follow up. Limb shortening was detected in 10 patients (23.8%) and ranged from 15 to 30 mm (average 22 mm). Preoperatively, twelve patients (28.6%) had moderate pain with using two crutches for ambulation; twenty one patients (50%) had severe pain and were unable to walk, and nine (21.4%) had limited walking ability using a walker. Postoperatively, no pain or residual mild pain which did not interfered with daily activities

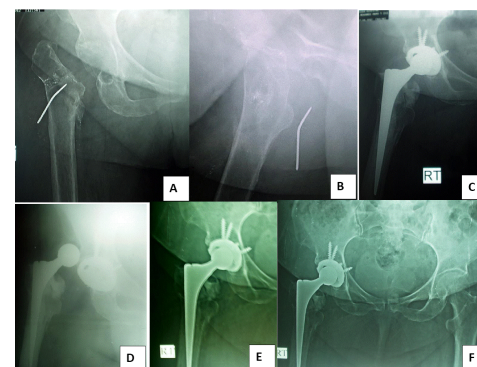


was found in 20 patients (47.6%), trochanteric pain in six (14.3%), and anterior thigh pain in 14 patients (33.3%). In two patients (4.8%) moderate to severe pain was found. Postoperative DVT proven by Doppler examination was found in three patients and were treated medically. All patients were able to walk with different walking ability. Thirty patients (72%) could freely walk outdoors using a cane or elbow crutch; eight patients (19%) had a limited walking ability using two axillary crutches, and four patients (9%) were able to walk indoors only.



Radiologically, follow up X-rays AP, Lateral views of hip joint with AP view of pelvis were done for all patients every month for 6 months, and every 6 months later till the final follow up. Postoperative dislocations occurred in two patients (4.5%) and closed reduction was done in one case (Figure 3C and 3D), and in the other patient, operative reduction and soft tissue reconstruction around the hip (Figure 6). Heterotopic ossification was seen in four (9%) of the patients and it was Brooker grade II in three, and grade III in one patient but this ossification did not lead to ankyloses (Figure 7). The acetabular inclination was within the accepted range 35-55° in 36 hips (86%), with six cups (14%) were vertically oriented, and no cup was horizontally oriented. The femoral stem was in neutral position in 34 stems (81%), 5 stems (were in 12%) in varus, and 3 stems (7%) were in valgus position.

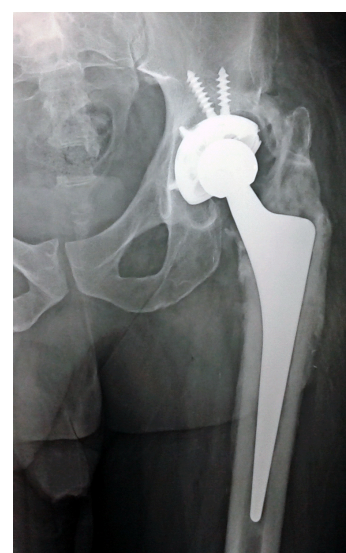According to Engh's criteria, 26 of 32 cementless stems were stable and had bony ingrowth with no significant subsidence, 5 were stable fibrous, and one stems was loose and infected. This patient had revision at 24 months postoperative with long stem cementless modular prosthesis (Figure 8). Radiolucency of 1 mm of cementless acetabular component was seen in 2 zones in six hips (14%), (zones 1 & 2 in 4 hips, and zones 2 & 3 in 2 hips) and these lucencies were not progressive. Two cemented stems with probable loosening at 4 and 6 years, but clinically the patient had minimal discomfort and no revision needed for these two cases. According to Gruen zones criteria for femoral stem, four stems had radiolucent line of 3mm in 2 zones but stems were stable. All cemented acetabular cups except two were stable at the final follow up. In one patient, the radiolucent line around the cemented cup in 2 zones with cup orientation changed from 45° postoperative to 60° at final follow up, but the patients did not agree revision.



**Figure 6:** Female patient 54 years old (Case No. 22): A&B) preoperative X-ray 1 year after debridement and implant extraction; C) postoperative X-ray with hybrid THR (cementless cup and cemented stem); D) postoperative dislocation 6 months postoperative for third time; E) post reduction X-ray; F) 3 years postoperative X-ray.

## Discussion

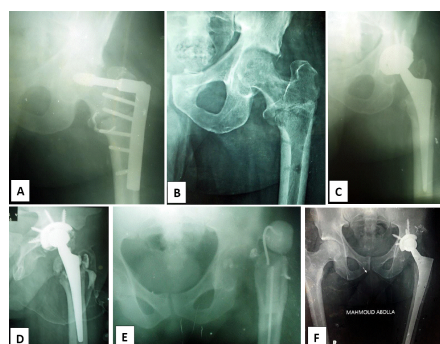
The significant pain and functional disability following failed internal fixation of proximal femoral fractures affect the normal patient's activities. In elderly patients with osteopenia direct the treatment options toward early ambulation and restoration of normal life. Hip replacement options were used to manage these patients either hemiarthroplasty or total hip replacement. The patient age, type of implant failure and the bone stock remained after removal of the implant individually determines the type of prosthesis and its method of fixation either cemented or cement less [1,3,5,22].



**Figure 7:** X-ray showing hypertrophic ossification grade III (Case No.30).

Multiple technical difficulties present in these cases as the holes after removal of hardware, malunion and deformity of proximal femur with

loss of landmarks, loss of bone stock, regional osteopenia, and soft tissue fibrosis with muscle weakness. Difficulties in canal reaming due to fibrosis, old entry of cephalomedullary nail, new bone formation were found in this series, so the beginning of reaming using flexible reamer over a guide wire under image intensifier was used and in eight cases there were no proximal femoral bone for implant stability, so long cement less stem was used in these cases. In cases with trochanteric nonunion reattachment and stainless steel wire fixation was used in 12 cases [22]. Calcar replacement, fully coated stems were used in four patients in these study due to loss of proximal femoral bone with no support to the standard implant.



**Figure 8:** Male patient 44 years old (Case No. 30): A) X-ray with DCS and avascular necrosis of femoral head; B) postoperative X-ray with cementless THR; C) X-ray 1.5 years postoperative with septic loosening; D) X-ray with removal of THR and spacer insertion; E) X-ray after revision with long stem calcar replacement.

Thakur et al. [23] reported on 15 patients with failed intertrochanteric fractures using hip arthroplasty using a modular distally fixing stem total hip replacement. Harris Hip Score (HHS) was improved from 35.9 preoperative to 83 postoperative. They had two patients (13.3%) walking without aid, 10 (66.7%) using a cane and 3 (20%) using a walker for ambulation. There had no patients with dislocation, DVT in one patient (6.67%), and heterotopic ossification in seven patients; 5 patients Brooker's grade (1) and 2 patients grade (2). They used constrained liner in two patients due to questionable stability of the hip intraoperative (Table 2).

In the study of Haidukewych and Berry [1], there were sixty patients of failed internal fixation treated with hip arthroplasty, 32 total hip replacements and 28 hemiarthroplasty. They reported 39 (89%) of survived 44 patients had mild or no pain after a mean follow up period of 65 months. There were 91% of their patients able to walk; and 59% using arm support.

Zhang et al. [24] evaluated the results of arthroplasty in 19 cases with 14 cemented 3 cement less, and 2 hybrid hip replacement after failed internal fixation of intertrochanteric fractures and they reported 47% incidence of complications with 31% intraoperative fracture and 16% postoperative dislocation. Clinically, the mean Harris Hip Score after follow up of 2 years was 79.8.

The decision using total hip replacement in this work was due to acetabular damage either due to screw penetration, chondrolysis, or present osteoarthritis. The selection of cemented or uncemented stem was according to bone stock remained and stability of stem in press fit during reaming. Long stem was used when trochanteric area was comminuted and prosthesis not contained in proximal calcar part.

Harris hip score	Mean score (points)		Postoperative score (number of patients %)				
	Preoperative	Postoperative	Excellent	Good	Fair	Poor	
	24 points	88 points	18(43%)	14(33.5%)	8(19%)	2(4.5%)	
Complications	Postoperative dislocation	Heterotopic ossification		Infection		Revision	DVT
	2 patients	Grade II (3 patients)	Grade III (1patient)	Superficial (3cases)	Deep (1case)	(1 case)	3 cases

**Table 2:** Clinical results and complications.

The results of this study were comparable with other studies. The good results of this study may be due to the relative young age of patients and the selection of the suitable technique for the right patient. The survival rate in 5 years were 95% as two patients required revision one with septic loosening and the other had aseptic loosening but refused revision. Dislocation rate was 5% in this series, in one case closed reduction was done and open reduction with soft tissue reconstruction around proximal femur. There were 42 patients out of fifty with total hip replacement. The Harris hip score improved from 24 preoperative to 88 postoperative with no or mild residual pain in 20 patients (48%), trochanteric pain in six (14%), and anterior thigh pain in 14 patients (33%). In two patients (5%) sever pain was found, in one patient septic loosening and revision was done at 24 months postoperative (Figure 5), the other one had a septic loosening but refused revision.

## Conclusion

Total hip arthroplasty is an accepted procedure after failed internal fixation of trochanteric femoral fractures. Individual selection of the implant depends upon the age of patient, level of activity, the bone stock of proximal femur, and the condition of the acetabulum. The greater trochanter should be reattached with abductor tendon to maintain the stability of hip. Intraoperative dislocation of the hip should be careful to avoid intraoperative fractures. Thus, total hip replacement is a good a successful procedure for patients with failed internal fixation of trochanteric femoral fractures.

## Conflict of interest

No: The author state that there has been no conflict of interest and there were no potential benefits in any form from a commercial party

related directly or indirectly to the subject of this manuscript. No funds, grants, or personnel to be acknowledged have been hidden.

## References

- Haidukewych GJ, Berry DJ (2003) Hip arthroplasty for salvage of failed treatment of intertrochanteric hip fractures. *J Bone Joint Surg Am* 85-85: 899-904.
- Gotfried Y, Cohen B, Rotem A (2002) Biomechanical evaluation of the percutaneous compression plating system for hip fractures. *J Orthop Trauma* 16: 644-650.
- Pachore JA, Shah VI, Sheth AN, Shah KP, Marothi DP, et al. (2013) Hip arthroplasty in failed intertrochanteric fractures in elderly. *Indian J Orthop* 47: 572-577.
- Ruecker AH, Rupprecht M, Gruber M, Gebauer M, Barvencik F, et al. (2009) The treatment of intertrochanteric fractures: results using an intramedullary nail with integrated cephalocervical screws and linear compression. *J Orthop Trauma* 23: 22-30.
- Syed SN, Mehroze Z, Muhammad KRN (2015) Total Hip Arthroplasty in Failed Hip Fractures: A Case Series; Reconstructive Review: 4.
- Wu CC, Shih CH, Chen WJ, Tai CL (1998) Treatment of cutout of a lag screw of a dynamic hip screw in an intertrochanteric fracture. *Arch Orthop Trauma Surg* 117: 193-196.
- Alvarez DB, Aparicio JP, Fernández EL, Múgica IG, Batalla DN, et al. (2004) Implant breakage, a rare complication with the Gamma nail. A review of 843 fractures of the proximal femur treated with a Gamma nail. *Acta Orthop Belg* 70: 435-443.
- Anglen JO (1997) Intertrochanteric osteotomy for failed internal fixation of femoral neck fracture. *Clin Orthop Relat Res*: 175-182.
- Haentjens P, Casteleyn PP, Opdecam P (1994) Hip arthroplasty for failed internal fixation of intertrochanteric and subtrochanteric fractures in the elderly patient. *Arch Orthop Trauma Surg* 113: 222-227.
- Said GZ, Farouk O, El-Sayed A, Said HG (2006) Salvage of failed dynamic hip screw fixation of intertrochanteric fractures. *Injury* 37: 194-202.
- Goldstein WM, Branson JJ (2005) Modular femoral component for conversion of previous hip surgery in total hip arthroplasty. *Orthopedics* 28: 1079-1084.
- Laffosse JM, Molinier F, Tricoire JL, Bonneville N, Chiron P, et al. (2007) Cementless modular hip arthroplasty as a salvage operation for failed internal fixation of trochanteric fractures in elderly patients. *Acta Orthop Belg* 73: 729-736.
- Mears DC, Durbhakula SM, Velyvis JH (2003) Reconstructive total hip replacement after proximal femoral injuries. In: Browner BD, Jupiter JB, Levine AM, Trafton PG (eds) *Skeletal Trauma*. Philadelphia, PA, Saunders: 1817.
- Patterson BM, Salvati EA, Huo MH (1990) Total hip arthroplasty for complications of intertrochanteric fracture. A technical note. *J Bone Joint Surg Am* 72: 776-777.
- Harris WH (1969) Traumatic arthritis of the hip after dislocation and acetabular fractures: treatment by mold arthroplasty. An end-result study using a new method of result evaluation. *J Bone Joint Surg Am* 51: 737-755.
- Nilsdotter A, Bremander A (2011) Measures of hip function and symptoms: Harris Hip Score (HHS), Hip Disability and Osteoarthritis Outcome Score (HOOS), Oxford Hip Score (OHS), Lequesne Index of Severity for Osteoarthritis of the Hip (LISOH), and American Academy of Orthopedic Surgeons (AAOS) Hip and Knee Questionnaire. *Arthritis Care Res (Hoboken)* 11: 200-207.
- Engh CA, Bobyn JD, Glassman AH (1987) Porous-coated hip replacement. The factors governing bone ingrowth, stress shielding, and clinical results. *J Bone Joint Surg Br* 69: 45-55.
- Gruen TA, McNeice GM, Amstutz HC (1979) "Modes of failure" of cemented stem-type femoral components: a radiographic analysis of loosening. *Clin Orthop Relat Res*: 17-27.
- DeLee JG, Charnley J (1976) Radiological demarcation of cemented sockets in total hip replacement. *Clin Orthop Relat Res*: 20-32.
- Brinker MR, Rosenberg AG, Kull L, Cox DD (1996) Primary noncemented total hip arthroplasty in patients with ankylosing spondylitis, clinical and radiographic results at an average follow-up period of 6 years. *J Arthroplasty* 11: 802.
- Brooker AF, Bowerman JW, Robinson RA, Riley LH Jr (1973) Ectopic ossification following total hip replacement. Incidence and a method of classification. *J Bone Joint Surg Am* 55: 1629-1632.
- Xiaojun S, Zongke Z, Jing Y, Bin S, Pengde K, et al. (2015) Total Hip Arthroplasty Using Non-Modular Cementless Long-Stem Distal Fixation for Salvage of Failed Internal Fixation of Intertrochanteric Fracture. *J of Arthroplasty* 30: 1999-2003.
- Thakur RR, Deshmukh AJ, Goyal A, Ranawat AS, Rasquinha VJ, et al. (2011) Management of failed trochanteric fracture fixation with cementless modular hip arthroplasty using a distally fixing stem. *J Arthroplasty* 26: 398-403.
- Zhang B, Chiu KY, Wang M (2004) Hip arthroplasty for failed internal fixation of intertrochanteric fractures. *J Arthroplasty* 19: 329-333.