

# The Value of the Bispectral Index as an Early Sign of Perioperative Stroke

Eduardo Allodi-Andrade<sup>1\*</sup>, Iandra C. Loureiro<sup>1</sup> and Ismar L. Cavalcanti<sup>2</sup>

<sup>1</sup>Resident, Department of Anesthesiology, National Cancer Institute, Rio de Janeiro, Brazil

<sup>2</sup>Chairman, Department of Anesthesiology, National Cancer Institute, Rio de Janeiro, Brazil

**Keywords:** Bispectral Index; Stroke; Neurological monitoring

## Introduction

The use of the Bispectral Index (BIS; Aspect Medical Systems, Natick, MA) was originally developed to permit anesthesiologists to titrate the hypnotic agents used [1]. However, recent case reports and studies [2-7] have demonstrated the possibility that this device may help to provide an earlier indication of unfavorable neurological outcomes, when otherwise unexplained low BIS<sup>TM</sup> values and high Suppression Ratio (SR) values occur.

Here we describe the case of a patient who was submitted to a Transsphenoidal Hypophysectomy. After a hypertensive crisis, the BIS<sup>TM</sup> value helped to recognize an unfavorable neurological event and permitted a timely diagnosis.

## Case Report

The patient was a 46-yr-old male scheduled for an elective Transsphenoidal Hypophysectomy, due to a macroadenoma that was reducing his visual acuity and leading to hypothyroidism. He was medicated with thyroid hormone and had no history of previous arterial hypertension. Pre-operative laboratory values and physical examination were normal.

He had two peripheral intravenous (16G and 20G) lines and an arterial line placed. A forced-air warming blanket was provided to avoid loss of body heat. Monitoring included capnography, pulse oximeter, neuromuscular transmission monitor (Datex-Ohmeda Aespire/5, Madison, WI) and BIS<sup>TM</sup> throughout the entire period and all values were appropriate for a conscious person. Induction consisted of lidocaine 70 mg to attenuate the hemodynamic responses to laryngoscope [8], a targeted control infusion of Propofol 4 mcg/ml, Remifentanyl 0.2 mcg.kg<sup>-1</sup>.min<sup>-1</sup> and Rocuronium 50 mg. For maintenance during the surgery, Propofol 3 mcg/ml and Remifentanyl 0.2 mcg.kg<sup>-1</sup>.min<sup>-1</sup> were used and boluses of Rocuronium 0.1 mg/Kg were employed to maintain 2 to 3 muscle contractions in the train-of-four stimulation pattern.

The surgeon applied oxymetazolin, which is a topical

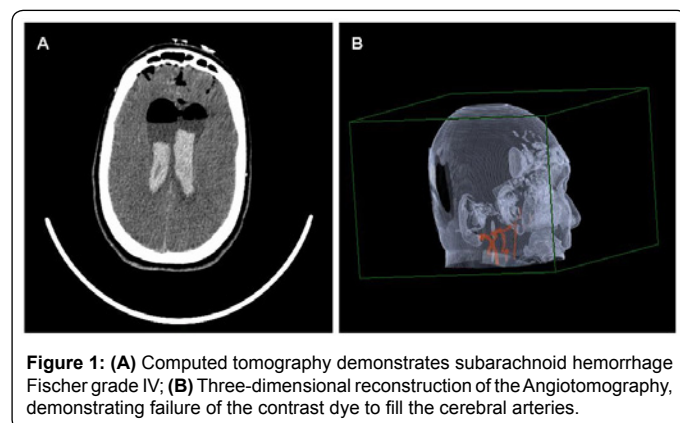
decongestant, prior to the surgical incision, to prevent intensive hemorrhage and the patient showed an increase in mean arterial pressure (MAP) from 90 to 110 mmHg, without any consequences. After 3 hours of surgery, without any arterial pressure fluctuations, the surgeon requested the anesthesiologist to raise the arterial pressure in order to check for possible hemorrhages. After 5 mg ephedrine IV, MAP rose from 70 mmHg to 160 mmHg, the BIS<sup>TM</sup> value dropped from 40 to zero and the SR went to 100. Sodium nitroprusside was initiated, which caused the MAP to drop to 80 mmHg and the BIS<sup>TM</sup> to rise to 30; however, it soon fell again to zero. All anesthetic agents were discontinued, but after 30 minutes the patient did not awaken and developed unresponsive paralytic mydriasis. After the neurosurgeon made a rapid neurological evaluation, an emergency computed angiogram scan was carried out and showed an acute hemorrhagic stroke and failure of the contrast dye to fill the cerebral arteries (Figure 1), leading to a diagnosis of cerebral death. The patient was taken to an intensive-care unit where he died of multiple organ failure after 4 days.

## Discussion

In the present case report, we show how the BIS<sup>TM</sup> device was more helpful than clinical examination, as a signal for early recognition of a catastrophic neurological outcome.

The value of this index, which was designed to measure intra-operative consciousness, falls due to hypnotic agents such as Propofol, hypothermia and hypoxia/hypoperfusion insults, since all three decrease neuronal depolarization, changing the pattern of the cerebral wave [1]. At prompt, one cannot ascertain with certainty which of these may be the causative agent; however, the index may suggest hypotheses, once we begin to exclude improbable causes.

In this case, the most probable cause for the observed rise in the SR and fall in the BIS<sup>TM</sup> index in the operating room was a hypoxia/hypoperfusion insult, since it changed linearly with the values of MAP and correction of this value raised the index temporarily. In addition, the angiogram confirmed the principal hypothesis. Although temperature was not being monitored, this was not considered a probable cause, since this type of surgery does not result in substantial loss of body heat and we used a warming blanket to protect the patient from cool temperatures in the operating room.



**Figure 1:** (A) Computed tomography demonstrates subarachnoid hemorrhage Fischer grade IV; (B) Three-dimensional reconstruction of the Angiotomography, demonstrating failure of the contrast dye to fill the cerebral arteries.

**\*Corresponding author:** Eduardo Allodi-Andrade, Praça Cruz Vermelha, 23 – 9o andar, 20230-130, Rio de Janeiro, RJ, Brazil, Tel: 552125066114, 552125066252; Fax: 552125066264; E-mail: [edualodi@yahoo.com.br](mailto:edualodi@yahoo.com.br)

**Received** September 04, 2010; **Accepted** October 22, 2010; **Published** October 24, 2010

**Citation:** Allodi-Andrade E, Loureiro IC, Cavalcanti IL (2010) The Value of the Bispectral Index as an Early Sign of Perioperative Stroke. J Anesth Clin Res 1:107. doi:10.4172/2155-6148.1000107

**Copyright:** © 2010 Allodi-Andrade E, et al. This is an open-access article distributed under the terms of the Creative Commons Attribution License, which permits unrestricted use, distribution, and reproduction in any medium, provided the original author and source are credited.

Other authors have described the BIS™ as an indicator of inadequate cerebral function during the removal of a left ventricular assist device [2] in cardiac surgery [4,6,7] and in an arteriovenous shunt construction [5]. As far as we know, this is the first case in which a hypothesis of perioperative stroke was suspected through the use of this device in a Transsphenoidal Hypophysectomy procedure. We are aware that if we had not used the BIS™ monitor during this surgery, our diagnostic approach would have been similar, although with a significant delay that could have avoided irreversible sequelae, had not the patient suffered a massive hemorrhage. In the case reports of Welsby et al. [2] and Ellenberger et al. [7], early and unfavorable results were also suspected based on the BIS™ monitor, but the results could not have been circumvented. However, Morimoto et al. [5] have shown that drops in the BIS values and increased SR values occurred linearly with low MAPs in a patient with altered autoregulation due to chronic hypertension. Therefore they managed to maintain the MAP at higher levels and after surgery, the patient had no neurological deficit. This case highlights the importance of the BIS™ monitor as an additional tool that may help to prevent cerebral damage and it clearly shows that a normal MAP is not a guarantee of regular cerebral blood flow.

In a recent study, Myles et al. [3] suggested that the BIS™ device may assist in distinguishing patients who could benefit from active resuscitation and treatment from those who could not, therefore contributing to a possible change in current practice and was of greater value than clinical judgment or pupillary signs. Nevertheless, further studies should be undertaken to confirm this possibility.

Clearly, this device has limitations in identifying focal ischemic insults, since only the unilateral frontal cortex is monitored. Finally, clinical and imaging examinations should be undertaken to confirm the diagnostic hypothesis. Until more information from larger clinical trials becomes available or new and improved models of BIS™ are developed, this device should be considered as a monitor of anesthetic depth, rather than as a diagnostic tool.

#### References

1. Johansen JW (2006) Update on bispectral Index monitoring. *Best Pract Res Clin Anaesth* 20: 81-99.
2. Welsby IJ, Ryan JM, Booth JV, Flanagan E, Messier RH, et al. (2003) The Bispectral Index in the Diagnosis of Perioperative Stroke: A Case Report and Discussion. *Anesth Analg* 96: 435-437.
3. Myles PS, Daly D, Silvers A, Cairo S (2009) Prediction of Neurological Outcome Using Bispectral Index Monitoring in Patients with Severe Ischemic-Hypoxic Brain Injury Undergoing Emergency Surgery. *Anesthesiology* 110: 1106-1115.
4. Villacorta J, Kerbaul F, Collart F, Guidon C, Bonnet M, et al. (2005) Perioperative Cerebral Ischaemia in Cardiac Surgery and BIS. *Anaesth Intensive Care* 33: 514-517.
5. Morimoto Y, Monden Y, Ohtake K, Sakabe T, Hagiwara S (2005) The Detection of Cerebral Hypoperfusion with Bispectral Index Monitoring During General Anesthesia. *Anesth Analg* 100: 158-161.
6. England MR (1999) The Changes in Bispectral Index during a Hypovolemic Cardiac Arrest. *Anesthesiology* 91: 1947-1949.
7. Ellenberger C, Diaper J, Licker M, Panos A (2007) Bispectral Index and Detection of acute Brain Injury during Cardiac Surgery. *Eur J Anaesthesiol* 24: 807-809.
8. Salhi B, Stettner E (2007) In defense of the use of lidocaine in rapid sequence intubation. *Ann Emerg Med* 49:84-86.