

The Use of SWEPT SOURCE OCT Angio in Diagnosis and Staging of Type 2 Macular Telangiectasia (MacTel 2)

Al Mamoori Fawwaz*

Medical Retina Department, Eye Specialty Hospital Amman, Jordan

*Corresponding author: Fawwaz Fali Al-Mamoori, Medical Retina Department, Eye Specialty Hospital, Amman, 11821, Jordan, Tel: 0096277519101; Email: fawazalmamoori@gmail.com

Received date: December 13, 2016; Accepted date: January 10, 2017; Published date: January 28, 2017

Copyright: ©2017 Fawwaz AM, et al. This is an open-access article distributed under the terms of the Creative Commons Attribution License, which permits unrestricted use, distribution, and reproduction in any medium, provided the original author and source are credited.

Abstract

Diagnosis and staging of macular telangiectasia type 2 (MacTel2) using Swept Source optical coherence tomography angiography.

Keywords: MacTel2, Angiography, Swept Source optical coherence tomography

Introduction

Macular telangiectasia type 2 has also been termed idiopathic perifoveal telangiectasia or idiopathic juxtafoveal telangiectasia type 2 [1-3]. It is now referred to as MacTel type 2, and it is a bilateral perifoveal vasculopathy which originates in the deep retinal capillary plexus in the temporal juxtafoveal region [4]. As it progresses, it involves the superficial retinal capillary plexus, and continues to progress anteriorly, posteriorly, and circumferentially. This is called the non-proliferative stage of the disease [5-9]. MacTel type 2 becomes proliferative when the vasogenic process extends under the retina, forming detachment and a retinal-retinal anastomosis. This form of the disease may eventually lead to disciform scarring.

In the early stages of the disease, fluorescein angiography (FA) imaging shows abnormal hyperfluorescence and leakage from the temporal, juxtafoveal capillary plexus, as the disease progresses, the hyperfluorescence and leakage spreads circumferentially around the fovea [7]. While FA provides a definitive diagnosis of MacTel2, it also involves the intravenous injection of a dye that can result in adverse effects such as nausea or vomiting, and rarely fluorescein can elicit an anaphylactic response [10-12]. Autofluorescence (AF) imaging is also useful in diagnosing MacTel2 [13]. Due to the depletion of luteal pigment in the temporal juxtafoveal retina, a relative increase in AF is observed in this region [14-16]. As the disease progresses, luteal pigment is lost circumferentially around the fovea and an increase in the relative hyperfluorescence is observed. In the later stages of the disease, atrophy of the RPE is observed, resulting in decreased AF within the central macula.

Optical coherence tomography (OCT), a noninvasive imaging modality, has revealed structural abnormalities in the inner retina such as retinal cavitation with draping of the internal limiting membrane and abnormalities in the outer retina such as disruption of the photoreceptor inner segment/outer segment/ellipsoid (IS/OS/E) region that were not previously appreciated by FA or AF imaging [17-25]. OCT imaging has improved the early detection of MacTel2 by identifying these early subtle changes in retinal anatomy, and OCT has proven to be useful for following these alterations in macular anatomy as the disease progresses to foveal atrophy, the formation of intraretinal

pigment plaques, and subretinal neovascularization. With the development of spectraldomain OCT (SDOCT) instruments with increased scanning speeds and highspeed sweptsource OCT (SSOCT) instruments, OCT microangiography imaging has emerged as a noninvasive strategy to visualize the retina and choroidal microvasculature without the use of an exogenous intravenous dye injection, [26-37] and identifying distinct characteristics of the capillary networks located within different layers of the retina and choroid.

Aim and Objectives

Diagnosis and staging of macular telangiectasia type 2 (MacTel2) using Swept Source optical coherence tomography Angiography.

Patient and Method

We retrospectively review a 60 year old patient with bilateral MacTel2 evaluated using a swept source OCT (SSOCT). The patient underwent a comprehensive ocular examination and imaging tests as part of the evaluation of her condition. The imaging tests included color fundus imaging (Topcon, Tokyo, Japan), digital fundus AF imaging, FA and Swept Source OCT with OCT Angio (TRITON TOPCON OCT).

The patient had no any other retinal pathology such as diabetic retinopathy or pathologic myopia and not previously treated with photodynamic therapy (PDT), thermal laser, intravitreal injections, or any retinal surgery. Information about previous medical conditions and ocular treatments was obtained by reviewing the medical charts.

Results

(SS-OCT A) detected abnormal microvasculature in all MacTel2 eyes, predominantly in the middle retinal layer. These vessels correlated well with the FA alterations. The abnormal temporal, juxtafoveal microvasculature in MacTel2 became apparent as the disease progressed and in later stages tended to extend circumferentially, with anastomotic vessels temporally.

In our Case, the Right Eye was in Early, Nonproliferative MacTel2, Best corrected visual acuity (BCVA) in her left eye was 20/30. The horizontal Bscan with the retinal flow in different layers represented by

colors shows the dilated vessels in the deep retinal capillary plexus found in the middle retinal layer, most pronounced in the region temporal to the fovea as observed in green (Figure 1A and B).With

intact IS-OS Junction (Figure 3), Fluorescein angiography shows telangiectatic abnormalities with mild hyperfluorescence and leakage in the temporal juxtafoveal region (Figure 2).

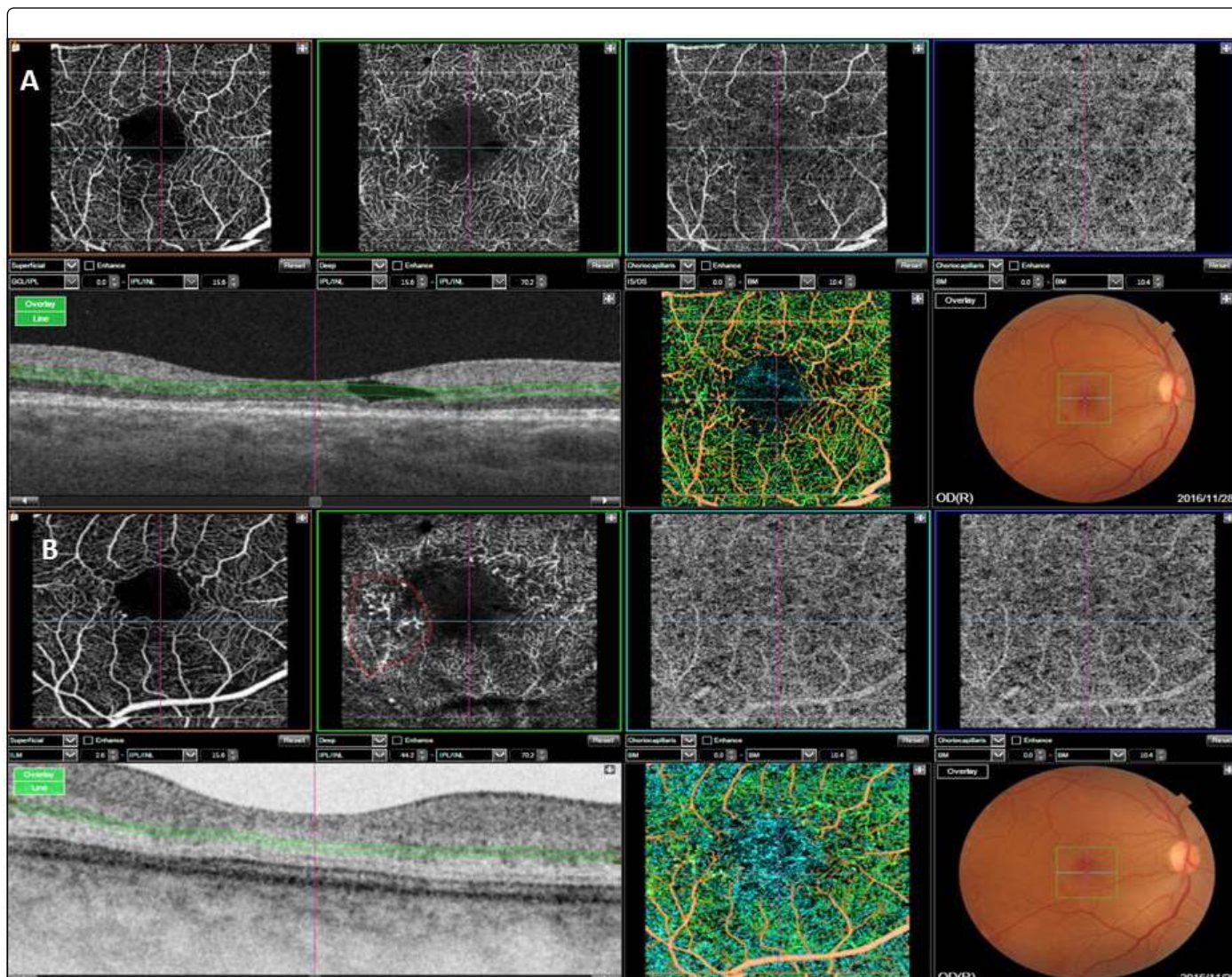


Figure 1: Horizontal Bscan with the retinal flow in different layers represented by colors.

The left eye was in Proliferative MacTel 2, best corrected visual acuity (BCVA) in her left eye was 20/50, and The Bscan shows cavitation in the outer retina and disruption of the IS/OS/E boundary in the temporal juxtafoveal region. The Bscan representing the microvascular flow (Figure 4A and B) details the presence of abnormal microvasculature (green and blue corresponding to an area with retinal

vascular anastomoses. Disruption of the microvasculature extends into the outer retina where the IS/OS/E is disrupted. Microvascular abnormalities, such as a distorted juxtafoveal capillary plexus with prominent anastomoses, FA imaging demonstrates hyperfluorescence in the temporal juxtafoveal region in the earliest stage associated with late leakage (Figure 5).

Conclusion

We used the SS-OCT angio technique to investigate eyes with MacTel2 using a TRITON SSOC. To extract the blood flow information and visualize the microvasculature of the central macula, the central macular microvasculature was visualized better than with

FA imaging. In addition, the better visualization of the juxtafoveal microvasculature with SS-OCT Angio may also be due, in part, to the absence of leakage on OCT Angio imaging, and it is this leakage that could obscure the normal vasculature seen on routine FA imaging. By

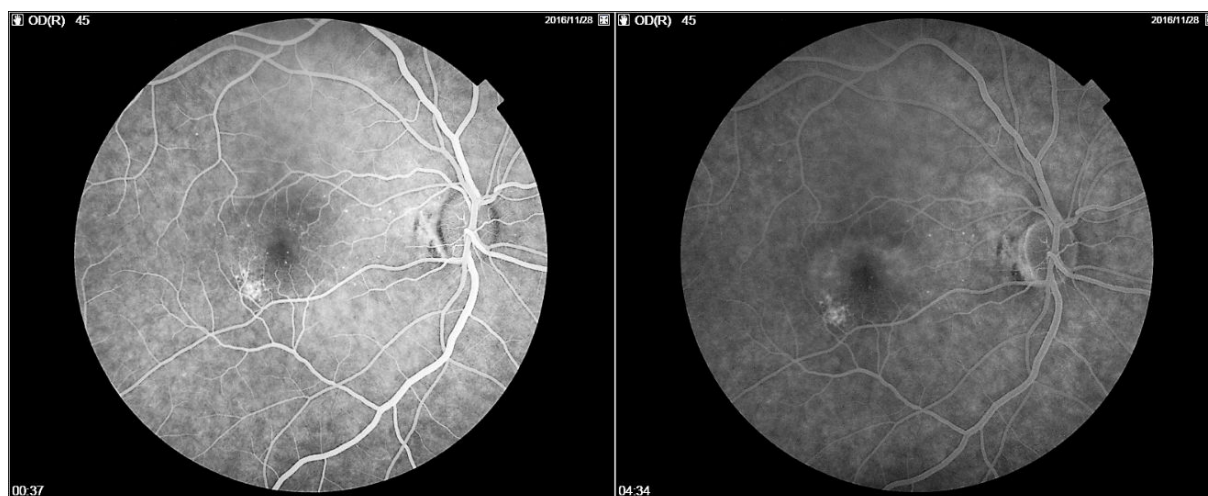

Figure 2: Fluorescein angiography showing telangiectatic abnormalities with mild hyperfluorescence and leakage in the temporal juxtafoveal region.

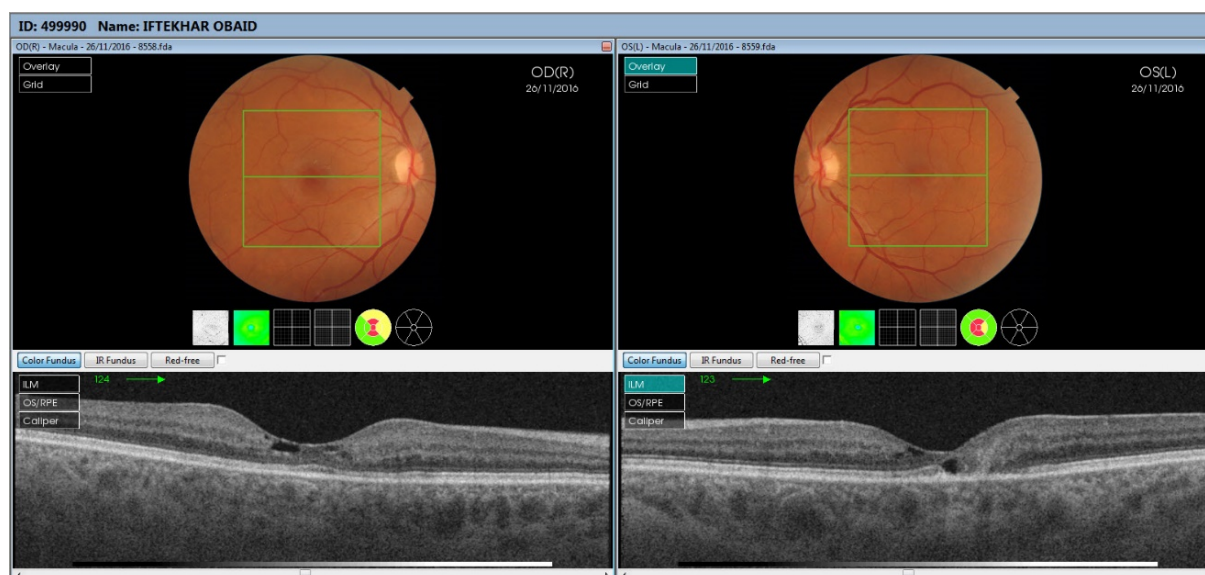


Figure 3: IS-OS Junction.

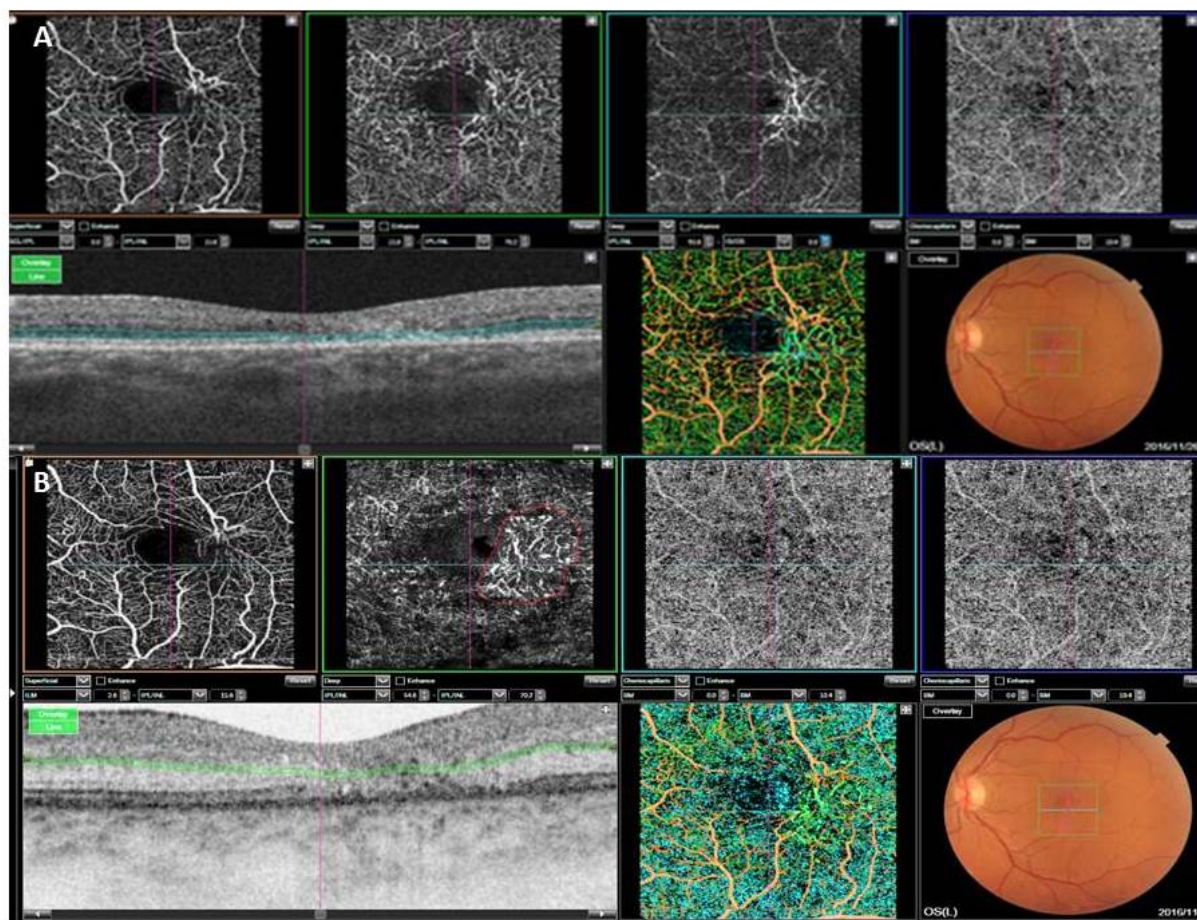


Figure 4: Bscan representing the microvascular flow.

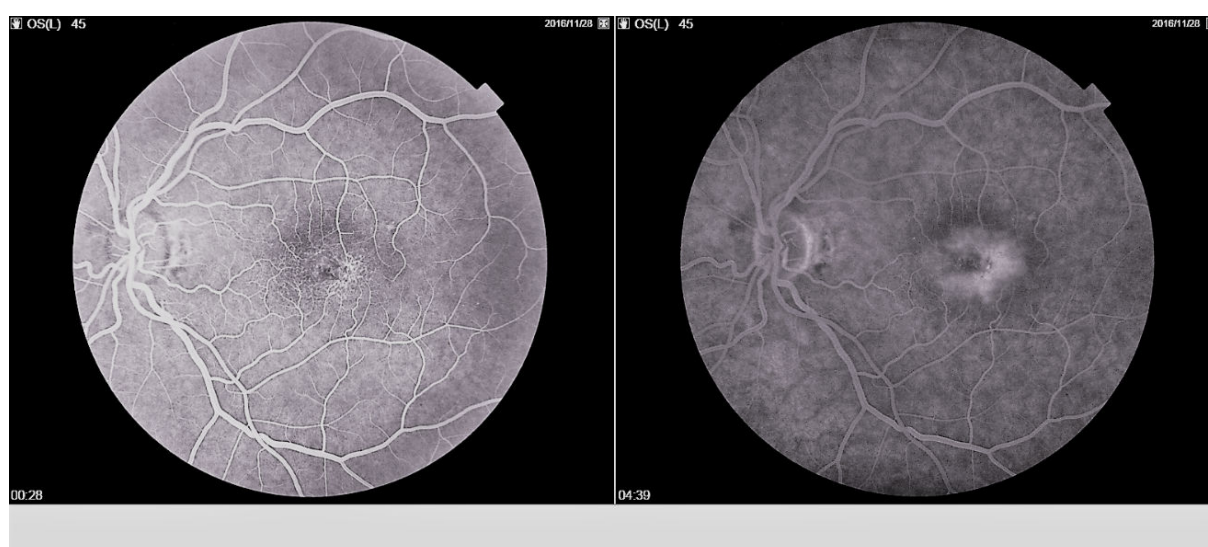

Figure 5: FA imaging demonstrates hyperfluorescence in the temporal juxtafoveal region in the earliest stage associated with late leakage.

using this ability to extract and visualize these retinal layers in MacTel2 and other diseases, SS-OCT Angio imaging may help facilitate the early diagnosis of disease and provide a better understanding of disease progression and the efficacy of treatments and to differentiate MacTel2 from other diseases affecting the retinal microvasculature associated with fluorescein angiographic leakage, such as neovascular age-related macular degeneration, diabetic macular edema, vein occlusions, and cystoid macular edema from differing conditions.

References

- Gass JD, Blodi BA (1993) Idiopathic juxtafoveal retinal telangiectasis. Update of classification and follow-up study. *Ophthalmology* 100: 1536-1546.
- Yannuzzi LA, Bardal AM, Freund KB, Chen KJ, Eandi CM, et al. (2006) Idiopathic macular telangiectasia. *Arch Ophthalmol* 124: 450-460.
- Yannuzzi LA (2010) *The Retinal Atlas*. Saunders Elsevier, Oxford, UK.
- Aung KZ, Wickremasinghe SS, Makeyeva G, Robman L, Guymer RH (2010) The prevalence estimates of macular telangiectasia type 2: the Melbourne Collaborative Cohort Study. *Retina* 30: 473-478.
- Klein R, Blodi BA, Meuer SM, Myers CE, Chew EY, et al. (2010) The prevalence of macular telangiectasia type 2 in the Beaver Dam eye study. *Am J Ophthalmol* 150: 55-62.
- Clemons TE, Gillies MC, Chew EY, Bird AC, Peto T, et al. (2010) Baseline characteristics of participants in the natural history study of macular telangiectasia (MacTel) MacTel Project Report No. 2. *Ophthalmic Epidemiol* 17: 66-73.
- <http://www.healio.com/ophthalmology/journals/osli/20149455/%7B849feaaa8a02423292ec8b4fd894db7d%7D/sweptsourcesoctangiographyofm...34/37>
- Sallo FB, Leung I, Chung M, Wolf-Schnurrrbusch UE, Dubra A, et al. (2011) Retinal crystals in type 2 idiopathic macular telangiectasia. *Ophthalmology* 118: 2461-2467.
- Zhu M, Krilis M, Gillies MC (2013) The relationship between inner retinal cavitation, photoreceptor disruption, and the integrity of the outer limiting membrane in macular telangiectasia type 2. *Retina* 33: 1547-1550.
- Schmitz-Valckenberg S, Ong EE, Rubin GS, Peto T, Tufail A, et al. (2009) Structural and functional changes over time in MacTel patients. *Retina* 29: 1314-1320.
- López-Sáez MP, Ordoqui E, Tornero P, Baeza A, Sainza T, et al. (1998) Fluorescein-induced allergic reaction. *Ann Allergy Asthma Immunol* 81: 428-430.
- Lira RP, Oliveira CL, Marques MV, Silva AR, Pessoa Cde C (2007) Adverse reactions of fluorescein angiography: a prospective study. *Arq Bras Oftalmol* 70: 615-618.
- Charbel Issa P, Gillies MC, Chew EY, Bird AC, Heeren TF, et al. (2013) Macular telangiectasia type 2. *Prog Retin Eye Res* 34: 49-77.
- Theelen T, Berendschot TT, Boon CJ, Hoyng CB, Klevering BJ (2008) Analysis of visual pigment by fundus autofluorescence. *Exp Eye Res* 86: 296-304.
- Wong WT, Forooghian F, Majumdar Z, Bonner RF, Cunningham D, et al. (2009) Fundus autofluorescence in type 2 idiopathic macular telangiectasia: correlation with optical coherence tomography and microperimetry. *Am J Ophthalmol* 148: 573-583.
- Ooto S, Hangai M, Takayama K, Arakawa N, Tsujikawa A, et al. (2011) High-resolution photoreceptor imaging in idiopathic macular telangiectasia type 2 using adaptive optics scanning laser ophthalmoscopy. *Invest Ophthalmol Vis Sci* 52: 5541-5550.
- Balaskas K, Leung I, Sallo FB, Clemons TE, Bird AC, et al. (2014) Associations between autofluorescence abnormalities and visual acuity in idiopathic macular telangiectasia type 2: MacTel project report number 5. *Retina* 34: 1630-1636.
- Mathew R, Sivaprasad S, Florea D, Leung I, Sallo F, et al. (2013) Agreement between time-domain and spectral-domain optical coherence tomography in the assessment of macular thickness in patients with idiopathic macular telangiectasia type 2. *Ophthalmologica* 230: 144-150.
- Surguch V, Gamulescu MA, Gabel VP (2007) Optical coherence tomography findings in idiopathic juxtafoveal retinal telangiectasis. *Graefes Arch Clin Exp Ophthalmol* 245: 783-788.
- Gaudric A, Ducos de Lahitte G, Cohen SY, Massin P, Haouchine B (2006) Optical coherence tomography in group 2A idiopathic juxtafoveal retinal telangiectasis. *Arch Ophthalmol* 124: 1410-1419.
- Paunescu LA, Ko TH, Duker JS, Chan A, Drexler W, et al. (2006) Idiopathic juxtafoveal retinal telangiectasis: new findings by ultrahigh-resolution optical coherence tomography. *Ophthalmology* 113: 48-57.
- Koizumi H, Iida T, Maruko I (2006) Morphologic features of group 2A idiopathic juxtafoveal retinal telangiectasis in three-dimensional optical coherence tomography. *Am J Ophthalmol* 142: 340-343.
- Baumüller S, Charbel Issa P, Scholl HP, Schmitz-Valckenberg S, Holz FG (2010) Outer retinal hyperreflective spots on spectral-domain optical coherence tomography in macular telangiectasia type 2. *Ophthalmology* 117: 2162-2168.
- Sallo FB, Peto T, Egan C, Wolf-Schnurrrbusch UE, Clemons TE, et al. (2012) The IS/OS junction layer in the natural history of type 2 idiopathic macular telangiectasia. *Invest Ophthalmol Vis Sci* 53: 7889-7895.
- Sallo FB, Peto T, Egan C, et al. (2012) "En face" OCT imaging of the IS/OS junction line in type 2 idiopathic macular telangiectasia. *Invest Ophthalmol Vis Sci* 53: 6145-6152.
- Wang RK, An L, Francis P, Wilson DJ (2010) Depth-resolved imaging of capillary networks in retina and choroid using ultrahigh sensitive optical microangiography. *Opt Lett* 35: 1467-1469.
- An L, Johnstone M, Wang RK (2012) Optical microangiography provides correlation between microstructure and microvasculature of optic nerve head in human subjects. *J Biomed Opt* 17: 116018.
- Wang RK (2010) Optical Microangiography: A Label Free 3D Imaging Technology to Visualize and Quantify Blood Circulations within Tissue Beds in vivo. *IEEE J Sel Top Quantum Electron* 16: 545-554.
- Wang RK, Jacques SL, Ma Z, Hurst S, Hanson SR, et al. (2007) Three dimensional optical angiography. *Opt Express* 15: 4083-4097.
- Choi W, Mohler KJ, Potsaid B, Lu CD, Liu JJ, et al. (2013) Choriocapillaris and choroidal microvasculature imaging with ultrahigh speed OCT angiography. *PLoS One* 8: e81499.
- Jia Y, Bailey ST, Wilson DJ, et al. Quantitative optical coherence tomography angiography of choroidal neovascularization in age-related macular degeneration. *Ophthalmol* 2014; 121: 1435-1444.
- Wei E, Jia Y, Tan O, Potsaid B, Liu JJ, et al. (2013) Parafoveal retinal vascular response to pattern visual stimulation assessed with OCT angiography. *PLoS One* 8: e81343.
- Braaf B, Vermeer KA, Vienola KV, de Boer JF (2012) Angiography of the retina and the choroid with phase-resolved OCT using interval-optimized backstitched B-scans. *Opt Express* 20: 20516-20534.
- Schwartz DM, Fingler J, Kim DY, Zawadzki RJ, Morse LS, et al. (2014) Phase-variance optical coherence tomography: a technique for noninvasive angiography. *Ophthalmol* 121: 180-187.
- Kim DY, Fingler J, Zawadzki RJ, Park SS, Morse LS, et al. (2013) Optical imaging of the chorioretinal vasculature in the living human eye. *Proc Natl Acad Sci USA* 110: 14354-14359.

-
36. Motaghianezam SM, Koos D, Fraser SE (2012) Differential phase-contrast, swept-source optical coherence tomography at 1060 nm for in vivo human retinal and choroidal vasculature visualization. J Biomed Opt 17: 026011.
37. Kim DY, Fingler J, Zawadzki RJ, Park SS, Morse LS, et al. (2012) Noninvasive imaging of the foveal avascular zone with high-speed, phase-variance optical coherence tomography. Invest Ophthalmol Vis Sci 53: 85-92.