

The Surgical Relevance of a Histological Investigation into the Accessory Ethmoidal Foramina and their Contents in a Caucasian Population

Hyder Jeddy¹, Magnus Theodorsson^{1*} and Phillip Adds²

¹St. George's University of London, United Kingdom

²Department of Anatomy, Division of Basic Medical Sciences, St. George's University of London, United Kingdom

*Corresponding author: Magnus Theodorsson, St George's University of London, Anatomy, Division of Basic Medical Sciences, Cranmer Terrace, London, SW17 0RE, United Kingdom, Tel: 07900303441; E-mail: magnustheo@doctors.org.uk

Received date: May 25, 2016; Accepted date: June 24, 2016; Published date: June 30, 2016

Copyright: © 2016 Jeddy H, et al. This is an open-access article distributed under the terms of the Creative Commons Attribution License, which permits unrestricted use, distribution, and reproduction in any medium, provided the original author and source are credited.

Abstract

Aims: It is the objective of this article to investigate the accessory ethmoidal foramina, located in the medial wall of the orbit, adjacent to the anterior and posterior ethmoidal foramina. Previous studies have shown that there is significant variation in the number and location of the fronto-ethmoidal foramina, causing potential complications during surgery. This study aims to identify accessory foramina in cadaveric orbits, and, using histological staining, further identify any structures passing through the foramina.

Methods: Thirty cadaveric orbits from Caucasians were dissected. The number and locations of the accessory foramina in the medial wall were noted. All orbits containing accessory foramina in the medial wall were stained with Sudan black dye, micro-dissected, and microscopically analysed.

Results: Accessory foramina were found in twelve orbits. All accessory foramina showed evidence of vasculature. Three orbits had less than five accessory foramina, four orbits presented with five accessory foramina, six accessory foramina presented in four cases, and in one case eight accessory foramina were present. Under-documented vasculature was found traversing these foramina.

Conclusion: This study highlights the occurrence and variations of accessory ethmoidal foramina in a Caucasian population, and presents their vascular contents. Ophthalmic and ENT surgeons operating on, or in proximity to, the medial wall must be aware of these communicating blood vessels when operating on Caucasian patients. This aims to reduce the risk of intra-operative or post-operative complications, especially in anti-coagulated patients or those with bleeding disorders.

Keywords: Anatomy; Orbit; Physiology; Surgical management

Synopsis

This study found accessory ethmoidal foramina in 40% of the sample population, and every accessory foramen contained evidence of blood vessels. Widely-documented vascular anatomy suggests these are branches of the anterior and posterior ethmoidal vessels.

Introduction

The clinical and surgical management of orbital pathology and trauma is both a complex and delicate practice. It requires the attention of both physicians and surgeons, from a variety of specialties, including ophthalmology, ear, nose and throat, maxillofacial and neurosurgery. An in-depth understanding of the anatomy of the orbit, including the possible variations in structure or neurovascular supply is therefore vital. It is the intention of this study to investigate the medial wall of the orbit, specifically the previously under-documented contents of the accessory ethmoidal foramina. Knowledge of any potential structures passing through these foramina could influence a number of ophthalmic and ENT procedures.

The medial orbital wall is classically taught as containing one anterior and one posterior ethmoidal foramen, however previous studies have documented the presence of multiple foramina. The position and number of these foramina are variable, however a ratio of '24-12-6' mm has been suggested for identifying their location. This outlines the average positions of the ethmoidal foramina in relation to the anterior lacrimal crest – the distance to the anterior ethmoidal foramen described as 24mm, 12mm between anterior and posterior ethmoidal foramina, and 6mm from the posterior foramen to the optic canal [1].

Karakas et al. studied sixty-two orbits from thirty-one Caucasian dry skulls, and found middle ethmoidal foramina in 28% of the sample [2]. Middle ethmoidal foramina were also observed in a study by Mutalik et al. comprising a study of one-hundred dry human skulls from an Indian population [3]. The middle ethmoidal foramen was observed on the right side in thirty-five skulls, and on the left side in forty-one skulls. Twenty and twenty-two extra foramina were noted below the optic canal on the right and left sides respectively. A study conducted by Abed et al. aimed to investigate the validity of the classic 24-12-6 mm anatomical pattern and the extent to which anatomical variation occurs within the British Caucasian population [4]. Of the forty-seven cadaveric orbits examined, the ethmoidal foramina followed a classic anatomical pattern in twenty-six cases (56%), whilst

twenty-one (44%) demonstrated an anatomical variation. These variations occurred bilaterally in eight cadavers (34%) and unilaterally in six (21%). They reported that the distance between the posterior ethmoidal foramen and the optic canal is more than double the distance quoted in the surgical literature-this is due to a high incidence of ethmoidal foramen variation. The study reported the first case in the literature of quintuple ethmoidal foramina, three ethmoidal foramina in seventeen cases (36%) and quadruple ethmoidal foramen in two cases (4%).

This study will further investigate the variation of ethmoidal foramina in a Caucasian population, and will examine the contents of any accessory foramina found.

Materials and Methods

A total of thirty orbits from twenty formalin-fixed cadavers were retrieved and dissected in this investigation. Once the process of dissection was completed, the samples retrieved were then histologically examined using Sudan black dye. Of the twenty cadavers dissected, twelve were retrieved from formalin-fixed cadavers, and eight from soft-fixed cadavers donated to the Anatomy Department of St. George's, University of London. The cause of death was documented for each case, and none of these were found to have impacted the normal anatomy of the orbit. The male-to-female ratio of the cadaveric specimens was 9:11, and all were of Caucasian ethnicity. The investigation was a four-part process: dissection, histological staining, micro dissection and microscopic analysis. Photographs were then taken of the positive results and diagrammatic representations of the medial walls were created using Google Sketch up.

Results

Twelve of the thirty orbits were found to have accessory foramina (40%), all of which demonstrated vasculature passing through them. These vascular bundles were identified either by coloration from Sudan black dye, or by the visible protrusion of a blood vessel undisturbed by the dissection and micro dissection process. Three orbits contained less than five accessory foramina, four orbits presented with five accessory foramina, six accessory foramina presented in four cases, and one orbit contained eight accessory foramina. On average, there were five accessory foramina per orbit. The variation in foramina location was categorised into an anterior region, in relation to the anterior ethmoidal foramen, a medial region, or posterior, nearest to the posterior ethmoidal foramen. Six cases were found to have foramina at one site (50%), and the remaining six cases presented at two different sites, with no occurrence of foramina in all three regions. Across the twelve orbits identified, twenty-six accessory foramina were located anteriorly (43%), with an equal number posteriorly and nine medial foramina overall (14%), (Figure 1).

Discussion

Having searched the latest literature, this study presents the most comprehensive findings of the contents of the accessory ethmoidal foramina in Caucasians. Knowledge of these vessels is necessary in conditions for which a surgical approach to the medial orbital wall is indicated, including fractures to the orbit, orbital tumours, or severe epistaxis requiring ligation of the anterior and posterior ethmoidal arteries. These extra-orbital branches of the ophthalmic artery have often been recorded as significantly variable in their presence and location. The origins of the accessory blood vessels found in this

investigation are best understood when the widely-accepted anatomy is considered, alongside variations documented in previous notable studies.

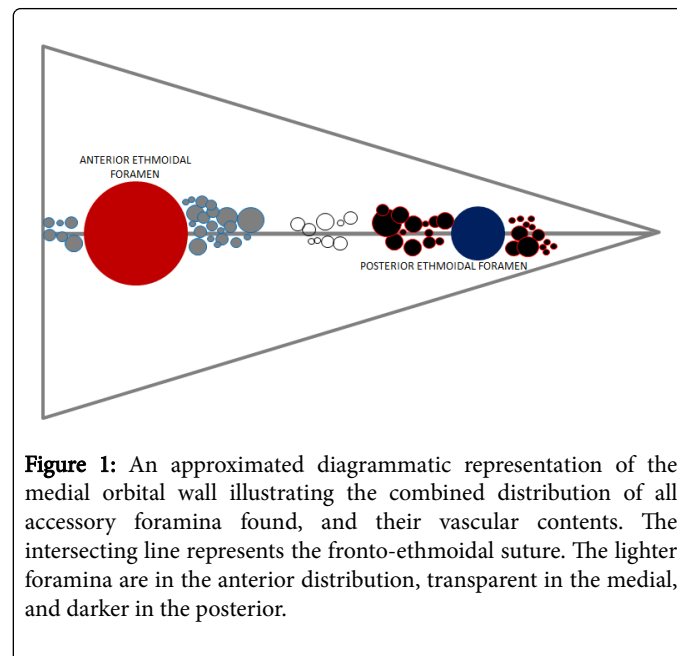


Figure 1: An approximated diagrammatic representation of the medial orbital wall illustrating the combined distribution of all accessory foramina found, and their vascular contents. The intersecting line represents the fronto-ethmoidal suture. The lighter foramina are in the anterior distribution, transparent in the medial, and darker in the posterior.

The small posterior ethmoidal artery arises near the junction of the second and third portions of the ophthalmic artery, and can be absent in 25% of cases [5]. In the 75% of individuals who have this vessel, it arises from the supraorbital artery, or less frequently from the anterior ethmoidal artery. It extends medially across the orbit and commonly passes over the superior oblique muscle, occasionally passing underneath. The artery subsequently exits through the posterior ethmoidal foramen 5-10 cm anterior to the optic canal.

In contrast, the posterior ethmoidal artery has been found to vary in origin, course and diameter. Erdogmus et al. documented three different origins from the ophthalmic artery, 94% stemming from the bend, 5% from its terminal portion, and the remainder from the second half of the artery [6]. In a radiological study of the anatomy of the ethmoidal arteries, variations were found to occur more frequently in the posterior ethmoidal artery [7].

Whilst previous studies have focused on the differing origins and course of the posterior ethmoidal artery, there is little found in the literature regarding any variation of the artery as it approaches the medial orbital wall. However a number of investigations have been made on the variants of the posterior ethmoidal foramina. Huamanop et al. noted the presence of multiple posterior ethmoidal foramina in 62% of 100 Thai orbits studied [8]. This multiplicity of foramina indicates the possibility of numerous branches of the posterior ethmoidal artery entering the medial wall. This current study demonstrates many different variations of foramina in the region of the posterior ethmoidal foramen (Figure 1), meaning a complex of vessels may be passing through this part of the orbit in a Caucasian individual.

Multiple posterior ethmoidal foramina were identified by Abed et al. in which a maximum of 3 posterior foramina were found, whereas 6 were noted in the present study [4]. This difference may have arisen due to the use of microscopic analysis, allowing for the observation of the smallest of foramina. It is important to understand that Abed et al.

defined any foramina existing beyond the anterior ethmoidal foramen as a combination of true posterior ethmoidal foramina with accessory foramina, regardless of distance from the posterior ethmoidal foramen. This was rejected in this study, as multiple accessory foramina with evidence of vasculature were within 1-3 mm of both the anterior and posterior ethmoidal foramina. This potentially indicates that both anterior and posterior ethmoidal arteries split into branches before traversing the medial wall. Abed et al. stated a similar idea, theorising that such foramina could represent multiple entry points of the posterior ethmoidal vasculature.

By contrast, the anterior ethmoidal artery is larger and more constant in comparison to the posterior ethmoidal artery. It occasionally originates from the supra-orbital artery, is absent in 2% of cases and can have multiple branches [5]. Four different variations in origin and course have been observed, all in relation to the superior oblique muscle. In the most common variant found by Erdogmus et al. the anterior ethmoidal artery originates from the ophthalmic artery and courses towards the inferior aspect of the medial orbital wall (66.7% of cases) [6]. Further examples take alternative trajectories towards the medial wall.

A larger investigation comprising four studies into the anterior ethmoidal artery shows 100% origin from the ophthalmic artery, and comments on the anterior ethmoidal canal not being continuous in its bone structure, being in partial or total dehiscence [9]. Between the four study arms, the occurrence of this ranged between 6% and 67%. This dehiscence of the canal potentially indicates that the artery splits into branches, either just prior to entering the canal, or within the canal itself. The lamina papyracea is known for not having a direct blood supply, meaning these vessels could possibly be the nourishing arteries of the ethmoid bone.

The importance of accurate anatomical knowledge is paramount in surgical practice. Several surgical procedures involve access to the anterior and posterior ethmoidal arteries. If one of these is damaged, it can cause profuse haemorrhage, resulting in an ophthalmic emergency whereby an orbital haematoma can rapidly form [5]. If such bleeding develops into the retro-bulbar space, impingement of the optic nerve can lead to blindness.

Iatrogenic laceration of any of the accessory blood vessels described in this study, or rupture by traumatic means, could exacerbate any pre-existing bleeding in the region. This produces additional surgical complications, especially in patients with reactionary haemorrhages who are anti-coagulated or those with intercurrent coagulopathies. In such cases, minor damage to even the smallest of vessels can accelerate the onset of an ophthalmic emergency. Additionally, the anterior ethmoidal artery is particularly vulnerable during surgery to the anterior ethmoidal sinus, and injury may lead to profuse epistaxis and intra-or retro-orbital bleeding [10]. Since this artery crosses three main cavities (the orbit, ethmoid labyrinth, and anterior fossa of the skull), the multiple branches described entering the medial orbital wall could potentially mirror further vascular branches in the other regions.

Furthermore, the accurate anatomy of the medial orbital wall must be considered in procedures such as orbital decompression for dysthyroid orbitopathy, whereby medial orbital wall removal, artery cauterisation or excision facilitates decompression of the optic nerve [11]. A safe anatomical boundary of at least 5 mm from any accessory ethmoidal foramina is suggested, to reduce the complications of interruptions to these vessels (Figure 2). On evaluating all documented occurrences of accessory ethmoidal foramina, including the findings

from this study, the area beyond this suggested boundary is most unlikely to present with accessory foramina and related vasculature [2,4,6].

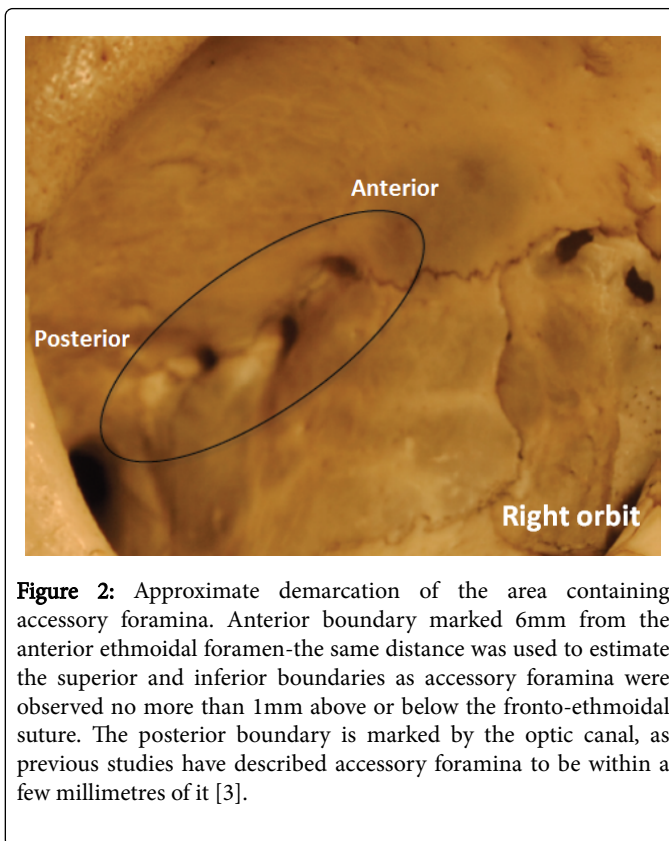


Figure 2: Approximate demarcation of the area containing accessory foramina. Anterior boundary marked 6mm from the anterior ethmoidal foramen—the same distance was used to estimate the superior and inferior boundaries as accessory foramina were observed no more than 1mm above or below the fronto-ethmoidal suture. The posterior boundary is marked by the optic canal, as previous studies have described accessory foramina to be within a few millimetres of it [3].

These findings will benefit all ophthalmic surgeons working in proximity to the medial orbit wall, aiding a reduction in complications from intra- and post-operative haemorrhage if an awareness of these vessels is appreciated. Additionally, ophthalmic anaesthetists should note the potential for accessory vasculature when making invasive anaesthetic injections. Retrobulbar and peribulbar injections, traditionally used in procedures such as cataract removal, are known to carry a greater risk of retrobulbar or periocular haemorrhage in comparison with sub-Tenon blocks increasingly in practice today [12,13]. A 1-year survey across both national and private healthcare in the UK found that haemorrhage secondary to retrobulbar and peribulbar injection was the second most common 'potentially sight-threatening' complication, behind globe perforation. Despite the incidence being rare (2.9 per 10,000), any avoidable harm to the patient should be minimised where possible. Another study of 1,915 retrobulbar blocks involving 10 cases of sight-threatening retrobulbar haemorrhage highlights this [14]. A proportion of these complications could potentially have been caused by the rupture of accessory ethmoidal vessels.

Implications for ENT conditions are also notable. The majority of epistaxis presentations arise from the anterior part of the septum, Little's area, which is supplied via the anterior and posterior ethmoidal arteries [12]. Anatomical similarities between Little's area and the fronto-ethmoidal suture line suggest similar foramina and vasculature may be present, making this site another source of complication from pathology, trauma or iatrogenic compromise.

Attempts to minimise limitations of this study were made, through careful dissection and method consideration, however they cannot be excluded. Despite significant delicacy in dissection technique, it is possible that some vessels and structures may have been removed from the medial wall, particularly during enucleation. The histological staining was also unable to assess the presence of nerve fibres alongside the accessory vessels. The anterior ethmoidal artery is known to traverse the anterior ethmoidal foramen with the anterior ethmoidal nerve, meaning nerve fibres may also travel through the accessory foramina of the medial wall.

Conclusion

This study provides a comprehensive assessment of the contents of the accessory ethmoidal foramina. Using a combination of dissection, histological staining and microscopic analysis, tiny branches of the anterior and posterior ethmoidal arteries were observed. The area in which these accessory foramina and vessels were observed is of high clinical relevance. These findings highlight that clinicians must be aware of the presence additional blood vessels when undertaking invasive procedures of the ethmoid bone and medial orbital wall. Further undocumented foramina, and subsequent vasculature, may therefore exist, calling for additional caution when performing surgery in this region. A safe anatomical boundary has been suggested to minimise complications from these structures.

References

1. Goldberg R, Stewart B, Rootman J (1995) *Orbital Surgery: A Conceptual Approach*, Williams and Wilkins, Baltimore.
2. KarakaŸ P, Bozkir MG, Oguz O (2003) Morphometric measurements from various reference points in the orbit of male Caucasians. *Surg Radiol Anat* 24: 358-362.
3. Mutalik A, Kolagi S, Hanji C, Ugale M, Rariam GB (2011) A Morphometric Anatomical Study Of The Ethmoidal Foramina On Dry Human Skulls. *Journal of Clinical and Diagnostic Research* 1: 28-30.
4. Abed SE, Shams P, Shen S, Addis PJ, Uddin JM (2012) A cadaveric study of ethmoidal foramina variation and its surgical significance in Caucasians. *Br J Ophthalmol* 96: 118-121.
5. Dutton J (2011) *Atlas of Clinical and Surgical Orbital Anatomy* (2nd edn) Elsevier Inc USA, pp: 88-89.
6. Erdogmus S, Govsa F (2006) The anatomic landmarks of ethmoidal arteries for the surgical approaches. *J Craniofac Surg* 17: 280-285.
7. Monjas-Cánovas I, García-Garrigós E, Arenas-Jiménez JJ, Abarca-Olivas J, Sánchez-Del Campo F, et al. (2011) [Radiological anatomy of the ethmoidal arteries: CT cadaver study]. *Acta Otorrinolaringol Esp* 62: 367-374.
8. Huanmanop T, Agthong S, Chentanez V (2007) Surgical anatomy of fissures and foramina in the orbits of Thai adults. *J Med Assoc Thai* 90: 2383-2391.
9. Lisboa Alquezar MP, Fernandez Liesa R, Lorente Munoz A, Perez Delgado L, Herrera Tolosana S, et al. (2010) Anterior ethmoidal artery at ethmoidal labyrinth: Bibliographical review of anatomical variants and references for endoscopic surgery. *Acta Otorrinolaringol Esp*, 61: 202-208.
10. Chiu T, Dunn JS (2006) An anatomical study of the arteries of the anterior nasal septum. *Otolaryngol Head Neck Surg* 134: 33-36.
11. Stephenson C (1997) *Ophthalmic Plastic, Reconstructive and Orbital Surgery*, Oxford: Butterworth-Heinemann, pp: 557-568.
12. Koh E, Frazzini VI, Kagetsu NJ (2000) Epistaxis: vascular anatomy, origins, and endovascular treatment. *AJR Am J Roentgenol* 174: 845-851.
13. Eke T, Thompson JR (2007) Serious complications of local anaesthesia for cataract surgery: a 1 year national survey in the United Kingdom. *Br J Ophthalmol* 91: 470-475.
14. Guise PA (2003) Sub-Tenon anesthesia: a prospective study of 6,000 blocks. *Anesthesiology* 98: 964-968.