



# The Southern Cross Block Technique for Intraoperative Mastectomy Analgesia

Summer Hassan<sup>1,2\*</sup>, Claudia Paterson<sup>1</sup>, Rana Alsadat<sup>1</sup>, Garth Poole<sup>1</sup>

<sup>1</sup>Department of General Surgery, Middlemore Hospital, Auckland, New Zealand; <sup>2</sup>Department of Cardiac physiology, The University of Auckland, Auckland, New Zealand

## ABSTRACT

**Purpose:** Mastectomy is a life-altering physical and psychological event for patients. Suboptimal management of immediate postoperative pain increases the risk of post-mastectomy pain syndrome. PECs II block is a regional analgesic technique expected to anesthetize the lateral chest wall. We propose an intraoperative surgeon-delivered modification to the PECs II block to improve the quality of recovery.

**Objective:** To develop a reproducible, efficient, safe intraoperative field block, and to assess its efficacy by pain scores and opiate consumption.

**Patients and methods:** The SCB was performed on 96 consecutive patients undergoing mastectomy by a single surgeon from 2020 to 2021. The block consisted of 40 ml of bupivacaine given under direct vision to five areas: pectoralis major, the interjectorily groove, pectoralis minor lateral intercostal nerves with the nerve to serratus anterior, and the medial cutaneous nerves. Patients were assessed using visual analogue pain scale from 0-10 for movement and at rest at 1,3,6,12, and 24 hours. Rescue analgesia was freely given, and the total requirements were obtained from patient notes.

**Results:** The median pain score at rest and with movement at 1 h was 0 out of 10. The median pain score at 3 h, at rest and movement, were 1 and 2, respectively. Only 28.1% of patients required second-line analgesia within the first 24 hours with average commencement at 4.8 hours. Total opioid consumption was minimal, averaging 0.42 mg of Oxynorm, 1.3 mg of Oxycodone, 1.8 mg of Sevredol, and 3.07 mg of Morphine. Only 12.5% of patients required a short course of opioids on discharge, and none returned to theatre or required pain-related readmission.

**Conclusion:** The SCB is a simple and effective technique to minimize post-mastectomy pain.

**Keywords:** Mastectomy; Analgesia; Regional blocks; Local anesthetics; Post-mastectomy pain

**Abbreviations:** OA: Osteoarthritis; CDC: Centers for Disease Control; ROM: Range Of Motion; SLSD: Single -Leg-Step-Down; KOOS: Knee Injury and Osteoarthritis and Outcome Score; ArJD: Activity-related Joint Discomfort; GCP: Good Clinical Practice; QOL: Quality Of Life; ADL: Activities of Daily Living; ANCOVA: Analysis of Covariance; ITT: Intention-To-Treat population; LOCF: Last Observation Carried Forward; Treg: regulatory T cells; DRKS: Deutsches Register Klinischer Studien; ICH: International Council for Harmonisation

## INTRODUCTION

Breast cancer is the most common type of cancer among women, affecting one in nine of women in New Zealand [1]. New Zealand has the 7<sup>th</sup> highest incidence of breast cancer worldwide [2]. Māori women have a breast cancer incidence of 125.5 per 100,000 age-standardised populations, which is the highest known breast cancer incidence of any ethnic group worldwide [3]. Pasifika women also have higher rates of breast cancer than Pākehā/European women. Mastectomy (The surgical removal of breast tissue), with or without

Axillary Node Dissection (AND) remains the treatment of choice for extensive, multifocal, multicentric breast cancer where Breast Conserving Surgery (BCS) is ineffective in achieving locoregional control [4-8]. It was performed in 56% of patients with invasive cancer in the Auckland region in the early 2000s [9]. Breast cancer surgeries induce a physiological and psychological insult, resulting in a multitude of post-operative complications. One of the most common post-operative complications is Post Mastectomy Pain (PMP), estimated to affect 20-60% of patients [10-12].

**Correspondence to:** Summer Hassan, Department of General Surgery, Middlemore Hospital, Auckland, New Zealand, E-mail: smac212@aucklanduni.ac.nz

**Received:** 21-Sep-2022, Manuscript No. JCTR-22-19326; **Editor assigned:** 23-Sep-2022, PreQC No. JCTR-22-19326 (PQ); **Reviewed:** 07-Oct-2022, QC No. JCTR-22-19326; **Revised:** 14-Oct-2022, Manuscript No. JCTR-22-19326 (R); **Published:** 21-Oct-2022, DOI:10.35248/2167-0870.22.12.511.

**Citation:** Hassan S, Paterson C, Alsadat R, Poole G (2022) The Southern Cross Block Technique for Intraoperative Mastectomy Analgesia. J Clin Trials. 12:511.

**Copyright:** © 2022 Hassan S, et al. This is an open access article distributed under the terms of the Creative Commons Attribution License, which permits unrestricted use, distribution, and reproduction in any medium, provided the original author and source are credited.

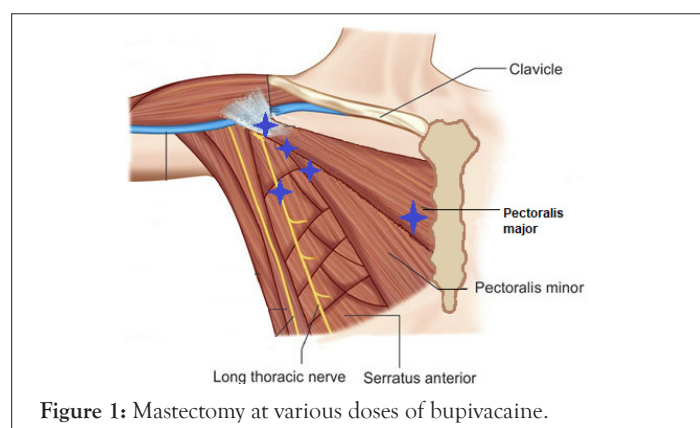
PMP has been defined by the International Association for the Study of Pain (IASP) as persistent pain soon after mastectomy/lumpectomy affecting the anterior thorax, axilla, and/or medial upper arm [13]. Although the duration of pain persistence postoperatively remains a topic of debate [14], there is a consensus that suboptimal management of the acute postoperative pain significantly increases the risk of developing PMP [15,16]. A literature review published by Larsson et al., summarises the treatment modalities for PMP [17].

The role of intraoperative local and regional anaesthetics is prophylactic and has been interrogated in several clinical trials [18]. These trials have demonstrated that regional anaesthetic agents, including thoracic paravertebral, thoracic epidural and peripheral nerve blocks, can minimize the pathological neural plasticity implicated in the progression to chronic pain [16,19-22]. Widespread adoption of these techniques is curtailed by the technical complexity and systemic complications [23]. Furthermore, an emerging method of administering regional block is the Pectoral Nerve-2 block (PECs 2 blocks). It entails Ultra Sound (US) guided, interfascial injections of local anaesthetic between the pectoralis major and minor muscles, above the serratus anterior muscle [24]. PECs block is gaining popularity owing to its effects in prolonging the duration of postoperative analgesia and decreasing the requirement for rescue analgesia [25]. Although limited data is available on the complications of PECs block, it has been associated with intravascular injection in the acromiothoracic artery and cephalic vein, as well as inducing pneumothorax in some cases [25].

The obvious limitation to adequate post mastectomy analgesia remains the inability to address all the nociceptive regions of the breast. Multimodal analgesia is the most likely solution. Enhanced Recovery After Surgery (ERAS) protocols aim to expedite patients' return to equilibrium postoperatively. ERAS protocols for mastectomy recommend using long-acting local anaesthetics e.g., Bupivacaine as an integral part of delivering multimodal analgesia [26]. This paper aims to present Southern Cross Block (SBC) technique, a consecutive series of a systematic five region field block using bupivacaine.

## Technique

At the conclusion of the mastectomy a maximal dose of bupivacaine is diluted to 40 mls and infiltrated into five areas: Pectoralis major tendon 10 mls, Interpectoral groove 10 ml, pectoralis minor tendon 5 ml, nerve to serratus 5 ml, and finally medial wound 10 ml (Figure 1). This aims to block the medial and lateral pectoral nerves, nerve to serratus anterior, as well as the medial and lateral intercostal nerves.



## METHODOLOGY

This is a single centre, single surgeon study evaluating the outcomes of the SCB mode of analgesia in 96 patients who underwent a mastectomy surgery for breast cancer from Jan 2020 to Dec 2021. Informed consent was obtained. Participants receiving any other type of blocks were excluded. Post-operative pain was assessed prospectively using Pain severity scale (0-10) at rest and upon movement.

The outcomes measured included: Time to first analgesic post operatively, Type of first Analgesic given, type and total dose of analgesics administered in the first 24 hours, Pain scores at 1, 3, 6, 12 and 24 hours on rest and movement and Analgesia administered on discharge. The collected data was analysed using IBM SPSS Statistics Version: 28.0.0.0 (SPSS Inc., Chicago, IL, USA). The Pearson correlation analysis was performed to examine the relationships among variables of interest.

## RESULTS

The study population included 96 participants, 95 females and 1 male between the ages of 29 to 89 years old, the mean age was 58.57. The ethnic background of the recruited population is summarised in Table 1. No statistically significant correlations were observed between patients' ethnicity and pain scores. The patients' BMI ranged between 17 to 52 with the mean BMI being 30.67, a positive correlation was detected between patients' BMI and the operative duration ( $r(96)=0.236$ ,  $p \leq 0.05$ ).

**Table 1:** Ethnicity summary of the study population.

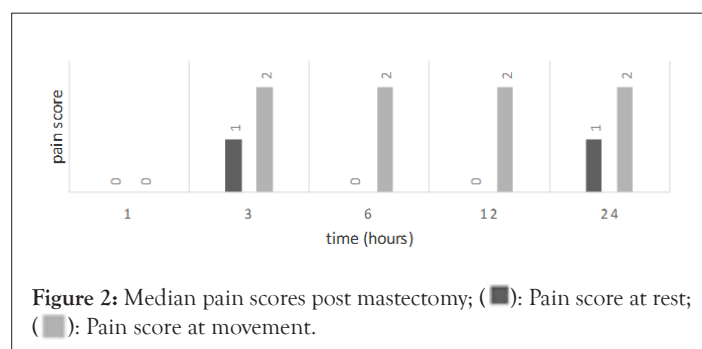
	Frequency	Percent
European	39	40.6
Maori	17	17.7
Pacific peoples	15	15.6
Asian	14	14.6
Other Ethnicity	11	11.5
Total	96	100

Of our 96 recruited participants; 50 underwent left mastectomy; 41 Right mastectomy and 5 patients had a bilateral mastectomy. AND was completed for most patient, a descriptive summary of AND level can be found in Table 2. The mean operating time was 1.12 hours (minimum: 00.38 h, maximum: 2:25 h) and the block administration took less than 3 minutes on average to perform. 39 patients (40.62%) were on analgesic agents pre-operatively for chronic pain conditions. The median pain score at rest and with movement at 1 h was 0 out of 10. Similarly, at 3 hours, the median pain scores reported were 1 and 2, at rest and movement respectively.

The pain scores reported at different time intervals are summarised in Figure 2. In our study population 67.7% of the participants received Paracetamol as the first analgesics within the first 6 hours post operatively. Only 28.1% of patients required second-line analgesia within the first 24 hours with average commencement at 4.8 hours. The total opioid consumption was minimal, averaging 0.42 mg of Oxycodone, 1.3 mg of Oxycodone, 1.8 mg of Sevredol, and 3.07 mg of Morphine (Table 3). This indicates an average oral morphine equivalent of 9.7 mg. Only 12.5% of patients required a short course of opioids on discharge, with a median of 1 day of inpatient stay. There were no injection adverse events, none returned to theatre or required pain-related readmission.

**Table 2:** Level of axillary node dissection.

		Frequency	Percent
Valid	Level 1	38	39.6
	Level 2	28	29.2
	Level 3	5	5.2
	SNB*	18	18.8
	None	7	7.3
	Total	96	100

**Table 3:** The average analgesics consumption 24 hours post mastectomy.

Drug	Weight
Paracetamol	08.42 g
NSAID	94.00 mg
Tramadol	37.00 mg
Oxynorm	00.40 mg
Oxycodone	01.32 mg
Sevredol	01.80 mg
Morphine	03.07 mg

## DISCUSSION

There is consensus on the value of optimising post mastectomy analgesia for a multitude of reasons, including the prevention of chronic pain syndromes, the detrimental consequences of pain on the patients' physiological state, the demand on nursing care, and to decrease opioid analgesics consumption inpatient, and on discharge. This is particularly important considering the overwhelming association between prescription analgesics and the number of overdose deaths [27]. Furthermore, and although controversial, some studies demonstrated a correlation between regional nerve blocks and the reduction of oncological recurrence [28,29]. The most likely answer to optimising post-operative analgesia is a multimodal approach that enables addressing the dispersed nociceptors in the region. Different types of regional blocks have been proposed, including thoracic paravertebral, Erector Spinae, Intercostal, serratus anterior, and pectoral nerves blocks, utilising different types of Local Anaesthetics (LA). Two techniques of pectoral blocks have been described: under Ultrasound (US) guidance, the Pecs I block anesthetizes both the medial pectoral nerve and the lateral pectoral nerve, addressing the interfascial region between the pectoralis major muscle and the pectoralis minor muscle at the level of the third rib. PECS II, on the other hand, anesthetizes the area between the pectoralis major and the pectoralis minor as for a Pecs I block, followed by infiltration of LA between the pectoralis minor and the serratus anterior, which will block the 3<sup>rd</sup> to 6<sup>th</sup> intercostal nerves, and the long thoracic nerve [30]. Similarly, the SCB, aims to anesthetise the medial

and lateral pectoral nerves, nerve to serratus anterior, as well as the medial and lateral intercostal nerves. It has the advantage of being a quick method not requiring US guidance. In a systematic review collating data from ten clinical trials investigating the role of wound infiltration with LA following different types of breast surgeries, six trials demonstrated statistically significant reduction in pain scores, all be it short-lasting, and four observed reductions in pain scores and opioid use [31]. The authors questioned the clinical relevance of the small, short lasting pain reduction. It is worth noting that this study results demonstrates 3-4 points of pain reduction compared to the reported average post-mastectomy pain score of 5 [32]. This represents about 50-70% reduction which is not dismissible. This finding is in keeping with other studies that demonstrated a clear value of LA infiltration in achieving adequate analgesia and opioid sparing effect [33]. Furthermore, the mean oral morphine equivalent use in this study was found to be 9.7 mg which is significantly lower than what has been reported in the literature [34]. Some of the complications reported with Paravertebral and PEC blocks include intravascular injury considering the proximity to the acromiothoracic artery and cephalic vein, as well as pneumothorax on rare occasions [25]. These risks are significantly lower with LA infiltration techniques and were not observed in our patient population.

## Study summary

Breast cancer is the most common type of cancer in women worldwide and mastectomies remain the treatment of choice where breast conserving surgery is inadequate in achieving loco regional control. Mastectomies induce a significant physiological and psychological insult, exacerbated by pain in the acute post-operative period. Under management of acute post mastectomy pain has been associated with worse outcomes and the development of chronic post mastectomy pain syndromes.

## CONCLUSION

This study, simply asks the question of whether infiltrating local anaesthetic at specific five systematic points under direct vision by the surgeon at the conclusion of the operation, would result into adequate analgesic effect post operatively. The Southern Cross block is a technique used to target the Medial and lateral pectoral nerves, Medial and lateral intercostal nerves as well as the long thoracic nerve by infiltration Bupivacaine at 5 points at the conclusion of the surgery. It is delivered in less than 3 minutes, has excellent analgesic effect, and is not associated with any significant adverse events. This pilot study needs further validation through a prospective controlled trial to assess whether the Southern Cross technique is superior to the currently used methods including PECS II block. The SCB is easy to perform, safe, and it provides significant analgesic effect as demonstrated by over 50% reduction in acute post-mastectomy pain scores and opiate intake.

## CONSENT AND ETHICS APPROVAL

All patients consented as per good clinical practice and ethics approval obtained.

## REFERENCES

1. Breast cancer in New Zealand. Breast cancer foundation; 2022.
2. The Facts. Breast Cancer Cure; 2014.
3. Seneviratne S, Campbell I, Scott N, Coles C, Lawrenson R. Treatment delay for Māori women with breast cancer in New Zealand. *Ethn Health*. 2015;20(2):178-193.

4. Neave L, Harvey V, Benjamin C, Thompson P, Pellett O, Whitlock J, et al. The Auckland breast cancer register: A special project of the Auckland breast cancer study group. *N Z Med J*. 2003;116(1184):1-12.
5. Franceschini G, Sanchez AM, Di Leone A, Magno S, Moschella F, Accetta C, et al. New trends in breast cancer surgery: a therapeutic approach increasingly efficacy and respectful of the patient. *G Chir*. 2015;36(4):145-152.
6. Kurtz JM, Jacquemier JO, Amalric RO, Brandone HE, Ayme YV, Hans DA, et al. Breast-conserving therapy for macroscopically multiple cancers. *Ann Surg*. 1990;212(1):38-44.
7. Lagendijk M, van Maaren MC, Saadatmand S, Strobbe LJ, Poortmans PM, Koppert LB, et al. Breast conserving therapy and mastectomy revisited: Breast cancer-specific survival and the influence of prognostic factors in 129,692 patients. *Int J Cancer*. 2018;142(1):165-175.
8. Sakorafas GH, Farley DR. Optimal management of ductal carcinoma in situ of the breast. *Surg Oncol*. 2003;12(4):221-40.
9. Leopold KA, Recht A, Schnitt SJ, Connolly JL, Rose MA, Silver B, et al. Results of conservative surgery and radiation therapy for multiple synchronous cancers of one breast. *Int J Radiat Oncol Biol Phys*. 1989;16(1):11-16.
10. de Menezes Couceiro TC, Valença MM, Raposo MC, de Orange FA, Amorim MM. Prevalence of post-mastectomy pain syndrome and associated risk factors: A cross-sectional cohort study. *Pain Manag Nurs*. 2014;15(4):731-737.
11. Vilholm OJ, Cold S, Rasmussen LA, Sindrup SH. The postmastectomy pain syndrome: An epidemiological study on the prevalence of chronic pain after surgery for breast cancer. *Br J Cancer*. 2008;99(4):604-10.
12. Wang L, Guyatt GH, Kennedy SA, Romerosa B, Kwon HY, Kaushal A, et al. Predictors of persistent pain after breast cancer surgery: a systematic review and meta-analysis of observational studies. *CMAJ*. 2016;188(14):E352-61.
13. Classification of chronic pain. Descriptions of chronic pain syndromes and definitions of pain terms; Prepared by the International Association for the Study of Pain, Subcommittee on Taxonomy. *Pain Suppl*. 1986;3:S1-226.
14. Waltho D, Rockwell G. Post-breast surgery pain syndrome: Establishing a consensus for the definition of post-mastectomy pain syndrome to provide a standardized clinical and research approach: A review of the literature and discussion. *Can J Surg*. 2016;59(5):342-350.
15. Bruce J, Thornton AJ, Powell R, Johnston M, Wells M, Heys SD, et al. Psychological, surgical, and sociodemographic predictors of pain outcomes after breast cancer surgery: A population-based cohort study. *Pain*. 2014 Feb 1;155(2):232-43.
16. Wang L, Guyatt GH, Kennedy SA, Romerosa B, Kwon HY, Kaushal A, et al. Predictors of persistent pain after breast cancer surgery: a systematic review and meta-analysis of observational studies. *CMAJ*. 2016;188(14):E352-61.
17. Larsson IM, Ahm Sørensen J, Bille C. The Post-mastectomy Pain Syndrome: A Systematic Review of the Treatment Modalities. *Breast J*. 2017;23(3):338-43.
18. Humble SR, Dalton AJ, Li L. A systematic review of therapeutic interventions to reduce acute and chronic post-surgical pain after amputation, thoracotomy or mastectomy. *Eur J Pain*. 2015;19(4):451-465.
19. Woolf CJ, Salter MW. Neuronal plasticity: Increasing the gain in pain. *Science*. 2000;288(5472):1765-1768.
20. Moller JF, Nikolajsen L, Rodt SA, Ronning H, Carlsson PS. Thoracic paravertebral block for breast cancer surgery: a randomized double-blind study. *Anesth Analg*. 2007;105(6):1848-1851.
21. Doss NW, Ipe J, Crimi T, Rajpal S, Cohen S, Fogler RJ, et al. Continuous thoracic epidural anesthesia with 0.2% ropivacaine versus general anesthesia for perioperative management of modified radical mastectomy. *Anesth Analg*. 2001;92(6):1552-1557.
22. Kolawole IK, Adesina MD, Olaoye IO. Intercostal nerves block for mastectomy in two patients with advanced breast malignancy. *J Natl Med Assoc*. 2006 Mar;98(3):450-453.
23. Blanco R, Fajardo M, Maldonado TP. Ultrasound description of Pecs II (modified Pecs I): A novel approach to breast surgery. *Rev Esp Anesthesiol Reanim*. 2012;59(9):470-5.
24. Versyck B, van Geffen GJ, Chin KJ. Analgesic efficacy of the Pecs II block: A systematic review and meta-analysis. *Anaesthesia*. 2019;74(5):663-673.
25. Kulhari S, Bharti N, Bala I, Arora S, Singh G. Efficacy of pectoral nerve block versus thoracic paravertebral block for postoperative analgesia after radical mastectomy: A randomized controlled trial. *Br J Anaesth*. 2016;117(3):382-386.
26. Rojas KE, Fortes TA, Flom PL, Manasseh DM, Andaz C, Borgen PL. Mastectomy is no longer an indication for postoperative opioid prescription at discharge. *Am J Surg*. 2019;218(4):700-705.
27. Wilson N, Kariisa M, Seth P, Smith IV H, Davis NL. Drug and opioid-involved overdose deaths—United States, 2017–2018. *Morbidity and Mortality Weekly Report*. 2020 Mar 3;69(11):290.
28. Exadaktylos AK, Buggy DJ, Moriarty DC, Mascha E, Sessler DI. Can anesthetic technique for primary breast cancer surgery affect recurrence or metastasis?. *Anesthesiology*. 2006;105(4):660-664.
29. Sessler DI, Pei L, Huang Y, Fleischmann E, Marhofer P, Kurz A, et al. Recurrence of breast cancer after regional or general anaesthesia: a randomised controlled trial. *The Lancet*. 2019;394(10211):1807-1815.
30. Aziz MB, Mukhdomi T. Regional anesthesia for breast reconstruction. In: *StatPearls*. 2022.
31. Byager N, Hansen MS, Mathiesen O, Dahl JB. The analgesic effect of wound infiltration with local anaesthetics after breast surgery: A qualitative systematic review. *Acta Anaesthesiol Scand*. 2014;58(4):402-410.
32. Fecho K, Miller NR, Merritt SA, Klauber-DeMore N, Hultman CS, Blau WS. Acute and persistent postoperative pain after breast surgery. *Pain Med*. 2009;10(4):708-15.
33. Campbell I, Cavanagh S, Creighton J, French R, Banerjee S, Kerr E, Shirley R. To infiltrate or not? Acute effects of local anaesthetic in breast surgery. *ANZ J Surg*. 2015;85(5):353-357.
34. Offodile AC, Gu C, Boukovalas S, Coroneos CJ, Chatterjee A, Largo RD, et al. Enhanced recovery after surgery (ERAS) pathways in breast reconstruction: Systematic review and meta-analysis of the literature. *Breast Cancer Res Treat*. 2019;173(1):65-77.