

# The Neutrophil-to-Lymphocyte Ratio as A Prognostic Factor For Long-Term Interleukin-2 Use in Renal Cell Carcinoma

Takashi Nagai<sup>1</sup>, Takehiko Okamura<sup>1\*</sup>, Yutaro Tanaka<sup>2</sup>, Daichi Kobayashi<sup>1</sup>, Takahiro Kobayashi<sup>1</sup>, Hidetoshi Akita<sup>1</sup> and Takahiro Yasui<sup>2</sup>

<sup>1</sup>Department of Urology, Anjo Kosei Hospital, Anjo, Japan

<sup>2</sup>Department of Nephro-Urology, Nagoya City University, Graduate School of Medical Sciences, Nagoya, Japan

\*Corresponding author: Takehiko Okamura, Department of Urology, Anjo Kosei Hospital 28 Higashihirookute, Anjo-cho, Anjo, Aichi-446-0026, Japan, Tel: +81-566-75-2111; Fax: +81566-76-4335; E-mail: hiko2546@kosei.anjo.aichi.jp

Received date: November 08, 2017; Accepted date: November 20, 2017; Published date: November 25, 2017

Copyright: © 2017 Nagai T, et al. This is an open-access article distributed under the terms of the Creative Commons Attribution License, which permits unrestricted use, distribution, and reproduction in any medium, provided the original author and source are credited.

\* These authors contributed equally to this work.

## Abstract

The neutrophil-to-lymphocyte ratio (NLR), a measure of systemic inflammation, has been reported to be a predictive parameter of patient prognosis. We speculated that the NLR is decreased in renal cell carcinoma (RCC) patients in whom interleukin (IL)-2 is effective. In this study, we retrospectively examined the usefulness of the NLR as a prognostic factor using three cases of RCC treated with long-term IL-2. In all three cases, the NLR remained less than 2.7 during IL-2 treatment, suggesting its effectiveness as a marker. During interferon- $\alpha$  or molecular targeted drug therapy, the NLR was unstable, regardless of treatment effectiveness, but a sudden rise in the NLR tended to suggest massive radiographic progression and worse prognosis. The results suggested that the NLR might serve as a useful marker for therapies when determining prognosis.

## Key words:

Interleukin-2; Renal cell carcinoma; Prognosis; Neutrophil-lymphocyte ratio

## Introduction

In the 1990s, interferon alpha (IFN- $\alpha$ ) and interleukin 2 (IL-2) were approved for the treatment of renal cell carcinoma (RCC). Moreover, in the 2000s, the introduction of molecular targeted drugs greatly improved prognosis in RCC patients [1]. Molecular targeted drugs are now commonly used for patient therapies instead of cytokines. Sorafenib, sunitinib, everolimus, temsirolimus, and pazopanib are now available in most countries and used without initial cytokine therapy. Although sequential therapy with molecular targeted drugs has attracted attention, no clear parameter exists to judge its effectiveness. By contrast, the effectiveness of immunotherapy, which sets the transverse axis of the T cell, can be evaluated by the appearance of circulating anti programmed death 1 (PD-1) antibodies [2].

The neutrophil-to-lymphocyte ratio (NLR), a measure of systemic inflammation, has been reported as a predictive parameter of patient prognosis in various cancers, including RCC [3]. Although RCC is considered an immunogenic cancer, immunotherapy is not always effective. We speculated that the NLR is decreased in RCC patients in whom IL-2 is effective. In this study, we retrospectively examined the usefulness of the NLR as a prognostic factor in three cases of metastatic RCC (mRCC) treated with long-term IL-2.

## Patients and Methods

We reviewed three patients with RCC who were administered IL-2 for over 3 years in our institution. All patients underwent total

nephrectomy and subsequent regular radiographic follow up. Adjuvant therapy was started when imaging showed recurrence. The patients were administered IL-2 for 42, 38, and 92 months, respectively. IFN- $\alpha$  was administered in all cases prior to IL-2 treatment, and the patients were switched to molecular targeted drugs after IL-2 administration. Each patient continued cancer treatment for more than 3 years after starting IL-2. Disease progression was evaluated by radiographic assessment according to the response evaluation criteria in solid tumors (RECIST) criteria, and the NLR was calculated by blood figure analysis of peripheral blood during treatment. The examination of the relationship between the NLR transition and disease progression was compared. This research was performed under approval of the institutional review board of Anjo Kosei Hospital.

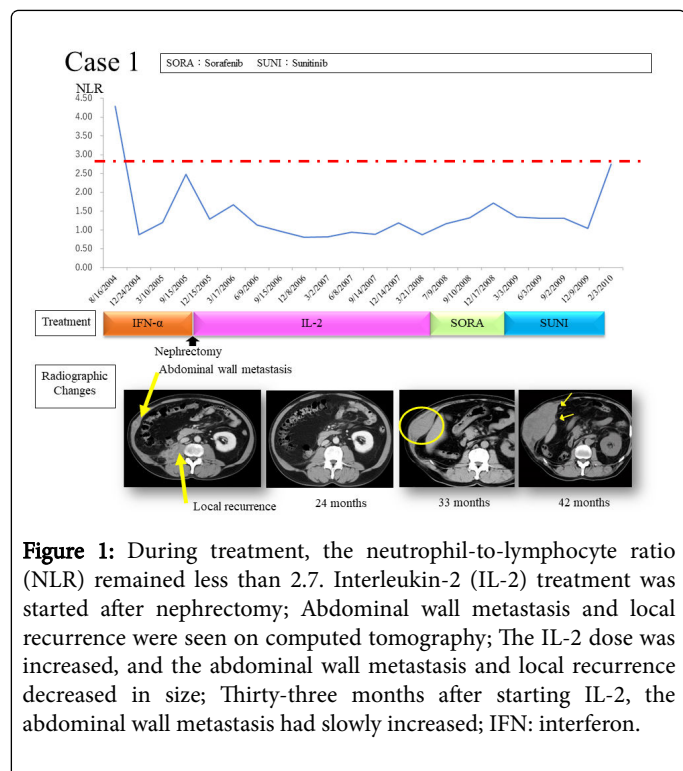
## Results

The characteristics of all three patients are shown in Table 1. All patients were men. They underwent nephrectomy, and the pathological results indicated clear cell carcinoma.

Case 3 presented with no metastatic lesions. The details of the treatments, radiographic changes, and shift of the NLR in each case are shown in Figures 1-3.

In case 1, IFN- $\alpha$  was administered for 14 months and metastatic lesions decreased. Since drug-induced hepatitis occurred, IFN- $\alpha$  was discontinued and the patient underwent nephrectomy. Though IL-2 administration was started after nephrectomy, abdominal wall metastasis and local recurrence were seen on computed tomography. The IL-2 dose was increased, and both the abdominal wall metastasis and local recurrence decreased in size. Thirty months after starting IL-2, lung metastasis was observed, but the abdominal wall metastasis and local recurrence were still diminished. Three months later, the

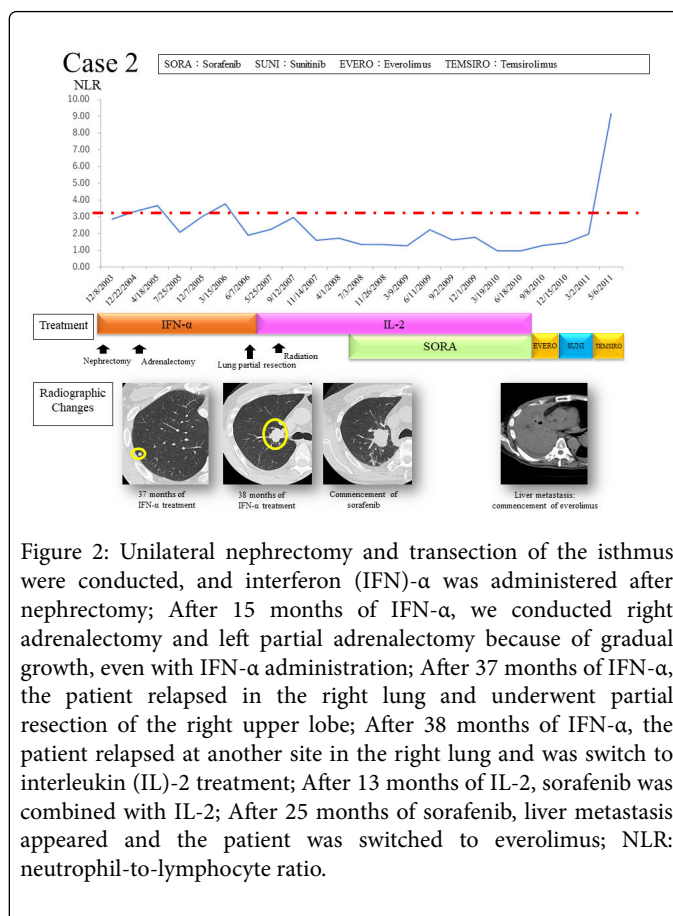
abdominal wall metastasis had enlarged slightly, although the lung metastasis had not increased in size. After 42 months of IL-2 treatment, the patient was switched to sorafenib. After 8 months, the abdominal wall and lung metastases had increased, and the patient was switched to sunitinib. After 12 months on sunitinib, the abdominal wall and lung metastases had increased and peritoneal metastasis was seen, and the patient died.



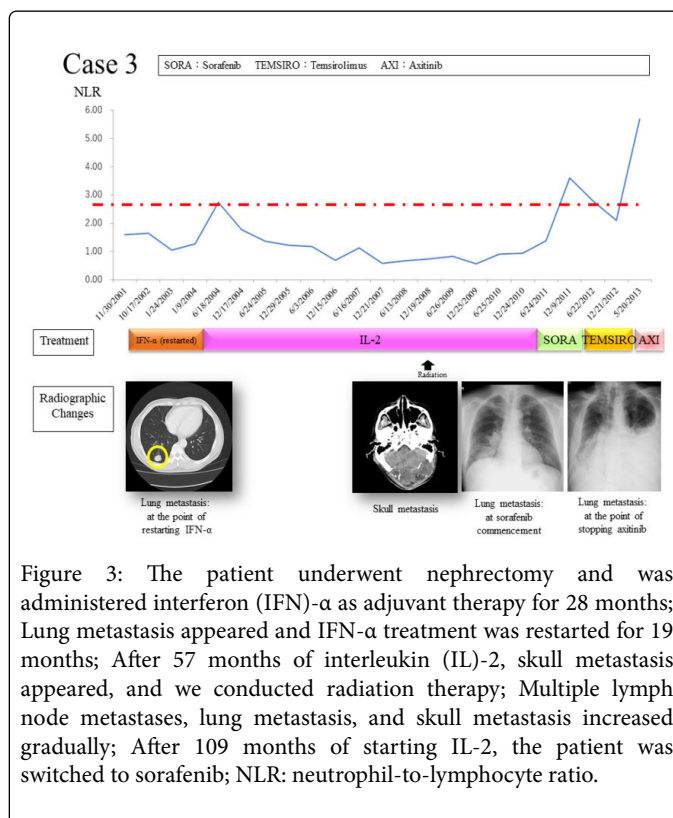
**Figure 1:** During treatment, the neutrophil-to-lymphocyte ratio (NLR) remained less than 2.7. Interleukin-2 (IL-2) treatment was started after nephrectomy; Abdominal wall metastasis and local recurrence were seen on computed tomography; The IL-2 dose was increased, and the abdominal wall metastasis and local recurrence decreased in size; Thirty-three months after starting IL-2, the abdominal wall metastasis had slowly increased; IFN: interferon.

Case No.	1	2	3
Age at diagnosis	60	58	51
Sex	Male	Male	Male
Past Medical History	hypertension diabetes	horseshoe kidney chronic thyroiditis diabetes	-
TNM	pT1bN2M1	pT2N1M1	pT3aN0M0
Metastatic Sites	lung retroperitoneum	lung adrenal gland	-
Histological Diagnosis	Clear cell carcinoma	Clear cell carcinoma	Clear cell carcinoma
Operation	Nephrectomy	Nephrectomy Transection of the isthmus	Nephrectomy

**Table 1:** Baseline patient characteristics.



**Figure 2:** Unilateral nephrectomy and transection of the isthmus were conducted, and interferon (IFN)-α was administered after nephrectomy; After 15 months of IFN-α, we conducted right adrenalectomy and left partial adrenalectomy because of gradual growth, even with IFN-α administration; After 37 months of IFN-α, the patient relapsed in the right lung and underwent partial resection of the right upper lobe; After 38 months of IFN-α, the patient relapsed at another site in the right lung and was switch to interleukin (IL)-2 treatment; After 13 months of IL-2, sorafenib was combined with IL-2; After 25 months of sorafenib, liver metastasis appeared and the patient was switched to everolimus; NLR: neutrophil-to-lymphocyte ratio.



**Figure 3:** The patient underwent nephrectomy and was administered interferon (IFN)-α as adjuvant therapy for 28 months; Lung metastasis appeared and IFN-α treatment was restarted for 19 months; After 57 months of interleukin (IL)-2, skull metastasis appeared, and we conducted radiation therapy; Multiple lymph node metastases, lung metastasis, and skull metastasis increased gradually; After 109 months of starting IL-2, the patient was switched to sorafenib; NLR: neutrophil-to-lymphocyte ratio.

In case 2, the patient had horseshoe kidney. Unilateral nephrectomy and transection of the isthmus were conducted, and IFN- $\alpha$  was administered after nephrectomy. The lung metastasis decreased with IFN- $\alpha$  treatment, but metastases in both adrenal glands increased. After 15 months, we conducted right adrenalectomy and left partial adrenalectomy because of gradual growth, even with IFN- $\alpha$  administration. After 37 months of IFN- $\alpha$  treatment, the patient relapsed in the right lung and underwent partial resection of the right upper lobe. After 1 month, lung metastasis was observed in another site in the right lung, and the patient was switched to IL-2. After 1 month of IL-2, radiation therapy was administered for lung metastasis. After 13 months of IL-2, sorafenib was combined with IL-2 treatment. After 25 months of sorafenib treatment, a liver metastasis appeared, and IL-2 and sorafenib were discontinued and the patient was switched to everolimus. The patient was switched to sunitinib after 1 month due to renal dysfunction. After 5 months of sunitinib treatment, the patient was switched to temsirolimus due to the appearance of brain metastasis. One month after starting temsirolimus, it was stopped due to renal dysfunction and worsening pain, and the patient died after 3 months.

In case 3, the patient underwent nephrectomy, and IFN- $\alpha$  was administered after 28 months of nephrectomy. IFN- $\alpha$  was stopped because of his wish after 18 months of treatment. Lung metastasis appeared and the patient received IFN- $\alpha$  again for 19 months. However, even after the second IFN- $\alpha$  administration, the lung metastasis worsened, and he received IL-2 treatment.

After 57 months of IL-2 treatment, skull metastasis appeared, and radiation therapy was administered to the skull lesion. Thereafter, multiple lymph node metastases, lung metastasis, and skull metastasis increased gradually. After 109 months of IL-2, the patient was switched to sorafenib. After 6 months of sorafenib, the multiple metastases increased in size and the patient was switched to temsirolimus. After 14 months of temsirolimus treatment, the patient was switched to axitinib. After 3 months of axitinib treatment, the patient died.

All of the patients were switched to molecular targeted drugs (2-4 different drugs before death), and each continued cancer treatment for more than 3 years after the start of IL-2 treatment. IL-2 was continued for more than 50 months, and one patient received IL-2 for 109 months. Furthermore, molecular targeted drugs were continued for more than 1 year after IL-2 termination in all cases. The NLR remained less than 2.7 during IL-2 treatment in all cases.

## Discussion

Our study has demonstrated that the NLR could be a useful marker for therapeutic response when determining prognosis in patients with RCC; however, we examined only three cases.

Inflammation can affect every aspect of tumor development and progression, as well as the response to therapy [4]. Various biomarkers of inflammation, such as C-reactive protein (CRP) kinetics [5], CRP/albumin ratio [6], platelet count [7], and the NLR have been reported as significant prognostic factors of RCC. Since these biomarkers are easily obtained from the patient's peripheral blood and are noninvasive and low cost, they are useful in terms of being less of a burden on patients. In 2001, Zahorec first reported that the NLR is a parameter that indicates the inflammation and stress of the entire body under critical conditions, and it can be assessed quickly and easily [8]. Since then, it has been widely shown that an increase in the NLR prior to medical treatment signifies a poor prognosis for various cancers, such

as colorectal cancer, gastric cancer, and ovarian cancer [9-11]. Ohno et al. reported in 2010 that the non-recurrence probability of survival from RCC was high in cases where the NLR was less than 2.7 before treatment, and that the NLR was an independent prognostic factor [12]. They also found that multivariate analysis revealed the NLR and T stage as significant predictors in RCC patients [12]. Unfortunately, there have been no further studies concerning the NLR in RCC. Although we only examined three cases, this study supports their consensus.

Naito et al. reported that IL-2-centered immunotherapy brought favorable treatment results in Japanese patients with mRCC [13]. There was no mention of the NLR in their report, but we speculate that the standard immunotherapy treatment in Japan maintains the NLR at a low level, extending patient survival.

## Conclusion

Our results suggest that the NLR might serve as a useful marker for therapies in determining the prognosis of patients with RCC. Further studies, including a prospective study in Japan and comparison with large-scale databases, are necessary. In conclusion, the NLR is easily assessed clinically and is a cost-effective biomarker in RCC and potentially other malignancies.

## References:

1. Hutson TE (2011) Targeted therapies for the treatment of metastatic renal cell carcinoma: clinical evidence. *Oncologist* 2: 14-22.
2. Motzer RJ, Escudier B, McDermott DE, George S, Hammers HJ, et al. (2015) Nivolumab versus everolimus in advanced renal-cell carcinoma. *N Engl J Med* 373: 1803-1813.
3. Hu K, Lou L, Ye J, Zhang S (2015) Prognostic role of the neutrophil-lymphocyte ratio in renal cell carcinoma: a meta-analysis. *BMJ Open* 5: e006404.
4. Grivennikov SI, Greten FR, Karin M (2010) Immunity, inflammation, and cancer. *Cell* 140: 883-899.
5. Saito K, Tatokoro M, Fujii Y, Iimura Y, Koga F, et al. (2009) Impact of C-reactive protein kinetics on survival of patients with metastatic renal cell carcinoma. *Eur Urol* 55: 1145-1153.
6. Chen Z, Shao Y, Fan M, Zhuang Q, Wang K, et al. (2015) Prognostic significance of preoperative C-reactive protein: albumin ratio in patients with clear cell renal cell carcinoma. *Int J Clin Exp Pathol* 8: 14893-14900.
7. Choi JY, Ko YH, Song PH (2016) Clinical significance of preoperative thrombocytosis in patients who underwent radical nephrectomy for nonmetastatic renal cell carcinoma. *Investig Clin Urol* 57: 324-329.
8. Zahorec R (2001) Ratio of neutrophil to lymphocyte counts—rapid and simple parameter of systemic inflammation and stress in critically ill. *Bratisl Lek Listy* 102: 5-14.
9. Chen J, Hong D, Zhai Y, Shen P (2015) Meta-analysis of associations between neutrophil-to-lymphocyte ratio and prognosis of gastric cancer. *World J Surg Oncol* 13: 122.
10. Tsai PL, Su WJ, Leung WH, Lai CT, Liu CK (2016) Neutrophil-lymphocyte ratio and CEA level as prognostic and predictive factors in colorectal cancer: A systematic review and meta-analysis. *J Cancer Res Ther* 12: 582-589.
11. Huang QT, Zhou L, Zeng WJ, Ma QQ, Wang W, et al. (2017) Prognostic Significance of Neutrophil-to-Lymphocyte Ratio in Ovarian Cancer: A Systematic Review and Meta-Analysis of Observational Studies. *Cell Physiol Biochem* 41: 2411-2418.
12. Ohno Y, Nakashima J, Ohori M, Hatano T, Tachibana M (2010) Pretreatment neutrophil-to-lymphocyte ratio as an independent predictor of recurrence in patients with nonmetastatic renal cell carcinoma. *J Urol* 184: 873-878.

13. Naito S, Yamamoto N, Takayama T, Muramoto M, Shinohara N, et al. (2010) Prognosis of Japanese metastatic renal cell carcinoma patients in the cytokine era: a cooperative group report of 1463 patients. *Eur Urol* 57: 317-325.