

The Inevitable: Donor Derived Chronic Myeloid Leukemia Following Matched Related Stem Cell Transplant for Acute Lymphoblastic Leukemia

Shatha Farhan^{1*}, Jawad Sheqwar¹, Brandon Shaw², Susan Michalowski², Milena Cankovic³, Edward Peres¹ and Nalini Janakiraman¹

¹Blood and Marrow Stem Cell Transplant Program, Henry Ford Hospital, Detroit, MI 48202, USA

²Department of Medical Genetics, Henry Ford Hospital, Detroit, MI 48202, USA

³Molecular Pathology and Genomic Medicine, Henry Ford Hospital, Detroit, MI 48202, USA

Abstract

Donor Derived Cell Leukemia (DCL) is a rare complication of Hematopoietic Stem Cell Transplantation (HSCT). DCL represents a unique form of leukemogenesis in which donor cells become transformed or proliferate following engraftment in a foreign host environment. We report a 58-year old patient with B-cell acute Lymphocytic leukemia who underwent an allogeneic HSCT from his Human Leukocyte Antigens (HLA)-matched sibling. Three months after HSCT, chromosomal analysis revealed a female karyotype with a (9;22) translocation. This was confirmed with Fluorescence in Situ Hybridization and polymerase chain reaction studies in the recipient and the donor confirming the transmission of occult leukemia.

Introduction

Allergenic hematopoietic stem cell transplant (HSCT) is considered an effective treatment strategy for Acute Lymphoblastic Leukemia (ALL) especially in patients with high-risk features. Post HSCT, secondary leukemia/ myelodysplastic Syndrome (MDS) that is derived from donor cell origin develops, thus being designated donor cell leukemia (DCL). DCL is a rare phenomenon, which was probably under-diagnosed for many years and may represent up to 5% of all leukemia relapses post- HSCT [1].

Here, we present a patient who developed donor cell- derived Chronic Myeloid Leukemia (CML) three months after allogeneic HSCT from a human leukocyte antigen (HLA)-matched related donor for ALL.

Case Report

A 58-year-old male patient was diagnosed with B-cell ALL in April 2012. Cytogenetic evaluation of a bone marrow specimen by chromosomal analysis revealed a hypodiploid karyotype (Figure 1A). Clonality was confirmed in approximately 80% of nuclei by Fluorescence in Situ Hybridization (FISH) analysis (Figure 1B-1E). FISH analysis using probes 9q34 (ABL), 11q23 (MLL), and 22q11.2 (BCR) was also performed. At least two hundred interphase cells were scored for each probe and BCR-ABL t(9;22) and MLL (11q23) were found to be normal. Cerebrospinal fluid analysis was negative for leukemic involvement. He was treated with five cycles of a 5-drug chemotherapy regimen with intrathecal prophylaxis. He attained a morphologically complete remission but had minimal residual disease by flow-cytometry. He was evaluated for allogeneic HSCT and his sister was found to be an HLA-identical donor. Prior to peripheral-blood stem- cell mobilization with granulocyte colony-stimulating factor, the donor's evaluation and hematologic studies were unremarkable. In October 2012, he received fludarabine and melphalan as a conditioning regimen followed by stem cell infusion from his HLA identical sibling. Tacrolimus and mini-dose methotrexate were used as Graft Versus Host Disease (GVHD) prophylaxis.

One month post-HSCT, bone marrow chromosome analysis showed a female karyotype and the Short tandem repeats (STRs) analysis was consistent with donor DNA. Nearly 3 months post-HSCT, Chromosome analysis using standard cytogenetic techniques from a bone marrow aspirate showed a female (donor) karyotype with a new clone that has (9;22) translocation in 38% of the metaphases examined

(Figure 2A). All the cells that had the Philadelphia chromosome were XX, suggesting donor origin of this cell clone. FISH analysis to detect minimum residual ALL disease was normal, although FISH analysis using dual- color dual-fusion probes specific for the t(9;22) confirmed the BCR-ABL fusion in 16.5% of nuclei examined (Figure 2B). To confirm this unusual finding, reverse transcriptase -polymerase chain reaction (RT-PCR) for BCR-ABL [t(9;22), p210] and STR analysis were performed. STR analysis demonstrated the presence of Donor DNA only. RT-PCR was positive for BCR-ABL fusion transcript with a ratio of BCR-ABL transcripts to control gene transcripts of 0.0461 in the peripheral blood of the recipient. Retrospective FISH analysis performed on frozen stem cells from the donor, showed the presence of the BCR-ABL fusion.

The donor underwent a repeat evaluation of hematologic parameters, which revealed her complete blood count with differential to be normal. A Bone marrow biopsy performed on the donor revealed normo-cellular marrow by morphology. There was no increase in myeloid precursors or any increase in production in leukopoiesis, erythropoiesis, or megakaryopoiesis. However, chromosome analysis revealed that 70% of metaphases examined carried a t(9;22)(q34;q11.2). This result was confirmed by FISH analysis. The ratio of BCR/ABL transcripts to control gene transcripts was 0.4326 in peripheral blood of the donor.

Collectively, these results were consistent with donor derived Chronic Myeloid Leukemia (ddCML) in the recipient and a preclinical CML in the donor. The previously undetected CML clone in the donor was inadvertently transmitted to recipient by HSCT. Both patient and donor were started on a Tyrosine Kinase Inhibitor (TKI). Now almost

***Corresponding author:** Shatha Farhan, Blood and Marrow Stem Cell Transplant Program, Henry Ford Hospital, CFP5, 2799 W Grand Blvd, Detroit, MI 48202, USA, Tel: 313-713-3910; Fax: 313-916-7911; E-mail: sfarhan1@hfhs.org

Received December 03, 2013; **Accepted** December 26, 2013; **Published** December 28, 2013

Citation: Farhan S, Sheqwar J, Shaw B, Michalowski S, Cankovic M, et al. (2013) The Inevitable: Donor Derived Chronic Myeloid Leukemia Following Matched Related Stem Cell Transplant for Acute Lymphoblastic Leukemia. J Hematol Thromb Dis 2: 124 doi: [10.4172/2329-8790.1000124](https://doi.org/10.4172/2329-8790.1000124)

Copyright: © 2013 Farhan S, et al. This is an open-access article distributed under the terms of the Creative Commons Attribution License, which permits unrestricted use, distribution, and reproduction in any medium, provided the original author and source are credited.

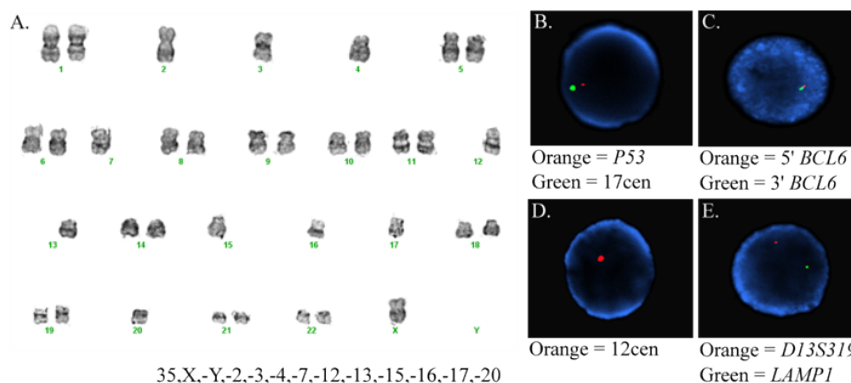


Figure 1: Cytogenetic findings (pre-Hematopoietic Stem Cell Transplant [HSCT]) consistent with severe hypodiploid Acute Lymphoblastic Leukemia (ALL). Panel A shows karyogram revealing hypodiploid cell. Panels B, C, D and E: fluorescence in situ hybridization (FISH) images using probes specific for *TP53* and chromosome 17 centromere (B), *BCL6* (C), chromosome 12 centromere (D), and 13q34 and 13q14 (E), showing pattern consistent with monosomy for chromosomes 3, 12, 13 and 17.

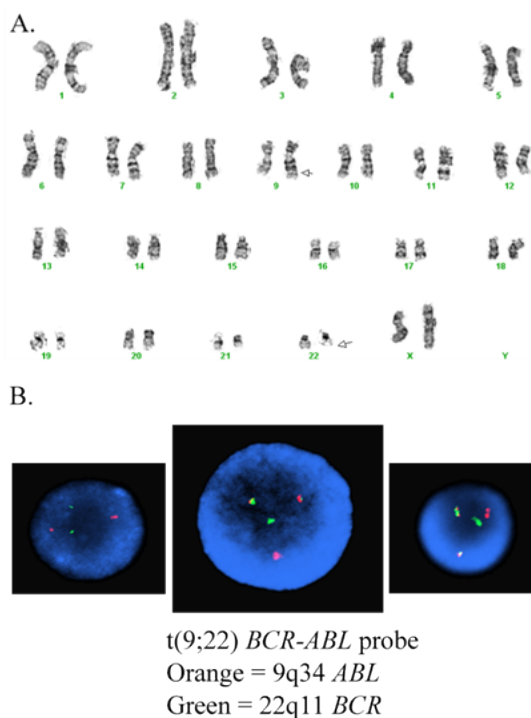


Figure 2: Cytogenetic findings (post-Hematopoietic Stem Cell Transplant [HSCT]) consistent with donor derived Chronic Myeloid Leukemia (CML). Panel A: Karyogram showing female cell with a 9;22 translocation [46,XX,t(9;22)(q34;q11.2)]. Panel B: fluorescence in situ hybridization (FISH) results showing a signal pattern consistent with *BCR-ABL* fusion.

8 months after HSCT, the recipient is doing well with stable blood counts and the ratio of *BCR/ABL* transcripts to control gene transcripts is 0.0000. In addition, flow-cytometry is negative for any evidence of ALL.

Discussion

Since the first publication describing a case of DCL in 1971 [2], several other cases have been reported with an increase in incidence noticed in recent years. This is probably due to advances in diagnostic technology and molecular chimerism monitoring [1]. However, etiology is still highly speculative because of the heterogeneity of

documented cases. Our case, however, is one of the rare cases of DCL secondary to an occult or preclinical leukemia in the donor that we were able to demonstrate by Cytogenetic and molecular techniques.

The transmission of MDS [3,4], acute myeloid leukemia [5], T-cell lymphoma [6], two cases of CML [7,8] and other hematologic malignancies [9] through bone marrow transplantation has been reported previously. The proper diagnosis of DCL is imperative because it has implications in regards to therapeutic options. In DCL seeking to enhance an allogeneic Graft Versus Leukemia (GVL) effect would not have the same therapeutic effect as in standard recipient-

derived relapses [1]. Our case is a sex-mismatched HSCT, however, it is known that leukemic blasts from male patients sometimes lose their Y-chromosome and that doubling of an X-chromosome can also occur. If this happens in the setting of allogeneic HSCT with a female donor in a male patient, one might erroneously suspect the development of leukemia in donor cells [10,11]. With the addition of molecular techniques using different polymorphism markers as in STR chimerism analysis should reliably confirm DCL in most cases. It's important to point out that there have been reports of normal donors harboring the BCR-ABL translocation [12,13]. However, some of these reports were generated via techniques that are not used clinically, and in this case the t(9;22) was detected in the donor by chromosome analysis, FISH and RT-PCR.

Overall, the natural history of DCL appears to have an aggressive course and poor prognosis. Because of the small number of reports, the optimal therapeutic modality for this disease remains unknown. Baron et al. reported a case of ddCML where the recipient was treated with imatinib, and a complete cytogenetic and molecular remission was achieved [7]. We treated our patient with dasatinib because of the history of ALL and the new CML clone. The reason to initiate dasatinib therapy was based on the inert properties of the multi-target kinase inhibitor. Dasatinib inhibits Src, ephrin receptor kinase, platelet-derived growth factor receptor, and Kit, in addition to its properties of inhibiting Bcr-Abl [14]. Src, in particular, has been implicated in leukemogenesis.

DCL is an infrequent complication of HSCT and represents a unique form of leukemo-genesis in which donor derived cells become transformed or proliferate following engraftment in a foreign host environment. With more sophisticated molecular techniques to detect DCL, there will be an increase in its incidence in transplant recipients from related and unrelated donors. This would help identify risk factors, biologic behavior and optimal therapy. In the majority of cases, donors for patients with DCL do not develop leukemia suggesting that there is involvement of a host factor in promoting DCL [15,16]. However in other cases, such as the one presented here, it is secondary to an occult undetected malignancy in the donor, and both donor and recipient will have the disease. Unfortunately it's difficult to avoid transmission of occult disease, as it is not cost effective to test for every mutation or perform every molecular test on donors with normal hematologic screening parameters.

References

1. Wiseman DH (2011) Donor cell leukemia: a review. *Biol Blood Marrow Transplant* 17: 771-789.
2. Fialkow PJ, Thomas ED, Bryant JI, Neiman PE (1971) Leukaemic transformation of engrafted human marrow cells in vivo. *Lancet* 1: 251-255.
3. Mielcarek M, Bryant E, Loken M, Torok-Storb B, Storb R (1999) Haemopoietic reconstitution by donor-derived myelodysplastic progenitor cells after haemopoietic stem cell transplantation. *Br J Haematol* 105: 361-365.
4. Mielcarek M, Bryant E, Loken M, Zaucha JM, Torok-Storb B, et al. (2006) Long-term engraftment and clonal dominance of donor-derived del(20q) hematopoietic cells after allogeneic stem cell transplantation. *Blood* 107: 1732-1733.
5. Niederwieser DW, Appelbaum FR, Gastl G, Gersdorf E, Meister B, et al. (1990) Inadvertent transmission of a donor's acute myeloid leukemia in bone marrow transplantation for chronic myelocytic leukemia. *N Engl J Med* 322: 1794-1796.
6. Berg KD, Brinster NK, Huhn KM, Goggins MG, Jones RJ, et al. (2001) Transmission of a T-cell lymphoma by allogeneic bone marrow transplantation. *N Engl J Med* 345: 1458-1463.
7. Baron F, Dresse MF, Beguin Y (2003) Transmission of chronic myeloid leukemia through peripheral-blood stem-cell transplantation. *N Engl J Med* 349: 913-914.
8. McCann SR, Lawler M, Humphries P, Bacigalupo A, Podesta M, et al. (1992) Recurrence of Philadelphia chromosome-positive leukemia in donor cells after marrow transplantation for chronic granulocytic leukemia: confirmation by microsatellite studies. *Blood* 79: 2803-2805.
9. Sala-Torra O, Hanna C, Loken MR, Flowers ME, Maris M, et al. (2006) Evidence of donor-derived hematologic malignancies after hematopoietic stem cell transplantation. *Biol Blood Marrow Transplant* 12: 511-517.
10. Naoe T, Kiyoi H, Yamanaka K, Naito K, Yamada K (1989) A case of cALL relapse after allogeneic BMT: recurrence of recipient cell origin, initially determined as being that of donor cell origin by sex chromosome analysis. *Br J Haematol* 73: 420-422.
11. Spinelli O, Giussani U, Borleri G, Lazzari M, Michelato A, et al. (2000) Need for an accurate molecular diagnosis to assess the donor origin of leukemia relapse after allogeneic stem cell transplantation. *Haematologica* 85: 1153-1157.
12. Biernaux C, Loos M, Sels A, Huez G, Stryckmans P (1995) Detection of major bcr-abl gene expression at a very low level in blood cells of some healthy individuals. *Blood* 86: 3118-3122.
13. Bose S, Deininger M, Gora-Tybor J, Goldman JM, Melo JV (1998) The presence of typical and atypical BCR-ABL fusion genes in leukocytes of normal individuals: biologic significance and implications for the assessment of minimal residual disease. *Blood* 92: 3362-3367.
14. Ottmann OG, Pfeifer H (2009) Management of Philadelphia chromosome-positive acute lymphoblastic leukemia (Ph+ ALL). *Hematology Am Soc Hematol Educ Program*.
15. Sala Torra O, Loeb KR (2011) Donor cell-derived leukemia and myelodysplastic neoplasm: unique forms of leukemia. *Am J Clin Pathol* 135: 501-504.
16. Hertenstein B, Hambach L, Bacigalupo A, Schmitz N, McCann S, et al. (2005) Development of leukemia in donor cells after allogeneic stem cell transplantation--a survey of the European Group for Blood and Marrow Transplantation (EBMT). *Haematologica* 90: 969-975.