

Short Communication

Open Access

The Incidence of Neurosensory Disturbance after Sagittal Split Ramus Osteotomy Depending on the Path of the Inferior Alveolar Neurovascular Bundle

Seigo Ohba^{1*}, Hitoshi Yoshimura², Tsugio Inokuchi³, Izumi Asahina¹ and Kazuo Sano²

¹Department of Regenerative Oral Surgery, Nagasaki University Graduate School of Biomedical Sciences, Japan

²Division of Dentistry and Oral Surgery, Department of Sensory and Locomotor Medicine, Faculty of Medical Sciences, University of Fukui, Japan

³Second Department of Oral and Maxillofacial Surgery, Nagasaki University School of Dentistry, Japan

Introduction

Both sagittal split ramus osteotomy (SSRO) and intraoral vertical ramus osteotomy (IVRO) are common surgical treatments for the mandible in patients with jaw deformities. Although SSRO has a wider indication than IVRO, SSRO has several disadvantages, including neurosensory disturbance (NSD) of the inferior alveolar nerve (IAN) [1,2]. While the incidence of NSD of the IAN after IVRO is 0 to 35% [1,3], that after SSRO is 9 to 85% [1,3,4]. In addition, several reports showed that the incidence of NSD of IAN was 99 to 100% immediately after SSRO [3,5,6], and 1 to 66% of the disturbances persisted permanently [5,7]. This permanent NSD not only irritates patients but also decreases patients' quality of life (QOL) [8].

NSD of IAN after surgery can be caused by stretching of or injury to the IAN and by segmental movement after osteotomy [1,9]. Several risk factors, which are associated with damage to the IAN, have been previously reported; these include bleeding [10], lingual working space of the mandibular ramus [10], width of the mandibular ramus [11-13], inappropriate splitting [14], gender [5], age [9,15], running site of the IAN [16,17], osteosynthesis method after split [1,4], and location of the mandibular and mental foramina [10]. However, there are few reports that describe methods that clearly reduce the risk of this complication. Some reports described undefined strategies such as splitting carefully with sufficient pre-surgical assessment [12,18].

In some institutions, a non-sharp-edged cement spatula has been used for osteotomy instead of an osteotome or a chisel to reduce the risk of IAN damage because of its own shape and ability. However, here is no report which described the incidence of NSD of IAN after SSRO using the spatula. The incidence of NSD of IAN was evaluated depending on the IAN pathway after SSRO by using a non-sharp-edged cement spatula in this study.

Materials and Methods

A non-sharp-edged cement spatula (Task Inc., Tokyo, Japan) (Figure 1) was used instead of an osteotome or a chisel during splitting of the mandibular ramus in all cases. The spatula is made of stainless steel, and the tip of the spatula is not sharp, but is flexible and is 4 cm long and 0.3 mm thick. The opposite end is flat and is convenient for malletting.

Patients

Sixty-four patients were diagnosed with jaw deformity and underwent short lingual osteotomy (SLO) [19], which is a modified SSRO, for the mandible with a non-sharp-edged cement spatula at the Department of Oral and Maxillofacial Surgery of University Hospital. Since the combination of SSRO and genioplasty has been reported to increase the incidence of NSD of the IAN [2], the patients who underwent genioplasty simultaneously with SLO were excluded from

this study. Eighteen in 64 patients in whom the mandibular canal wall was in contact with the lateral cortical bone of the ramus at least on one side in axial sections of their preoperative computed tomography (CT) images, were included in this study. The anatomical relationship between the canal wall and the lateral cortical bone was divided into the following 3 groups according to a previous report [13] (Figure 2): a) non-contact group in which a bone marrow space between the canal wall and the lateral cortical bone was observed in the any axial CT images; b) contact group in which the canal wall was in contact with the lateral cortical bone in any axial CT images; and c) fusion group in which the canal wall made a groove in the lateral cortical bone in any axial CT images.



Figure 1: A cement spatula. The tip is thin and flexible and its edge is not sharp. The opposite end of this tool is flat and is convenient for malletting.

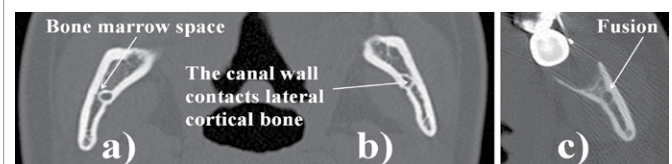


Figure 2: The anatomical relationship between the canal wall and the lateral cortical bone was divided into three groups according to the axial section of the pre-surgical CT images: a) non-contact group in which a bone marrow space between the canal wall and the lateral cortical bone was observed; b) contact group in which the canal wall was in contact with the lateral cortical bone; and c) fusion group in which the canal wall made a groove in the lateral cortical bone.

***Corresponding author:** Seigo Ohba, Department of Regenerative Oral Surgery, Nagasaki University Graduate School of Biomedical Sciences 1-7-1 Sakamoto, Nagasaki 852-8588 Japan, Tel: +81 95 819 7704; Fax: +81 95 819 7705; E-mail: sohba@nagasaki-u.ac.jp, seigoohba@gmail.com

Received December 30, 2014; **Accepted** January 30, 2015; **Published** February 05, 2015

Citation: Ohba S, Yoshimura H, Inokuchi T, Asahina I, Sano K (2015) The Incidence of Neurosensory Disturbance after Sagittal Split Ramus Osteotomy Depending on the Path of the Inferior Alveolar Neurovascular Bundle. *Anat Physiol* 5: 171. doi:10.4172/2161-0940.1000171

Copyright: © 2015 Ohba S, et al. This is an open-access article distributed under the terms of the Creative Commons Attribution License, which permits unrestricted use, distribution, and reproduction in any medium, provided the original author and source are credited.

Surgical procedure

SLO was performed according to a previous report [19] with or without Le Fort I osteotomy. All surgeries were performed by 4 experienced oral and maxillofacial surgeons. When the mandibular ramus was split, the cortical bone of the anterior edge was first grooved by a sagittal saw. Then, a separator increased the space between the segments to determine the IAN. Finally, splitting was completed by separating the lateral cortical bone from the bone marrow using a non-sharp-edged cement spatula (Figures 3 and 4). Because the tip of the spatula is flexible and not sharp, it can be moved posteriorly along the lateral cortical bone of the mandibular ramus. Consequently, this device does not injure the IAN or the cortical bone. This technique enables a secure osteotomy without damaging the IAN. Postoperative management was followed by physiological positioning strategy which was previously reported [20,21].

Evaluation of the NSD

NSD depends on patients' subjective experience. Therefore, NSD was diagnosed in this study if the patients felt any different sensation when their lower lips and mental regions were tested with soft-touch with their eyes closed according to a previous report [22]. The duration of the NSD was recorded.

Results

The mandibular canal wall was in contact with the lateral cortical bone of the ramus at least on one side in axial sections of their preoperative CT images in 18 of 64 patients who were included in this study. Six of 18 patients were male, and the other 12 were female. Their mean age was 20.9 (15 – 34) years old. There was a 0 to 10.5 mm (mean; 6.3 mm) movement of the proximal segment within 5 mm difference between both sides. All surgeries were performed without any remarkable events or unsuccessful osteotomies, and the patients were discharged from the hospital within 16 days after surgery. No severe complications, such as bleeding, were observed during or after surgery.

The anatomical relationship between the canal wall and the lateral cortical bone in the 18 patients (36 ramus sides) was divided into a) non-contact group (9 sides), b) contact group (21 sides) and c) fusion group (6 sides) (Table 1). In the non-contact group, the bone marrow spaces between the canal wall and the lateral cortical bone were 0.50 to 1.37 mm (mean; 0.78 mm).

Table 2 shows the period of NSD in each group. In the entire group, NSD disappeared within 1 week after surgery on 11 sides (30.5%), and NSD disappeared within 1 month after surgery in 28 sides (77.8%). NSD on 8 sides (22.2%) continued more than one month after surgery. In the non-contact group (9 sides), NSD on 7 sides disappeared within 1 week and on 2 sides disappeared within 1 month after surgery. In the contact group (21 sides), NSD on 4 sides disappeared less than 1 week and on 11 sides, disappeared within 1 month. NSD on 3 sides disappeared within 3 months. However, NSD on 3 sides persisted for more than 3 months. The longest persisting NSD in the contact group disappeared 8 months after surgery. In the fusion group, NSD on 4 side disappeared in less than 1 month and NSD on 1 side disappeared within 3 months. On the other hand, NSD on 1 side were protracted. Eventually, all NSD disappeared, although the most protracted case was one in the fusion group that continued for 8 months after surgery.

Discussion

The most important risk factor for NSD of the IAN after SSRO is

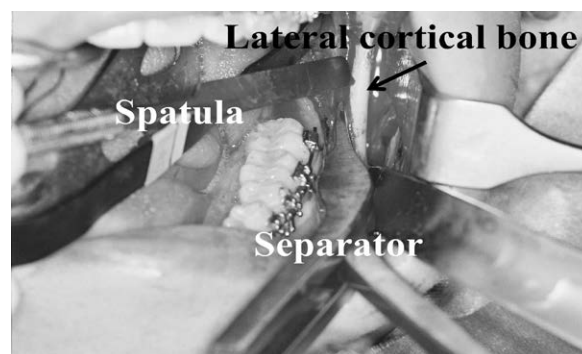


Figure 3: A non-sharp-edged cement spatula was used to separate the lateral cortical bone from bone marrow.

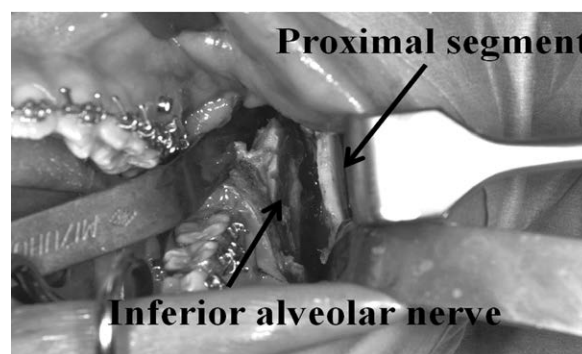


Figure 4: The inferior alveolar nerve was observed between segments.

	Number of patients		Number of ramus
Study group	18	Non-contact	9
		Contact	21
		Fusion	6

Study group: patients who had a canal wall that was in contact with the lateral cortical bone of the ramus at least one side.

Table 1: Number of patients and ramus sides.

The period of NSD	Anatomical relationship between the canal wall and lateral cortical bone (sides)		
	Non-contact (9)	Contact (21)	Fusion (6)
Less than 1 week	7	4	0
Less than 1 month	2	11	4
Less than 3 months	0	3	1
More than 3 months	0	3	1

Table 2: The periods of neurosensory disturbance (NSD) in the lower lip and mental region.

anatomical location of the IAN [16,17,23]. The IAN enters the mandible from the mandibular foramen and usually runs through the bone marrow toward the mental foramen [7]. Most clinicians agreed that the risk of NSD of the IAN was increased when the distance from the canal wall to the outside of the lateral cortical bone of the mandibular ramus was less than 2 mm [13,17,24]. Moreover, when bone marrow space between the canal wall to the inside of the lateral cortical bone of the mandibular ramus was less than 0.8 mm, the incidence of NSD of the IAN was significantly high [17]. On the other hand, the mean bone marrow space between the inside of the lateral cortical bone of the mandibular ramus to the canal wall was 0.78 mm and NSD of the IAN

in all cases disappeared relatively early after osteotomy with a non-sharp-edged cement spatula instead of an osteotome or a chisel with sharp edge in the non-contact group in this study. This suggests that a non-sharp-edged cement spatula is useful for avoiding NSD of the IAN during SSRO even if the IAN run close to the lateral cortical bone.

Yamamoto et al. [16] showed that 25% of the canal (10/30 sides) was in contact with the lateral cortical bone of the mandibular ramus and NSD occurred in all these cases. Tamáz et al. [23] and Tsuji et al. [12] also reported that the canal was in contact with the lateral cortical bone of the mandibular ramus with almost the same frequency. In this study, 21.1% (27/128 sides) of the ramus was shown to be the connection between the canal wall and the lateral cortical bone in 18 of 52 patients. This incidence was almost same as previous reports. NSD of the IAN in 23 of 27 sides disappeared less than 3 months after surgery in the contact and fusion groups. In addition, all NSD completely disappeared eventually although NSD tended to be more protracted in the contact and fusion groups compared with non-contact group. In this technique, the separator was used to gradually increase the space between the segments, and the space was directly observed during osteotomy. Therefore, if the IAN existed on the side of the lateral cortical bone, the spatula could be used to safely separate the IAN from the cortical bone under direct visualization because the tip of the spatula was thin, flexible and not sharp. This suggests the efficacy of a non-sharp-edged cement spatula for SSRO, although the canal wall made a groove in the lateral cortical bone, and the IAN was exposed during osteotomy in several cases (Figure 4).

The incidence of NSD of the IAN was significantly increased when the distance from the IAN to the lateral cortical bone in the second molar region was less than 4.5 mm [11]. Wittwer et al. [18] suggested changing the position of the mesial osteotomy depending on the anatomical location of the IAN in those cases. The direct injury of the IAN during splitting and inappropriate osteotomy was also related to NSD of the IAN [15]. When a thin osteotome/chisel was used or when only a separator was used without an osteotome/chisel during splitting, there was a possibility of injuring the IAN directly [14,24]. Inappropriate osteotomy occurred in 4.5% when only a separator was used for SSRO. Although SLO may decrease the incidence of NSD [25], it is possible that the ramus is split along with the mandibular foramen when the curve around the mandibular foramen is severe. Therefore, splitting with only a separator may induce an inappropriate osteotomy, resulting in an increased incidence of NSD. These findings imply that it is necessary to perform a secure osteotomy by protecting the IAN to avoid NSD. In our technique, splitting was almost completed using a separator and a non-sharp-edged spatula, and the spatula could be used to separate the cortical bone and bone marrow along the lateral cortical bone.

Based on our experience, incidence of NSD of IAN was high after SSRO if the IAN contacts the lateral cortical bone. However, NSD of IAN may be disappeared relatively early although the mandibular canal is close to or contacts with lateral cortical bone using the cement spatula because of its shape and ability to reduce NSD of the IAN during SSRO. This suggested that a non-sharp-edged cement spatula was useful SSRO to avoid the incidence of IAN during SSRO.

References

1. Westermarck A, Bystedt H, von Konow L (1998) Inferior alveolar nerve function after mandibular osteotomies. *Br J Oral Maxillofac Surg* 36: 425-428.
2. Acebal-Bianco F, Vuylsteke PL, Mommaerts MY, De Clercq CA (2000) Perioperative complications in corrective facial orthopedic surgery: a 5-year retrospective study. *J Oral Maxillofac Surg* 58: 754-760.
3. Walter JM Jr, Gregg JM (1979) Analysis of postsurgical neurologic alteration in the trigeminal nerve. *J Oral Surg* 37: 410-414.
4. Raveh J, Vuillemin T, Ladrach K, Sutter F (1988) New techniques for reproduction of the condyle relation and reduction of complications after sagittal ramus split osteotomy of the mandible. *J Oral Maxillofac Surg* 46: 751-757.
5. Jokić D, Jokić D, Uglešić V, Knežević P, Macan D (2012) Altered light-touch sensation after bilateral sagittal-split osteotomy: a prospective study of 50 patients. *Angle Orthod* 82: 1029-1032.
6. Phillips C, Kim SH, Essick G, Tucker M, Turvey TA (2009) Sensory retraining after orthognathic surgery: effect on patient report of altered sensations. *Am J Orthod Dentofacial Orthop* 136: 788-794.
7. Yoshida T, Nagamine T, Kobayashi T, Michimi N, Nakajima T, et al. (1989) Impairment of the inferior alveolar nerve after sagittal split osteotomy. *J Craniomaxillofac Surg* 17: 271-277.
8. Phillips C, Essick G, Blakey 3rd G, Tucker M (2007) Relationship between patients' perceptions of postsurgical sequelae and altered sensations after bilateral sagittal split osteotomy. *J Oral Maxillofac Surg* 65: 597-607.
9. Ylikontiola L, Kinnunen J, Oikarinen K (2000) Factors affecting neurosensory disturbance after mandibular bilateral sagittal split osteotomy. *J Oral Maxillofac Surg* 58: 1234-1239.
10. Kuroyanagi N, Miyachi H, Ochiai S, Kamiya N, Kanazawa T, et al. (2013) Prediction of neurosensory alterations after sagittal split ramus osteotomy. *Int J Oral Maxillofac Surg* 42: 814-822.
11. Yoshioka I, Tanaka T, Khanal A, Habu M, Kito S, et al. (2010) Relationship between inferior alveolar nerve canal position at mandibular second molar in patients with prognathism and possible occurrence of neurosensory disturbance after sagittal split ramus osteotomy. *J Oral Maxillofac Surg* 68: 3022-3027.
12. Tsuji Y, Muto T, Kawakami J, Takeda S (2005) Computed tomographic analysis of the position and course of the mandibular canal: relevance to the sagittal split ramus osteotomy. *Int J Oral Maxillofac Surg* 34: 243-246.
13. Yamauchi K, Takahashi T, Kaneuji T, Nogami S, Yamamoto N, et al. (2012) Risk factors for neurosensory disturbance after bilateral sagittal split osteotomy based on position of mandibular canal and morphology of mandibular angle. *J Oral Maxillofac Surg* 70: 401-406.
14. Brusati R, Fiamminghi L, Sesenna E, Gazzotti A (1981) Functional disturbances of the inferior alveolar nerve after sagittal osteotomy of the mandibular ramus: operating technique for prevention. *J Maxillofac Surg* 9: 123-125.
15. August M, Marchena J, Donady J, Kaban L (1998) Neurosensory deficit and functional impairment after sagittal ramus osteotomy: a long-term follow-up study. *J Oral Maxillofac Surg* 56: 1231-1235.
16. Yamamoto R, Nakamura A, Ohno K, Michi KI (2002) Relationship of the mandibular canal to the lateral cortex of the mandibular ramus as a factor in the development of neurosensory disturbance after bilateral sagittal split osteotomy. *J Oral Maxillofac Surg* 60: 490-495.
17. Ylikontiola L, Moberg K, Huuonen S, Soikkonen K, Oikarinen K (2002) Comparison of three radiographic methods used to locate the mandibular canal in the buccolingual direction before bilateral sagittal split osteotomy. *Oral Surg Oral Med Oral Pathol Oral Radiol Endod* 93: 736-742.
18. Wittwer G, Adeyemo WL, Beinemann J, Juergens P (2012) Evaluation of risk of injury to the inferior alveolar nerve with classical sagittal split osteotomy technique and proposed alternative surgical techniques using computer-assisted surgery. *Int J Oral Maxillofac Surg* 41: 79-86.
19. Yang HJ, Lee WJ, Yi WJ, Hwang SJ (2010) Interferences between mandibular proximal and distal segments in orthognathic surgery for patients with asymmetric mandibular prognathism depending on different osteotomy techniques. *Oral Surg Oral Med Oral Pathol Oral Radiol Endod* 110: 18-24.
20. Ohba S, Yoshida M, Kohara H, Kawasaki T, Minamizato T, et al. (2014) Short lingual osteotomy without fixation: a new strategy for mandibular osteotomy known as "physiological positioning". *Br J Oral Maxillofac Surg* 52: e9-9e13.
21. Ohba S, Nakao N, Nakatani Y, Kawasaki T, Minamizato T, et al. (2014) The skeletal stability after maxillo-mandibular osteotomy with a "physiological positioning strategy". *Br J Oral Maxillofac Surg* 52: 965-969.
22. D'Agostino A, Trevisiol L, Gugole F, Bondi V, Nocini PF (2010) Complications of orthognathic surgery: the inferior alveolar nerve. *J Craniofac Surg* 21: 1189-1195.

23. Tamás F (1987) Position of the mandibular canal. *Int J Oral Maxillofac Surg* 16: 65-69.
24. Dal Pont G (1961) Retromolar osteotomy for the correction of prognathism. *J Oral Surg Anesth Hosp Dent Serv* 19: 42-47.
25. Epker BN (1977) Modifications in the sagittal osteotomy of the mandible. *J Oral Surg* 35: 157-159.