

# Testicular Microlithiasis and Testicular Germ Cell Tumors: A Seven Year Retrospective Study

Gian Carlo Parenti<sup>1</sup>, Ugo De Giorgi<sup>2</sup>, Elisa Gaddoni<sup>3</sup>, Vincenza Conteduca<sup>1</sup>, Silvia Zago<sup>1</sup>, Paolo Campioni<sup>3</sup>, Melchiorre Giganti<sup>3</sup> and Fabrizio Albarello<sup>3\*</sup>

<sup>1</sup>Department of radiology, S Maria delle Croci Hospital, Ravenna, Italy

<sup>2</sup>Department of oncology, IRCCS Romagna Scientific Institute for the Study and Treatment of Cancer (I.R.S.T.), Meldola, Italy

<sup>3</sup>Department of radiology, Ferrara University Hospital, Arcispedale Sant Anna, Cona, Italy

## Abstract

**Purpose:** To evaluate the association between grade II and III testicular Microlithiasis (TM) and Testicular Germ Cell Tumor (TGCT), reporting disease-free survival over 7 years.

**Materials and Methods:** The association between TM and TGCT was studied in 7,320 male patients referred to the radiology department of an Italian hospital for several scrotal disease. TM associated with TGCT was diagnosed in all men by ultrasound (US) and by testicular histology specimens. All patients with TM were followed-up annually with US. Chi-square, Kaplan-Meier and Fisher's exact test were used for statistical analysis.

**Results:** The incidence of TM was 1.4% (98 of 7320). Twenty eight patients with TGCT (28 of 58, 48.2%) had associated TM. During the follow-up, testicular cancer was detected in six patients (incidence 6.12%, 95% confidence interval from 2.8 to 12.7); four of these were recurrences of TGCT, while the other two patients were ex novo TGCT. There was a significant difference ( $p < 0.001$ ) between the rate of TGCT in men with TM (28 of 98, 28.5%) and that in men without TM (30 of 7222, 0.4%) with an odds ratio of 95.89 [95% CI 42.7 - 110.5].

**Conclusion:** The association found between TGCT and TM addresses microlithiasis as a prospective marker for testicular tumor. Yearly follow-up with US should be taken into consideration, encouraging self-examination in the meantime.

**Keywords:** Testicular microlithiasis; Germ cell tumor; Doppler ultrasonography; Follow-up

**Abbreviations:** US: Color Doppler Ultrasonography; CIS: Carcinoma In Situ TM: Testicular Microlithiasis; CTM: Classic Microlithiasis; LTM: Limited Microlithiasis; TGCT: Testicular Germ Cell Tumor; TIN: Testicular Intraepithelial Neoplasia.

## Introduction

Testicular Microlithiasis (TM) is an infrequent condition recognized by a sonographic pattern of multiple small foci of increased echogenicity measuring 1-3 mm in diameter. These are randomly distributed throughout the testicular parenchyma, in which calcium deposits have been formed into the lumen of seminiferous tubules or have arisen from the tubular basement membrane components [1-6]. Classic Microlithiasis (CTM) was defined as five or more echogenic foci in either or both testicles and Limited Microlithiasis (LTM) as fewer than five foci [7]. CTM is sub-categorized in grade I (5-10 microliths/image), grade II (10-20 microliths/image), and grade III (> 20 microliths/image) [8]. The incidence of TM on color Doppler ultrasound (US) reported in the literature among symptomatic and asymptomatic patients ranges between 0.6% and 20% [9-17]. TM has been described in association with many benign conditions of the testis, such as testicular torsion, varicocele, epididymitis, and cryptorchidism [10-12,18]. Testicular Germ Cell Tumors (TGCT) is the most frequent malignancies found in Caucasian men between 20 and 40 years old [19]. TGCT represent about 95% of all testicular neoplasias and the worldwide incidence of these tumors has more than doubled over the past 40 years [20,21]. Though most of these tumors are curable, with a current survival index higher than 90%, their occurrence rate is still growing [22,23].

Several risk factors for TGCT have been identified, including prior

history of TGCT, positive family history, cryptorchidism, testicular dysgenesis, and Klinefelter's syndrome [24]. There are conflicting data on the association between microlithiasis and TGCT; some authors have reported TM to be a risk factor for concurrent testicular tumor, with an incidence ranged between 8% and 46%, whereas other authors do not mention TM as a risk factor for TGCT [1,9-16,25-29]. However, no data are available on the potential cause-effect connection between the subgroup of grade II and III TM and TGCT development.

The primary purpose of this retrospective study was to evaluate the association between grade II and III TM and TGCT on a large cohort of patients who have undergone scrotal US as routine examination for diagnosis and follow-up of several testicular events. The study examined seven years of data and observations. A secondary aim was to study the disease free survival of the group with TGCT and grade II and III TM versus the group of patients with TGCT but without grade II and III TM, during the follow-up with scrotal US.

## Materials and Methods

From January 2004 to January 2011, 7320 male patients were

\*Corresponding author: Fabrizio Albarello, Via Fossignano 1/b Aprilia (LT) 04011, Italy, Tel: +39 3928529110; E-mail: [fabrizioalbarello@yahoo.it](mailto:fabrizioalbarello@yahoo.it)

Received January 10, 2014; Accepted March 20, 2014; Published March 31, 2014

Citation: Parenti GC, De Giorgi U, Gaddoni E, Conteduca V, Zago S, et al. (2014) Testicular Microlithiasis and Testicular Germ Cell Tumors: A Seven Year Retrospective Study. *Andrology* 3: 115. doi: [10.4172/2167-0250.1000115](https://doi.org/10.4172/2167-0250.1000115)

Copyright: © 2014 Parenti GC, et al. This is an open-access article distributed under the terms of the Creative Commons Attribution License, which permits unrestricted use, distribution, and reproduction in any medium, provided the original author and source are credited.

referred to the radiology department for scrotal US. The reasons for these referrals included testicular torsion, traumatic event or other urgent reasons from the emergency unit or outpatients, referred by urologists to assess acute and sub-acute scrotal disease or to follow-up patients previously treated for cryptorchidism or TGCT. Findings at US and patients charts were reviewed retrospectively to establish the presence of grade II and III TM and to note relevant clinical information of the patients such as cryptorchidism, infertility, traumatic event and pathologic reports of testicular tumor.

Approval to report this retrospective study was sought from the Hospital Ethics Board, which waived the need for formal review and approval. All patients had an ultrasound examination performed for clinical reasons, with parental consent when needed.

All of the examinations were performed by radiologists with at least 10 years experience with scrotal US and carried out with a high resolution Logiq 7 (GE Healthcare, UK) or H21 (Hitachi, Kashiwa, Japan) or iU22 (Philips, Bothell, WA) scanner, equipped with linear-array probe (settable frequency from 7 up to 17 MHz) and color power Doppler imaging.

Fleiss's  $\kappa$  was used for assessing the inter-observers agreement between the raters.

Panoramic gray-scale scans were obtained in both longitudinal and transverse planes comparing size and echogenicity of the two sides. Any difference in echogenicity in any part of the testis, including heterogeneity of the echo pattern, focal nodules, and echogenic dots, was documented. For each testis, the representative US imaging was performed, setting the appropriate pulse repetition frequency, wall filter and color gain to obtain the optimal color flow signal. Additional techniques, such as Valsalva maneuver or upright position, were used for evaluation of the venous plexus, as needed.

The grading system was based on the number of microliths per testis at US: grade I = 5-10 microliths, grade II = 10-20, grade III >20 [8].

1) Patients with grade II and III TM were included in a single group of study.

2) Patients with grade I TM were assimilated in the group of men without TM considering the risk related to TGCT comparable to the general population risk [30]. Suspected testicular masses were identified reporting their number, echo-structure, vascularity and the presence of microlithiasis within the neoplasm or in the adjacent parenchyma.

3) Patients with grade II and III TM and no signs of malignancy at the first examination were followed-up annually, whereas patients with grade I TM were advised for self-examination, as per our Institution guidelines and the literature reviews [30,31].

In patients with a past history of testicular cancer, follow-up ultrasound was performed every six months with an annual urology outpatient review. Patients with US suggestive for neoplastic lesion underwent orchiectomy or nodulectomy.

In addition to assessing a definitive diagnosis of TGCT the histological examination was performed, which also detected the presence of microlithiasis within the neoplasm as well as in the parenchyma surrounding the mass. This also defined the histological type, the vascularization and whether sclerohyalinosis was associated, leading to the hypothesis that these changes may be detected

histologically in the parenchyma adjacent to the neoplastic lesion, making a predisposing environment for the rise of testicular cancers [32].

Chi-square, mid-p and Fisher's exact test were used for statistical analysis. A p value of < 0.05 was considered statistically significant to determinate the correlation between grade II and III TM with TGCT. The Kaplan-Meier with log-rank (Mantel-Cox) test was used for the disease free survival analysis (IBM Corp. Released 2011. IBM SPSS Statistics for Windows, Version 20.0 Armonk, NY: IBM Corp.).

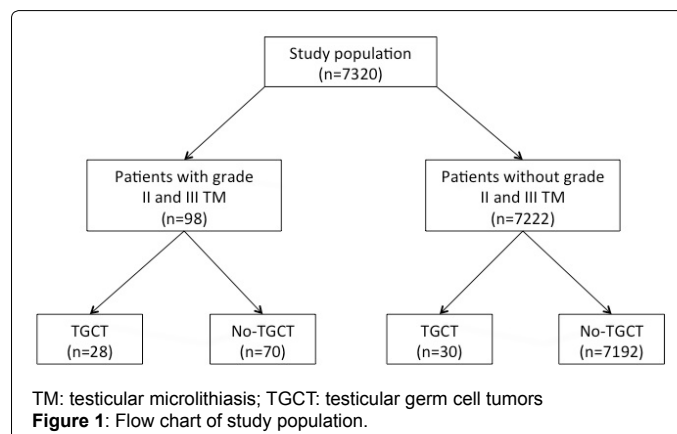
## Results

This retrospective study included 7320 male patients aged from 7 to 82 years (mean  $\pm$  SD: 29.6  $\pm$  7.4 years), whose 5122 patients (70 %) had < 40 years. The number of follow-up ultrasounds performed on each patient ranged from 1 to 9 (median 4). Patients were followed-up from 20 to 84 months.

The clinical indications for US examination included one or more of the following: history of testicular cancer (1%), history of treated cryptorchidism (6%), history of testicular trauma (5%), infertility (30%), suspected infection (30%), scrotal pain (20%), history of orchitis (3%), scrotal enlargement (2%), testicular palpable mass (2%), family history of testicular tumor (1%). The total number of documented testicular tumors is 66, which included: 58 TGCT (35 seminoma, 21 non-seminoma, 2 burned-out tumors found as a mass in the testis); 2 Leydig cell tumors, 1 B-cell lymphoma, 1 lymphoblastic lymphoma, 2 Sertoli cell tumors, 1 epidermoid tumor, 1 adenomatoid tumor.

The incidence of grade II and III TM was diagnosed in 98 of 7320 patients (1.4%), whose 28 patients with diagnosis of TGCT (20 seminoma and 8 non-seminoma; 48.2%) had grade II and III TM, whereas only 30 patients of 7222 without grade II and III TM had diagnosis of TGCT (17 seminoma and 13 non-seminoma; 0.4%) (Figure 1). There was a significant difference ( $p < 0.001$ ) between the rate of TGCT in men with grade II and III TM and that in men without grade II and III TM with an odds ratio of 95.89 [95% CI 42.7 - 110.5]; risk ratio of 68.78 [95% CI 42.8-110.6].

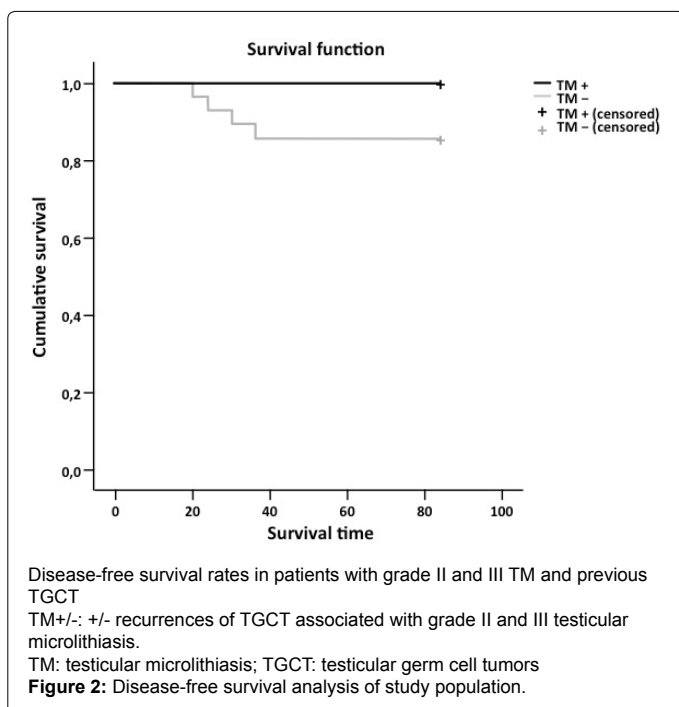
During the study period, 6 testicular cancers were detected in patients with TM of grade II and III (incidence 6.12 %, 95% confidence interval from 2.8 to 12.7); 4 of them were recurrences of TGCT in patients who had previously undergone an orchiectomy [incidence 14.28% (4 of 28); confidence interval from 5.7 to 31], while 2 were ex novo TGCT, one of whom had a previous history of treated maldescent



testis [incidence 2.85% (2 of 70); confidence interval from 0.79 to 9.8] (Figure 2).

In the 30 patients without grade II and III TM in the controlateral testis but with unilateral TGCT (17 seminoma and 13 non-seminoma) no interval tumor development was noted during the follow-up with US. The incidence of recurrence TGCT in the controlateral testis was greater in the patients with grade II and III TM (4 of 28 patients), than in those without (0 of 30) ( $p = 0.033$ ).

Comparing the testicular tumors associated with grade II and III TM (28 of 98, 28.5%) with those not associated (30 of 7222, 0.4%) there was a significant difference in the rate of coexisting tumor ( $p < 0.001$ ; odds ratio of 101.9 [95% confidence interval (CI) 59.2 - 175.7]; risk ratio of 69.35 [95% CI 44.6 - 107.6]). Fleiss's  $\kappa$  was  $> 0.8$ .



The main characteristics of 58 men with tumor resected or not to grade II and III TM are summarized in Table 1. The main features of 98 patients with grade II and III TM are listed in Table 2.

## Discussion

The incidence of TM in healthy population based on US is between 0.6% and 5.6% [33]. Several risk factors for TGCT development have been identified, including previous history of TGCT, positive family history, cryptorchidism, testicular dysgenesis, and Klinefelter's syndrome [24,26]. Hypotheses concerning the association between microlithiasis and TGCT are conflicting. About 14-16.9% of patients with a primary testicular tumor are found to have TM of the contralateral testis, which has also been shown to give an increased risk of carcinoma in situ (CIS) [15,18,34,35]. TGCT develop through a precursor stage, called testicular intraepithelial neoplasia (TIN; also called intratubular germ cell neoplasia or CIS), which is present many years before invasive malignancy occurs. Some physicians recommend a contralateral biopsy, at least for high-risk patients, defined as patients with unilateral TGCT who face a 5-6% risk of a second testis cancer, or those with retroperitoneal TGCT, who have more than 10% risk of a testicular cancer. A third group of patients might also be considered for biopsy: patients with testicular microlithiasis upon scrotal sonography [36]. Yet, as the majority of patients with untreated CIS/TIN in the contralateral testis will eventually develop overt TGCT within the next 10 years, surveillance programs, e.g. by regular clinical examination and testicular ultrasound, are mandatory [37]. During the last decade, several authors documented the increased incidence of TM in patients with testicular tumors: TM was reported in 23-73% of patients with testicular tumors versus 2.1-6% in those without TM [12,14,25,38]. This finding led to follow-ups with men with TM over varying time periods, but no author has documented the development of a tumor [13,19]. However, some case reports documented the development of tumors in patients with known TM [40,41]. Richenberg et al. suggested that ultrasound surveillance is unlikely to benefit patients with TM in the absence of other risk factors, while Mullooly et al confirmed the importance of TM in the development of TGCT [42]. Even though they did not suggest regular surveillance, they did recommended referral to a urological unit for all men diagnosed with TM on scrotal ultrasonography [43].

Features	Cancer development (28 pts)	No cancer development (70 pts)
Mean age at time of TM diagnosis (years, range)	32 (27-37)	40 (7-84)
Bilateral TM (%)	71	35.7
History of prior orchidectomy for unilateral tumor (%)	14	2
Familial history for testicular cancer (%)	3.5	0
Infertility (%)	3.5	7
Testicular dysgenesis (%)	7	3.5
History of traumatic event (%)	3.5	3.5
History of orchitis (%)	0	0

**Table 1:** Summary of 98 patients features with grade II and III Testicular Microlithiasis (TM) subdivided into two groups: (1) with and (2) without cancer development.

Characteristics	Testicular tumor with grade II and III TM (28 patients)	Testicular tumor without TM (30 patients)	p
Mean age at diagnosis of tumor testicular (years, range)	30 (27-40)	40 (7-84)	< 0.05
Disease free-survival (months)	38	50	< 0.04
Overall free-survival (months)	20	60	< 0.05
Prevalence of recurrence tumor in the controlateral testis (%)	14.2	0	0.033
Rate of coexisting tumor (%)	0	0	< 0.05

**Table 2:** Characteristics of testicular tumor in men with and without grade II and III Testicular Microlithiasis (TM).

In the meta-analysis of Tan et al. TM was associated with a substantially elevated risk of a concurrent diagnosis of TGCT if other risk factors were present [27]. Actually, many reviews report TM as a risk factor for development of TGCT but no specific evidence has been described in the literature about the association between grade II and III TM with TGCT [12,14,18,44].

In this retrospective study, we have shown the association between grade II and III TM and TGCT on a cohort of 7320 patients who underwent a routine US examination in the radiology unit. The incidence of TM of grade II and III was 1.4% (98 of 7320). TGCT was diagnosed in 58 patients, 28 of whom (48.2%) had associated TM of grade II and III; 30 patients had not. We found a significant difference between the rate of TGCT in men with TM of grade II and III (28 of 98: 28.5%) and that in men without TM (30 of 7,222: 0.4%) with an odds ratio of 95.89 (95% confidence interval from 42.7 to 110.5) and a risk ratio of 68.78 (95% confidence interval from 42.78 to 110.6). Moreover, considering the disease-free survival of the two groups of men followed-up, the recurrence of TGCT in the contralateral testis was greater in the patients with grade II and III TM (4 of 28 patients) than in those without (0 of 30,  $P = 0.048$ ).

The present study has several limitations. Firstly, it was performed retrospectively with the inherent shortcomings of this kind of review. Furthermore, another limitation of our study is the analysis of the association of all the risk factors for developing TGCT not only of TM. However, we found that 22.4% (13 of 58) of overall TGCT cases were associated with tubular hyalinization, 12% of those (7 of 58) had grade II and III TM and 2 of 7 (28.5%) were in sub-fertile patients. These outcomes lead to the hypothesis that testicular cancers arise in a predisposing environment, and that TM could also be considered a premalignant condition [4,5]. Another pitfall has to be considered: some patients had undergone therapy during the follow-up; this would more likely lead to an underestimation of the incidence of the findings.

The lack of current proven follow-up strategies for patients with TM basically stems from ignorance of the exact incidence of symptomatic and asymptomatic populations and ambiguity in the cause-effect relationship of TM with other potentially associated conditions.

## Conclusion

The association between TGCT and grade II and III TM and the incidence of recurrent TGCT related to this condition found in this study suggests that this sonographic feature is a prospective marker for testicular tumor.

Yearly follow-up with US should be considered, encouraging self-examination in the meantime. Nevertheless long-term prospective studies are needed to better define the role of grade II and III TM in the pathogenesis of TGCT and also to find a consensus on the follow-up of patients with TM.

## References

1. Backus ML, Mack LA, Middleton WD, King BF, Winter TC, et al. (1994) Testicular microlithiasis: imaging appearances and pathologic correlation. *Radiology* 192: 781-785.
2. De Jong BW, De Gouveia Brazao CA, Stoop H, Wolfenbuttel KP, Oosterhuis JW, et al. (2004) Raman spectroscopic analysis identifies testicular microlithiasis as intratubular hydroxyapatite. *J Urol* 171: 92-96.
3. Drut R, Drut RM (2002) Testicular microlithiasis: histologic and immunohistochemical findings in 11 pediatric cases. *Pediatric and developmental pathology* 5: 544-550.
4. Kim B, Winter TC, Ryu JA (2003) Testicular microlithiasis: clinical significance and review of the literature. *Eur Radiol* 13: 2567-2576.
5. Nistal M, Martinez-Garcia C, Paniagua R (1995) The origin of testicular microliths. *Int J Androl* 18: 221-229.
6. Renshaw AA (1998) Testicular calcifications: incidence, histology and proposed pathological criteria for testicular microlithiasis. *J Urol* 160: 1625-1628.
7. Goede J, Hack WW, van der Voort-Doedens LM, Pierik FH, Looijenga LH, et al. (2010) Testicular microlithiasis in boys and young men with congenital or acquired undescended (ascending) testis. *J Urol* 183: 1539-1543.
8. Sanli O, Kadioglu A, Atar M, Acar O, Nane I, et al. (2008) Grading of classical testicular microlithiasis has no effect on the prevalence of associated testicular tumors. *Urol Int* 80: 310-316.
9. Cast JE, Nelson WM, Early AS, Biyani S, Cooksey G, et al. (2000) Testicular microlithiasis: prevalence and tumor risk in a population referred for scrotal sonography. *AJR Am J Roentgenol* 175: 1703-1706.
10. Ganem JP, Workman KR, Shaban SF (1999) Testicular microlithiasis is associated with testicular pathology. *Urology* 53: 209-213.
11. Höbarth K, Susani M, Szabo N, Kratzik C (1992) Incidence of testicular microlithiasis. *Urology* 40: 464-467.
12. Otite U, Webb JA, Oliver RT, Badenoch DF, Nargund VH (2001) Testicular microlithiasis: is it a benign condition with malignant potential? *Eur Urol* 40: 538-542.
13. Skyrme RJ, Fenn NJ, Jones AR, Bowsher WG (2000) Testicular microlithiasis in a UK population: its incidence, associations and follow-up. *BJU Int* 86: 482-485.
14. Derogee M, Bevers RF, Prins HJ, Jonges TG, Elbers FH et al. (2001) Testicular microlithiasis, a premalignant condition: prevalence, histopathologic findings, and relation to testicular tumor. *Urology* 57: 1133-1137.
15. Bach AM, Hann LE, Shi W, Giess CS, Yoo HH, et al. (2003) Is there an increased incidence of contralateral testicular cancer in patients with intratesticular microlithiasis? *AJR Am J Roentgenol* 180: 497-500.
16. Middleton WD, Teefey SA, Santillan CS (2002) Testicular microlithiasis: prospective analysis of prevalence and associated tumor. *Radiology* 224: 425-428.
17. Peterson AC, Bauman JM, Light DE, McMann LP, Costabile RA (2001) The prevalence of testicular microlithiasis in an asymptomatic population of men 18 to 35 years old. *J Urol* 166: 2061-2064.
18. von Eckardstein S, Tsakmakidis G, Kamischke A, Rolf C, Nieschlag E (2001) Sonographic testicular microlithiasis as an indicator of premalignant conditions in normal and infertile men. *J Androl* 22: 818-824.
19. Wu X, Groves FD, McLaughlin CC, Jemal A, Martin J, et al. (2005) Cancer incidence patterns among adolescents and young adults in the United States. *Cancer Causes Control* 16: 309-320.
20. Chia VM, Quraishi SM, Devesa SS, Purdue MP, Cook MB et al. (2010) International trends in the incidence of testicular cancer, 1973-2002. *Cancer epidemiology, biomarkers & prev* 19: 1151-1159.
21. Jemal A, Bray F, Center MM, Ferlay J, Ward E, et al. (2011) Global cancer statistics. *CA Cancer J Clin* 61: 69-90.
22. Townsend JS, Richardson LC, German RR (2010) Incidence of testicular cancer in the United States, 1999-2004. *Am J Mens Health* 4: 353-360.
23. Walschaerts M, Huyghe E, Muller A, Bachaud JM, Bujan L, et al. (2008) Doubling of testicular cancer incidence rate over the last 20 years in southern France. *Cancer Causes Control* 19: 155-161.
24. <http://www.nccn.org/index.asp>
25. Höbarth K, Szabo N, Klingler HC, Kratzik C (1993) Sonographic appearance of testicular microlithiasis. *Eur Urol* 24: 251-255.
26. Parenti GC, Zago S, Lusa M, Campioni P, Mannella P (2007) Association between testicular microlithiasis and primary malignancy of the testis: our experience and review of the literature. *Radiol Med* 112: 588-596.
27. Tan IB, Ang KK, Ching BC, Mohan C, Toh CK, et al. (2010) Testicular microlithiasis predicts concurrent testicular germ cell tumors and intratubular germ cell neoplasia of unclassified type in adults: a meta-analysis and systematic review. *Cancer* 116: 4520-4532.

28. Chen JL, Chou YH, Tiu CM, Chiou HJ, Wang HK, et al. (2010) Testicular microlithiasis: analysis of prevalence and associated testicular cancer in Taiwanese men. *J Clin Ultrasound* 38: 309-313.
29. La Vignera S, Condorelli R, Vicari E, D'Agata R, Calogero AE (2012) Testicular microlithiasis: analysis of prevalence and associated testicular cancer in central-eastern Sicilian andrological patients. *Andrologia* 44 Suppl 1: 295-299.
30. Puttemans T (1999) Atlas échographique, Doppler couleur du scrotum. Sauramps Médical France.
31. Pourbagher MA, Kilinc F, Guvel S, Pourbagher A, Egilmez T, et al. (2005) Follow-up of testicular microlithiasis for subsequent testicular cancer development. *Urol Int* 74: 108-112.
32. Nistal M PR (1997) Non neoplastic diseases of the testis. In: Bostwick DG, Eble JN *Urologic surgical pathology* St Louis: Mosby, 457-565.
33. Yee WS, Kim YS, Kim SJ, Choi JB, Kim SI, et al. (2011) Testicular microlithiasis: prevalence and clinical significance in a population referred for scrotal ultrasonography. *Korean J Urol* 52: 172-177.
34. Holm M, Rajpert-De Meyts E, Daugaard G, Skakkebaek NE (2002) Re: the prevalence of testicular microlithiasis in an asymptomatic population of men 18 to 35 years old. *J Urol* 168: 1108.
35. Skakkebaek NE (1972) Possible carcinoma-in-situ of the testis. *Lancet* 2: 516-517.
36. Dieckmann KP, Kulejewski M, Heinemann V, Loy V (2011) Testicular biopsy for early cancer detection--objectives, technique and controversies. *Int J Androl* 34: e7-13.
37. Beyer J, Albers P, Altena R, Aparicio J, Bokemeyer C, et al. (2013) Maintaining success, reducing treatment burden, focusing on survivorship: highlights from the third European consensus conference on diagnosis and treatment of germ-cell cancer. *Ann oncol* 24: 878-888.
38. Winter TC, Zunkel DE, Mack LA (1996) Testicular carcinoma in a patient with previously demonstrated testicular microlithiasis. *J Urol* 155: 648.
39. Bennett HF, Middleton WD, Bullock AD, Teefey SA (2001) Testicular microlithiasis: US follow-up. *Radiology* 218: 359-363.
40. Poulsen JSP, Holm M (2005) Testicular microlithiasis - a sinister condition?. In: Dawson C, Muir GH *The Evidence for Urology* (1st edn.) Shrewsbury, Tfm Publishing Ltd 31-38.
41. Gilbert S, Nuttall MC, Sidhu PS, Ravi R (2007) Metachronous testicular tumors developing 5 and 9 years after the diagnosis of testicular microlithiasis. *J Ultrasound Med* 26: 981-984.
42. Richenberg J, Brejt N (2012) Testicular microlithiasis: is there a need for surveillance in the absence of other risk factors? *Eur Radiol* 22: 2540-2546.
43. Mullooly C, Hickerton B, Weston R, Woolley PD (2012) Testicular microlithiasis: is it significant? *Int J STD AIDS* 23: 620-622.
44. Cornford PA, Baird AD, Woolfenden KA (2001) Testicular microlithiasis needs long-term surveillance. *Scand J Urol Nephrol* 35: 243-244.