

# Survival Undergoing Rescue Percutaneous Coronary Intervention under the Support of Intra-aortic Balloon Counter-Pulsation in Acute Myocardial Infarction Complicated by Cardiogenic Shock

Zhao-Feng Li<sup>1\*</sup>, Shu-Guang Yang<sup>1</sup>, Xue-Jia Su<sup>2</sup>, and Yu-Fei Zhang<sup>3\*\*</sup>

<sup>1</sup>Department of Cardiology, No. 88 Hospital of PLA, Tai'an City, Shandong Province, China

<sup>2</sup>Department of Thoracic Surgery, No. 88 Hospital of PLA, Tai'an City, Shandong Province, China

<sup>3</sup>Department of Intensive Care Unit, No. 88 Hospital of PLA, Tai'an City, Shandong Province, China

**Corresponding authors:** Zhao-Feng Li, Department of Cardiology, No. 88 Hospital of PLA, Tai'an City, Shandong Province, 271000, China, Tel: +86-538-8839826; Fax: +86-538-8839826; E-mail: lizhaofeng\_2013@yahoo.com

\*\*Yu-Fei Zhang, Department of Intensive Care Unit, No. 88 Hospital of PLA, Tai'an City, Shandong Province, China, Tel: +86-538-8839826; Fax: +86-538-8839826; E-mail: feiyufang@163.com

**Rec date:** May 15, 2014, **Acc date:** Jun 24, 2014, **Pub date:** Jun 30, 2014

**Copyright:** © 2014 Li ZF, et al. This is an open-access article distributed under the terms of the Creative Commons Attribution License, which permits unrestricted use, distribution, and reproduction in any medium, provided the original author and source are credited.

## Abstract

Fibrinolytic therapy remains the most common initial therapy for ST-segment elevation myocardial infarction (STEMI) in the U.S. and worldwide. However, an initial fibrinolytic therapy restores normal flow in only about 50% to 60% of STEMI patients in 90 minutes, with even lower success rates in elderly patients or those with cardiogenic shock. Based on the limited data, rescue percutaneous coronary intervention (PCI) appears to reduce the risks of recurrent myocardial infarction and possibly death compared to conservative therapy for the patients following unsuccessful fibrinolytic therapy. Here, we present a case with STEMI complicated by cardiogenic shock undergoing rescue PCI under the support of intra-aortic balloon counterpulsation (IABP).

**Keywords:** Intraaortic balloon counterpulsation; Acute myocardial infarction; Cardiogenic shock

## Introduction

According to the guideline for the management of ST-elevation myocardial infarction (STEMI) of ACCF/AHA, primary percutaneous coronary intervention (PCI) was the first choice for the patients with STEMI within the twelve hours from the symptom onset [1]. Fibrinolytic therapy remains the most common reperfusion treatment all over the world [2]. However, fibrinolytic therapy was not sure to acquire a total reperfusion and about 30% to 50% of patients with STEMI failed to achieve patency of the infarct related artery (IRA) at 90 min after thrombolytic therapy [3]. Rescue PCI early after failed thrombolysis seems to be as effective and safe as primary PCI by some recent trials [4]. Here, we report a case of STEMI for fibrinolytic therapy and rescue PCI.

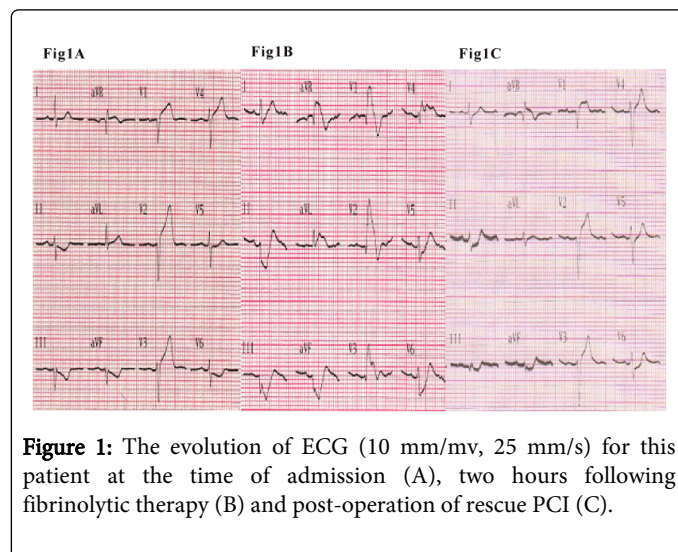
## Case Report

A 73-year-old man with no history of chest pain was admitted to our emergency department, complaining of aggressive left-sided chest pain, dyspnoea, profuse sweating, and weakness for about an hour. Blood pressure values were 80/55 mmHg, the heart rate was 53 beats/min accompanied with occasional ventricular premature beat. The initial electrocardiogram (ECG) was performed (Figure 1A). This ECG showed that ST segment was elevated between 2 mm and 3 mm in precordial leads V2-V4 and was depressed between 0.05 mm and 1.5 mm in limb leads II, III, and aVF. Tall T wave was also seen in leads V2-V4. This ECG also showed QS in leads V1-V2 and poor R wave progression in precordial leads V1-V6. According to the

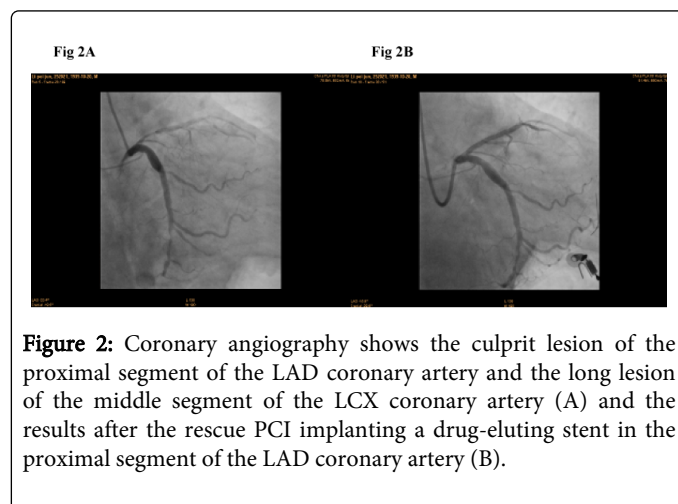
guideline for the management of ST-elevation myocardial infarction of ACCF/AHA, this patient was diagnosed with anterior wall acute myocardial infarction based on the above evidences [1]. Immediately, aspirin 300 mg and clopidogrel 300 mg were given by oral and 3000 units low-molecular heparin was given by subcutaneous injection. And urokinase 1.5 million units were given by intravenous administration in thirty minutes.

However, this patient reported that chest pain was not worsened in 120 minutes following fibrinolytic therapy. The second ECG after fibrinolytic therapy also showed that ST segment was elevated between 3 mm and 8 mm in precordial leads V1-V4 and depressed between 2 mm and 4 mm in limb leads II, III, and aVF (Figure 1B). The ST segment was also elevated about 2.5 mm in lead aVR suggested that thrombus invasion might involve the left main coronary artery. Physical examination also showed that his limbs were clammy. The ECG monitor showed that his blood pressure values dropped to the level of 65/46 mmHg under the support of the maximal dose of dopamine (20 ug/kg per min). What's more, ventricular fibrillation happened repeatedly about once every one minute. Cardio-pulmonary resuscitation and defibrillation were immediately done and his normal sinus rhythm was regained. Intra-aortic balloon counter-pulsation (IABP) was inserted into the right femoral artery and further advanced to near the level of the left subclavian artery, with the balloon inflated with helium during diastole. Under the support of IABP, the patient's hemodynamic condition recovered relatively stable and his blood pressure values were raised to a level of 85/55 mmHg. The frequency of ventricular fibrillation was also obviously decreased. In consideration of the patient's clinical conditions, the patient failed to be re-perfused by urokinase and rescue PCI was performed immediately through the right radial artery approach. Urgent coronary angiography (CAG) showed that the proximal segment of

the left anterior descending (LAD) coronary artery had a lesion with 95% stenosis and the middle to distal segment of the left circumflex artery (LCX) had a long lesion with 90% stenosis (Figure 2A). The distal segment of right coronary artery (RCA) had a lesion with 90% stenosis. Based on the appearance of his ECG, we thought that the LAD artery was his culprit vessel and then implanted a drug-eluting stent in the proximal segment of the LAD artery (Figure 2B). Then the hemodynamic condition recovered and his blood pressure was raised to 105/64 mmHg under the support of IABP and dopamine. The ECG after rescue PCI showed an obvious recovery in ST segment in the precordial leads V1-V4 and limb leads including II, III, aVF, and aVR (Figure 1C). This patient also reported that his chest pain was significantly reduced following the rescue PCI.



**Figure 1:** The evolution of ECG (10 mm/mv, 25 mm/s) for this patient at the time of admission (A), two hours following fibrinolytic therapy (B) and post-operation of rescue PCI (C).



**Figure 2:** Coronary angiography shows the culprit lesion of the proximal segment of the LAD coronary artery and the long lesion of the middle segment of the LCX coronary artery (A) and the results after the rescue PCI implanting a drug-eluting stent in the proximal segment of the LAD coronary artery (B).

## Discussion

As it is known to us all, primary PCI is currently the optimal reperfusion treatment for the patients with STEMI within the twelve hours from the ischemic symptoms onset according to the guidelines [1]. Primary PCI is superior to fibrinolytic therapy to dredge the infarct artery and acquire the higher rates of infarct artery patency and TIMI 3 flow. However, primary PCI was not firstly recommended for this patient due to both reasons. On the one hand, primary PCI could not be promoted in 120 minutes in our hospital. On the other hand,

there were not any obvious contraindications and complications with fibrinolytic therapy based on his clinical conditions. According to the guideline for the management of ST-elevation myocardial infarction and due to our limitations, fibrinolytic therapy was the first choice of treatment for this patient [1]. However, this patient still reported his chest pain was not worsened after two hours following fibrinolytic therapy and developed some conditions of cardiogenic shock included low blood pressure, clammy limbs, and incessant ventricular fibrillation. Based on the above evidences, we thought that fibrinolytic therapy was not successful for this patient. As it is known to us all, IABP is the most often used left ventricular assist device for hemodynamic support and can result in initial hemodynamic stabilization. Sanborn TA et al reported that treatment of patients in cardiogenic shock due to predominant LV failure with thrombolytic therapy, IABP and revascularization by PTCA/CABG was associated with lower in-hospital mortality rates than standard medical therapy [5]. What's more, they also suggested that a strategy of early thrombolytic therapy and IABP followed by immediate transfer for PTCA or CABG may be appropriate for hospitals without revascularization capability [5]. IABP used in cardiogenic shock is a class IB and class IC recommendation in American and European guidelines, which is partly challenged by a recent meta-analysis [6-8]. Sjaun KD et al. reported that IABP showed neither a 30-day survival benefit nor improved left ventricular ejection fraction, while being associated with significantly higher stroke and bleeding rates [8]. However, it was under the support of IABP that this patient's hemodynamic condition recovered to relative stabilization which gained time to adopt rescue PCI to save his life. Based on the limited randomized data, rescue PCI appears superior to conservative therapy following unsuccessful fibrinolysis and merits more frequent consideration [9,10]. What's more, both of the guidelines of European Society of Cardiology and American College of Cardiology/American Heart Association for the management of STEMI recommend urgent rescue PCI for patients who fail to achieve reperfusion by fibrinolytic therapy [11,12].

## Conclusion

In conclusion, we thought that IABP could improve the patients' hemodynamic conditions with cardiogenic shock complicated by acute myocardial infarction and was suggested as a bridge for urgent revascularization. More researches are also anticipated to assess the role of IABP and rescue PCI in patients with cardiogenic shock complicated by acute myocardial infarction.

## References

1. O'Gara PT, Kushner FG, Ascheim DD, Casey DD, Chung MK, et al. (2013) ACCF/AHA guideline for the management of ST-elevation myocardial infarction: a report of the American College of Cardiology Foundation/American Heart Association Task Force on Practice Guidelines. *J Am Coll Cardiol* 61: e78-e140.
2. Eagle KA, Goodman SG, Avezum A, Budaj A, Sullivan CM, et al. (2002) Practice variation and missed opportunities for reperfusion in ST-segment-elevation myocardial infarction: findings from the Global Registry of Acute Events (GRACE). *Lancet* 359: 373-377.
3. [No authors listed] (1993) An international randomized trial comparing four thrombolytic strategies for acute myocardial infarction. The GUSTO investigators. *N Engl J Med* 329: 673-682.
4. Mendoza CE, Bhatt MR, Virani S, Schob AH, Levine S, et al. (2007) Management of failed thrombolysis after acute myocardial infarction: an overview of current treatment options. *Int J Cardiol* 114: 291-299.

5. Sanborn TA, Sleeper LA, Bates ER, Jacobs AK, Boland J, et al. (2000) Impact of thrombolysis, intra-aortic balloon pump counterpulsation, and their combination in cardiogenic shock complicating acute myocardial infarction: a report from the SHOCK Trial Registry. *J Am Coll Cardiol* 36: 1123-1129.
6. Antman EM, Anbe DT, Armstrong PW, Bates ER, Green LA, et al. (2004) ACC/AHA guidelines for the management of patients with ST-elevation myocardial infarction-executive summary. *Circulation* 110: 588-636.
7. Van de Werf F, Bax J, Betriu A, Blomstrom-Lundqvist C, Crea F, et al. (2008) Management of acute myocardial infarction in patients presenting with persistent ST-segment elevation: the task force on the management of ST-segment elevation acute myocardial infarction of the European Society of Cardiology. *Eur Heart J* 29: 2909-2945.
8. Sjauw KD, Engström AE, Vis MM, van der Schaaf RJ, Baan J Jr, et al. (2009) A systematic review and meta-analysis of intra-aortic balloon pump therapy in ST-elevation myocardial infarction: should we change the guidelines? *Eur Heart J* 30: 459-468.
9. Gershlick AH, Stephens-Lloyd A, Hughes S, Abrams KR, Stevens SE, et al. (2005) Rescue angioplasty after failed thrombolytic therapy for acute myocardial infarction. *N Engl J Med* 353: 2758-2768.
10. Ellis SG, da Silva ER, Heyndrickx G, Talley JD, Cernigliaro C, et al. (1994) Randomized comparison of rescue angioplasty with conservative management of patients with early failure of thrombolysis for acute anterior myocardial infarction. *Circulation* 90: 2280-2284.
11. Van de Werf F, Ardissino D, Betriu A, Cokkinos DV, Falk E, et al. (2003) Management of acute myocardial infarction in patients presenting with ST-segment elevation. The Task Force on the Management of Acute Myocardial Infarction of the European Society of Cardiology. *Eur Heart J* 24: 28-66.
12. Antman EM, Anbe DT, Armstrong PW, Bates ER, Green LA, et al. (2004) ACC/AHA guidelines for the management of patients with ST-elevation myocardial infarction: a report of the American College of Cardiology/American Heart Association Task Force on Practice Guidelines (Committee to Revise the 1999 Guidelines for the Management of Patients With Acute Myocardial Infarction). *J Am Coll Cardiol* 110: 588-636.