

## Superior versus Inferior Conjunctival Autograft Using Fibrin Glue in Management of Primary Pterygium: Clinical and Histopathological Results

Ashraf Bor'i<sup>1</sup>, Mohamed A Elmarakby, Mahmoud E Saleh and Marwa Khairy

Faculty of Zagazig, Zagazig University, Elsharkia, Egypt

**Corresponding author:** Ashraf Bor'i, Zagazig Ophthalmology Department, University Faculty of Medicine, 22 Elshraei Street Elkawmia, Zagazig, Elsharkia 22486, Egypt, Tel: 00201065338080; E-mail: Ashborai@yahoo.com

**Received date:** June 28, 2016; **Accepted date:** August 01, 2016; **Published date:** August 05, 2016

**Copyright:** © 2016 Bor'i A, et al. This is an open-access article distributed under the terms of the Creative Commons Attribution License, which permits unrestricted use, distribution, and reproduction in any medium, provided the original author and source are credited.

### Abstract

**Purpose:** To evaluate the differences between superior and inferior conjunctival autografts with fibrin glue in management of primary pterygium as regard surgical difficulties, duration, recurrence, complications and stem cell density.

**Patients and methods:** In a prospective one stage randomized controlled study, 36 patients with primary pterygium were included in the study and assigned into 2 groups. Group A received superior and group B received inferior conjunctival auto graft each group comprised 18 patients. All eyes were followed up at day 1 and 3 and at first week, first month, 3 month and finally 6 month post-operatively. All the intraoperative and postoperative data were analyzed.

**Results:** 36 patients with pterygium were included in this study and 17 patients were males and 19 were females with average follow up period of  $7.5 \pm 0.6$  months. Mean age was  $52.5 \pm 5.9$  years and  $46.2 \pm 11.7$  years respectively, the mean size of pterygium was  $12.1 \pm 3.4$  mm<sup>2</sup>  $11.3 \pm 2.1$  mm<sup>2</sup> respectively. Mean size of the autograft was  $26.9 \pm 6.7$  mm<sup>2</sup>, and  $27 \pm 5.6$  mm<sup>2</sup> respectively. The mean surgical time was  $17.8 \pm 2.0$  minutes and  $17.5 \pm 2.4$  minutes respectively. Mean follow up period was  $7.4 \pm 0.6$  months and  $7.6 \pm 0.7$  months respectively. There was one recurrent case in each group. No difference in stem cell density between 2 groups.

**Conclusions:** Inferior autograft with fibrin glue has the same advantages as superior one as regard rate of recurrence and surgical time but superior to it as regard patient discomfort and saving superior conjunctiva sparing it for future glaucoma surgery if needed.

**Keywords:** Conjunctival autograft; Fibrin glue; Primary pterygium

### Introduction

Pterygium is a fibrovascular growth of the conjunctiva extending across the limbus to invade the cornea at a variable distance. The exposure to ultraviolet rays is a presumed aetiology and hence it is more common in people in countries with hot climate [1].

Surgical removal of the pterygium is the permanent treatment; however recurrence is the main issue. Simple excision leads to high rates of recurrence which are reported to be as high as 89% [1]. Free conjunctival autograft which was first described by Kenyon et al. shows a low recurrence rate of 5.3%. Since then, many subsequent studies have found this surgical technique to be safe and effective in reducing the number of recurrences after pterygium surgery [2,3].

Superior conjunctiva is the most common site for harvesting donor autograft in pterygium surgery but sometimes it is difficult or not recommended to take the conjunctival autograft from the superior conjunctiva as in scarring of the superior conjunctiva due to previous surgery or trauma or post infection; patients who have had filtration surgery; patients with glaucoma who may require future filtration surgery. Previous publications on the use of inferior conjunctival autograft in the management of pterygia have been limited to

noncomparative case series, with the use of sutures to secure the graft [4].

Koranyi et al. were the first to describe the use of fibrin glue for conjunctival grafting in pterygium surgery. They found that using fibrin glue instead of sutures in pterygium surgery causes better outcome and significantly shortens the time of the surgery [5].

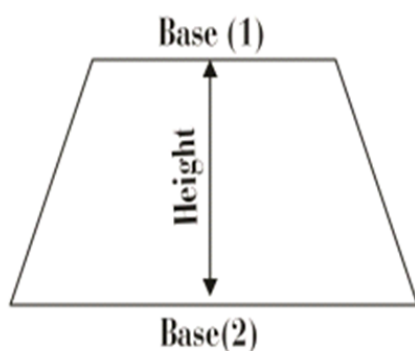
In this study we aim to evaluate the differences between superior and inferior conjunctival autografts using fibrin glue in surgical management of primary pterygium as regard recurrence rates, difficulties in the technique, surgical duration and complications.

### Methods

A prospective controlled study that included 36 patients with primary pterygium. Informed written consent was obtained from all patients including their acceptance to the maneuver and all possible complications that may be encountered. All surgeries were done in Zagazig University Hospital during the period from January 2013 to January 2014. The study was approved by the institutional board of Zagazig University (ZU-IRB) at the start of the study and adhered to the tenets of Helsinki declaration. The patients were randomly assigned into two groups: (group A) superior conjunctival autograft that serves as the control group and (group B) inferior conjunctival autograft group with 18 cases in each group.

Inclusion criteria included patients with primary active pterygium. Patients with symblepharon or conjunctival scar, double-head pterygia, previous ocular trauma, cases with clinically apparent limbal stem cell deficiencies apart from site of pterygium occurrence, patients with previous intraocular or ocular surface surgery and patients with recurrent pterygium were excluded from the study.

Data collected from each patient included medical and ocular history especially any previous intraocular surgery. General ophthalmic examination was done and the pterygium size measured (approximated to be the trapezoid area of tissue on the cornea calculated by the following formula:  $\text{area} = \text{height} \times (\text{base 1} + \text{base 2}) / 2$  (Figure 1).



**Figure 1:** The trapezoid area of Pterygium size.

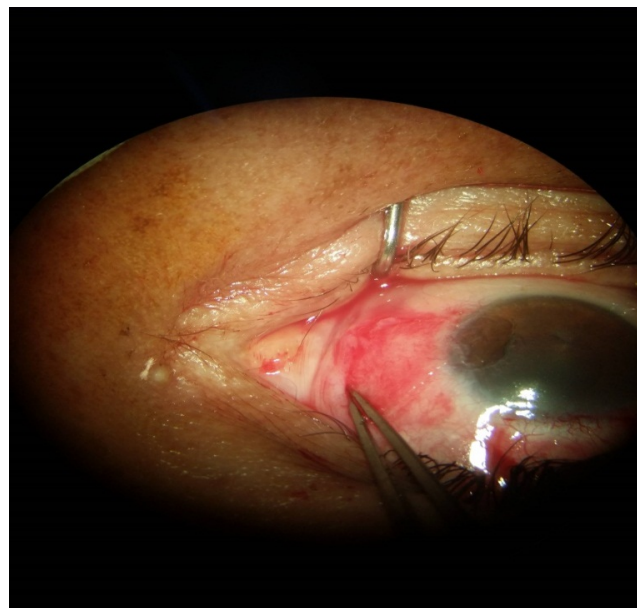
### Surgical technique

Fibrin glue (Fibrogloo, Cairo Medical Center Blood Bank) was prepared preoperatively by adding 1 ml of distilled water into each reagent (R1: thrombin, R2: fibrinogen). After sterilization and preparation of involved eye, topical 0.4% Benoxinate HCL was instilled.

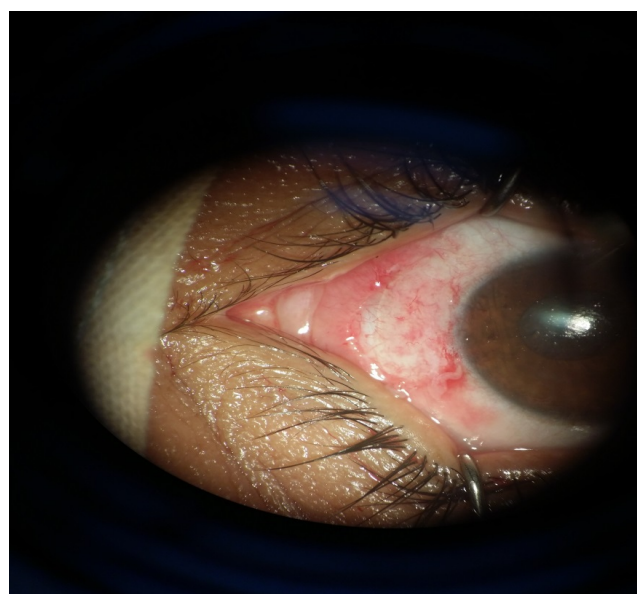
The area to be excised was marked with marker pen and 1% lidocaine hydrochloride with epinephrine 1:100,000 were injected subconjunctivally beneath the pterygium body. All surgeries were performed by a single surgeon using the bare sclera technique. Briefly, the head of the pterygium was excised using avulsion technique and the body was dissected from the sclera. Thereafter, the remnants of the pterygium tissue was dissected from the limbal region using Beaver blade No 15. Tenon's layer was removed with cautery to the underlying blood vessels. The site of conjunctival autograft was marked with marker pen and its size was measured. After graft preparation the thrombin solution was applied to the scleral bed and fibrinogen to the autograft under surface in all cases. The donor area was left with the Tenon overlying sclera.

The surgical time was recorded from the time the marking began to the removal of the lid speculum. Topical 0.3% tobramycin and 0.1% dexamethasone ophthalmic eye drops were given 4 times daily for 1 week, followed by a slow taper over 6 weeks.

Every patient was then followed at day 1 and 3 and at first week, first month, 3 month, 6 month and finally 12 month post-operatively. All the intraoperative and postoperative complications were carefully detected, managed and reported (Figures 2a-2c).



**Figure 2a:** Autograft taken from inferior conjunctiva fixed with fibrin glue.



**Figure 2b:** One week postoperative.

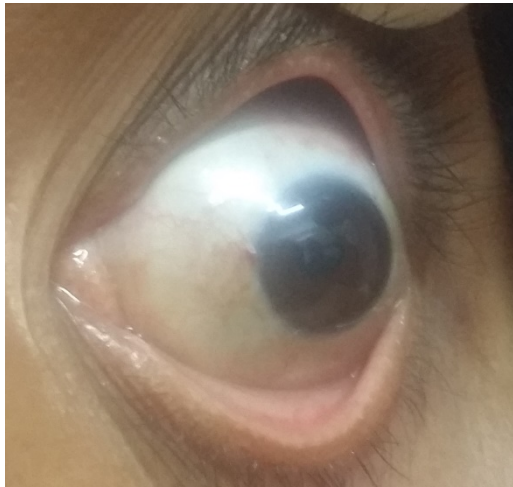

Figure 2c: Three months postoperative.

### Immunohistochemical staining of limbal stem cells with P63

Histopathological slides of patients from the superior limbus and the inferior limbus of each patient were taken intraoperative and sent for the histopathologist to be stained using the Immuno-histochemical staining P63.

Immunohistochemical staining was carried out using streptavidin-biotin immunoperoxidase technique. Three to five micrometer thick sections cut from formalin fixed paraffin embedded blocks. The slides were incubated overnight using 1:60 dilution of the 4A4 mouse monoclonal antibody (Lab Vision Corporation, Santa Cruz), which binds to all isoforms of p63. After a buffer rinse, bound antibodies were detected with the DAKO Envision System. Slides were counterstained with Hematoxylin and Eosin stain.

Each slide was evaluated at 40 X magnification by a pathologist in order to find areas with maximum positive nuclei. Then these areas were examined at 400 X magnification and the percentage of positive nuclei to total nuclei was calculated. In this study, at least 100 cells were counted and only the cells that were definitely positive were considered.

The percentage of tissue that stained for P63 was evaluated in a semi-quantitative fashion using the following scale: <10%, 10%-50%, 50%-90%, and >90%. The percentage of stained nuclei was compared between slides obtained from the superior and the inferior limbus. The same maneuvers were repeated at the end of follow up period in order to compare the stem cell population density with preoperative density.

Data were collected, tabulated and statistically analyzed using SPSS version 17 for the detection of significant values. Student's t-test was used to compare means and P value was calculated for significance.

### Results

Thirty-six patients with primary nasal pterygium were included in this study. Mean age was  $49.3 \pm 10.9$  years, 17 patients were males and 19 were females with average follow up period of  $7.5 \pm 0.6$  months. They were divided into two groups superior conjunctival graft

(group A) and inferior conjunctival graft group (group B) with 18 cases in each group.

The mean age for (group A) was  $52.5 \pm 5.9$  years. The mean age for (group B) was  $46.2 \pm 11.7$  years. P value between the two groups was 0.07 which was statistically insignificant.

In the (group A) 9 males and 9 females were included and for the (group B) 8 males and 10 females were included. P value between the two groups was 0.73 which was statistically insignificant.

The mean size of pterygium in (group A) was  $12.1 \pm 3.4$  mm<sup>2</sup>, and in (group B) was  $11.3 \pm 2.1$  mm<sup>2</sup> with P value 0.38 which was statistically insignificant. The mean size of the conjunctival autograft in (group A) was  $26.9 \pm 6.7$  mm<sup>2</sup>, and in (group B) was  $27 \pm 5.6$  mm<sup>2</sup> with P value 0.97 which was statistically insignificant Table 1.

	Superior	Inferior	t	P
Size of pterygium (mm <sup>2</sup> )				
X ± SD	12.1 ± 3.4	11.3 ± 2.1	0.88	0.38
Range	9-18	8-16		
Size of CAU (mm <sup>2</sup> )				
X ± SD	26.9 ± 6.7	27 ± 5.6	0.02	0.97
Range	20-35	16-35		

Table 1: Shows the clinical data of the patients.

The mean surgical time in (group A) was  $17.8 \pm 2.0$  minutes and in (group B) was  $17.5 \pm 2.4$  minutes, with P value 0.59 which was statistically insignificant. The mean follow up period in (group A) was  $14.8 \pm 0.6$  months, and in (group B) was  $14.97 \pm 0.7$  months, with P value 0.55 which was statistically insignificant (Table 2).

There was one recurrent case in (group A) (5.6%) and one in (group B) (5.6%) noted in the first month of follow up period both were less than one mm of fibrovascular growth across the limbus. There was no statistical significant in recurrence rates between the two groups.

	Sup	Inf	t	p
Follow up (months)				
X ± SD	4.8 ± 0.6	4.97 ± 0.7	0.65	0.55
Range	4-5.5	4-6		
Surgical time (minutes)				
X ± SD	17.8 ± 2.0	17.5 ± 2.4	0.53	0.59
Range	15-20	15-22		
Recurrence				
No	17 94.4%	17 94.4%	0.0	1.0
Yes	1 5.6%	1 5.6%		

Table 2: Shows the follow up period, surgical time and recurrence in the 2 groups.

Our study found that there is no difference in the density of limbal epithelial stem cells which stained positive by P63 immuno-stain

between (group A) and (group B) and also, no difference in the density before and after surgery in the same group (Figures 3a-3d).

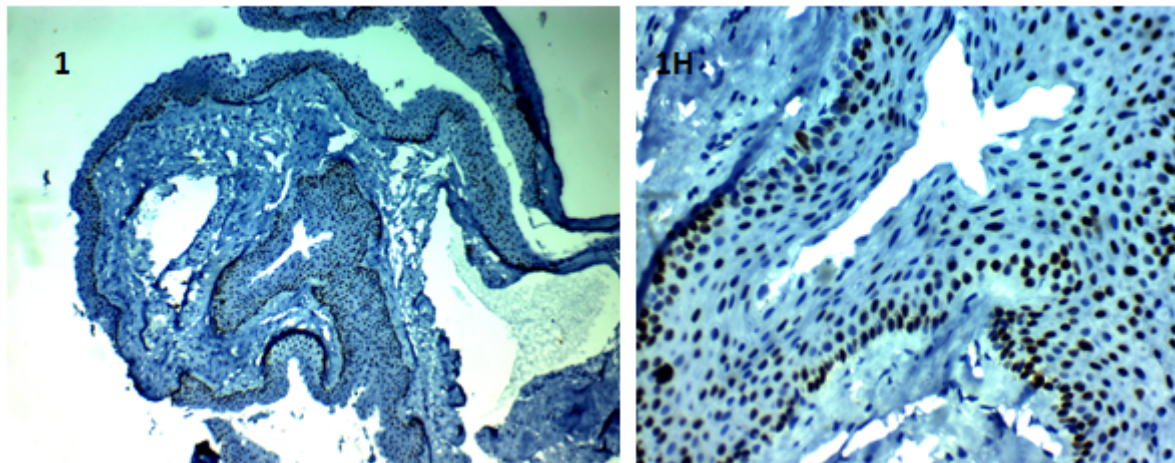


Figure 3a: Low and high magnification photos of stem cell density from superior conjunctiva taken intraoperative.

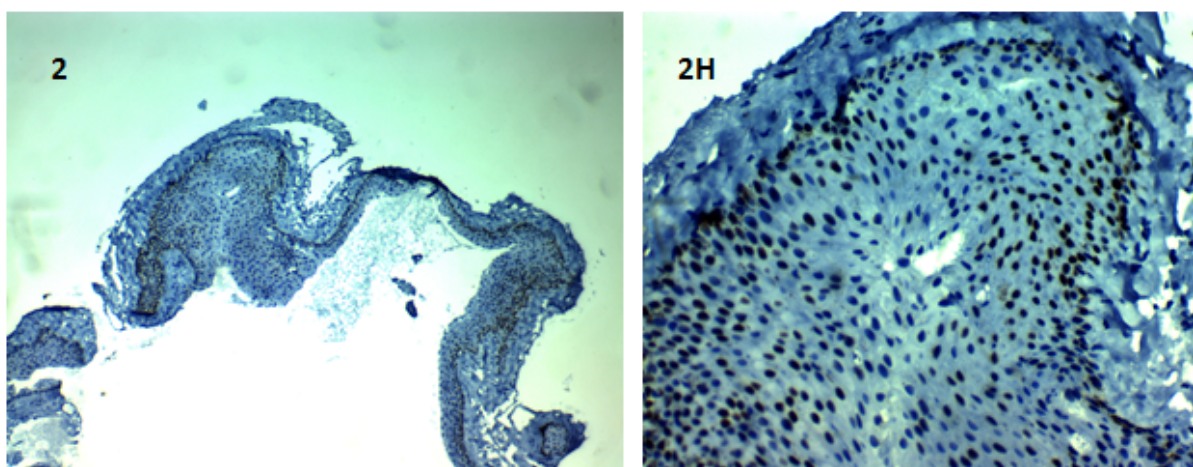


Figure 3b: Low and high magnification photos of stem cell density from inferior conjunctiva taken intraoperative.

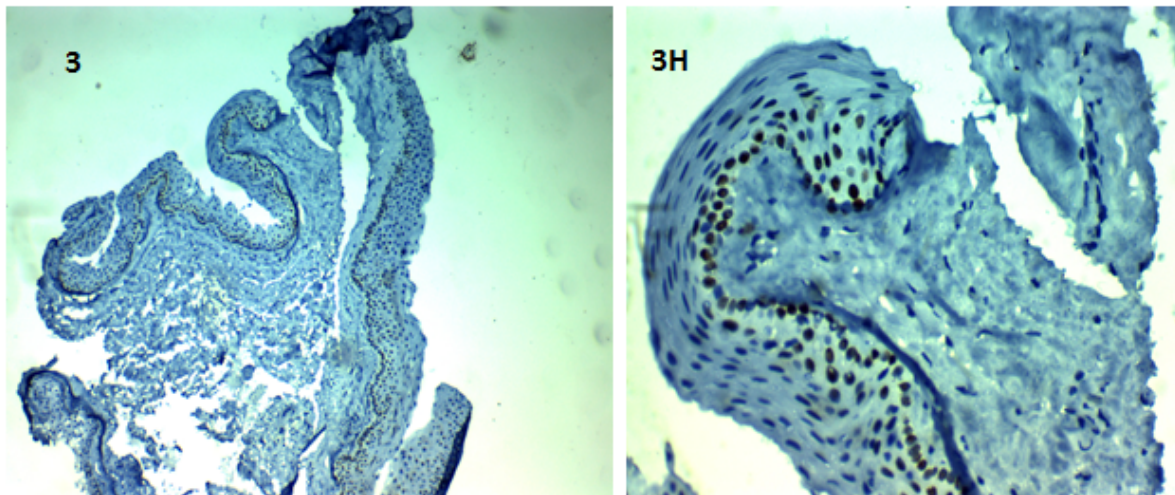
## Discussion

Conjunctival autograft is considered to be the standard surgical treatment for Pterygium with variable recurrence rates varying from 2% to 39%. Results may be ameliorated when fibrin glue is used with further reduction in the rate of recurrence [4].

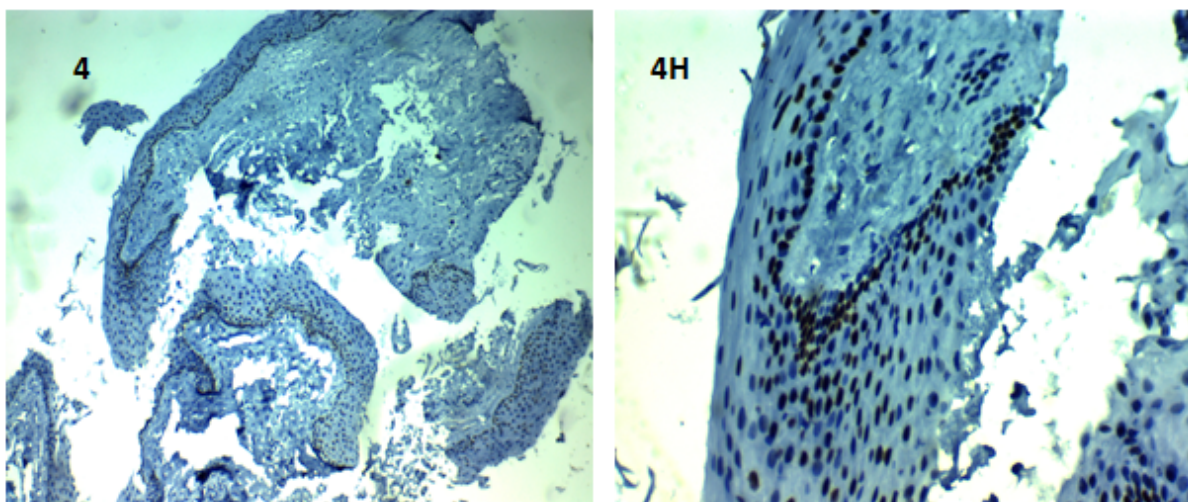
Taking a conjunctival autograft from the superior bulbar area is sometimes unfeasible due to scarring, ocular surface disease or previous trabeculectomy. In these circumstances, taking the autograft from the fellow eye superior conjunctiva or from the inferior conjunctiva of the same eye is an alternative. Harvesting the inferior bulbar conjunctiva is thought to be more technically difficult to obtain a large thin graft, and has a risk of symblepharon formation. However, inferior conjunctival autografting is associated with less irritation during blinking with

preservation of the superior conjunctiva for future glaucoma surgery [6].

In our study 36 patients with primary pterygium were included and divided into two groups with 18 cases in each group treated with conjunctival autograft from superior or inferior conjunctiva. In both groups fibrin glue was used in attaching the autograft, the recurrence rate in the superior group was 5.6% and in the inferior was 5.6%, similar study was done by Chen et al. which included 60 eyes divided into two groups superior and inferior groups with one eye in the superior group (4.2%) and one eye in the inferior group (4.0%) developed pterygium recurrence [4]. Our higher recurrence may be attributed to the lower case number, different surgical maneuver in pterygium excision and different demographic distribution.



**Figure 3c:** Low and high magnification photos of stem cell density from superior conjunctiva autograft taken 6 months postoperative.



**Figure 3d:** Low and high magnification photos of stem cell density from inferior conjunctiva autograft taken 6 months postoperative.

Koc et al. demonstrated that autografting from superior or inferior sites in primary pterygium cases showed no significant difference in recurrence rate which Supports our results, but in the event of recurrent pterygia, autografting from the inferior site resulted in a significantly ( $P=0.166$ ) higher likelihood of recurrence [7].

Shrestha et al. summarized the outcomes of 50 eyes undergoing inferior conjunctival autografting for primary pterygia. Recurrence in 2 eyes was noted (4%) [8].

All these studies used sutures to secure the donor conjunctival autograft.

Koranyi et al. reported recurrence rate of 5.3% for glue versus 13.5% for sutures and suggested that immediate adherence of the graft and lack of postoperative inflammation may inhibit fibroblast ingrowth

and reduce the recurrence [5]. Our low recurrence rates support these findings.

In this study the mean size of pterygium in  $\text{mm}^2$  measured by caliper in superior group was  $12.1 \pm 3.4 \text{ mm}^2$  and in inferior group was  $11.3 \pm 2.1 \text{ mm}^2$  with P value 0.38 which was statistically insignificant. The mean size of conjunctival autograft in  $\text{mm}^2$  in superior group was  $26.9 \pm 6.7 \text{ mm}^2$ , and in inferior group was  $27 \pm 5.6 \text{ mm}^2$  with P value 0.97 which was statistically insignificant. The autografts were harvested larger than the excised pterygium to send part of it for histopathological examination. The mean surgical time in superior group was  $17.8 \pm 2.0$  minutes, and in inferior group was  $17.5 \pm 2$ , with P value 0.59 which was statistically insignificant.

In all cases of our study fibrin glue (Fibrogloo) showed perfect adhesion of the autograft, however in one case adhesion was not

sufficient in one edge and sutured to the conjunctiva. Foroutan et al. reported 13.33% rate of graft dehiscence using autologous fibrin and attributed this to a low concentration of thrombin and fibrinogen in autologous glue compared to a commercial preparation [9].

Graft retraction was reported by Tan, who suggests improper dissection of the conjunctiva from the Tenon during graft preparation and recommended meticulous dissection of graft tissue [10]. Also Foroutan et al. reported 20 % of cases with graft retraction and gave the same explanation [9]. However Wit et al. reported no graft displacement and postulated that sutureless autografts resulted in even tension across the whole graft interface and no direct tension on the free edges resulting in reduced stimulus for sub-conjunctival scar formation [11]. He also proposed that the apposition of the eye lids to the bulbar conjunctiva provides a natural biological dressing, compression, and a smooth frictionless surface. Our results were the same with no cases of graft retraction noticed during the follow up period.

Our study reported subconjunctival scarring in 3 cases of the inferior group (16.6%). Also one case developed symblepharon (5.5%) without epiphora and managed by simple excision of fibrous bands with direct closure. A similar finding for minor complications was found by Shrestha et al. with conjunctival scarring rate at the donor site was only 8%. This could be due to their short follow-up period [8].

Most of the patients were cosmetically satisfied in postoperative follow up visits. Patients receiving inferior conjunctival autograft did not experience more postoperative discomfort when compared with superior conjunctival autograft.

Our study found that there is no difference in the density of limbal epithelial stem cells which stained positive by P63 immuno-stain between superior and inferior limbus in the same patient and also the same density before and after surgery, this may supports the similar recurrence rates in both superior and inferior groups.

## Conclusions

Inferior autograft with fibrin glue has the same advantages as superior one as regard rate of recurrence and surgical time but

superior to it as regard patient discomfort and saving superior conjunctiva sparing it for future glaucoma surgery if needed.

## References

1. Jaros PA, DeLuise VP (1988) Pingueculae and pterygia. *Surv Ophthalmol* 33: 41-49.
2. Kenyon KR, Wagoner MD, Hettinger ME (1985) Conjunctival autograft transplantation for advanced and recurrent pterygium. *Ophthalmology* 92: 1461-1470.
3. Rao SK, Lekha T, Sitalakshmi G, Padmanabhan P (1997) Conjunctival autograft for pterygium surgery: how well does it prevent recurrence. *Ophthalmic Surg Lasers* 28: 875-877.
4. Chen Q, Li Y, Xu F, Yan Y, Lu K, et al. (2015) Comparison of Inferior and Superior Conjunctival Autograft for Primary Pterygium. *Curr Eye Res* 40: 786-791.
5. Koranyi G, Seregard S, Kopp ED (2004) Cut and paste: a no suture, small incision approach to pterygium surgery. *Br J Ophthalmol* 88: 911-914.
6. Kim S, Yang Y, Kim J (1998) Primary pterygium surgery using the inferior conjunctival transposition flap. *Ophthalmic Surg Lasers* 29: 608-611.
7. Koc F, Demirbay P, Teke MY (2002) Primary and recurrent pterygium conjunctival autografting. *T Oft Gaz* 32: 583-588.
8. Shrestha A, Shrestha A, Bhandari S, Maharjan N, Khadka D, et al. (2012) Inferior conjunctival autografting for pterygium surgery: an alternative way of preserving the glaucoma filtration site in far western Nepal. *Clin Ophthalmol* 6: 315-319.
9. Foroutan A, Beigzadeh F, Ghaempanah MJ (2011) Efficacy of autologous brin glue for primary pterygium surgery with conjunctival autograft. *Iranian J Ophthalmol* 23: 39-47.
10. Tan D (1999) Conjunctival grafting for ocular surface disease. *Curr Opin Ophthalmol* 10: 277-281.
11. de Wit D, Athanasiadis I, Sharma A, Moore J (2010) Sutureless and glue-free conjunctival autograft in pterygium surgery: a case series. *Eye (Lond)* 24: 1474-1477.