

Superior Vena Cava Syndrome as the Preliminary Manifestation of Hodgkin's Lymphoma in A 31 Year Old Female Patient: A Case Report

Davis Kibirige*

Department of Medicine, Uganda Martyrs Hospital Lubaga, Kampala, Uganda

Abstract

Superior vena cava syndrome is a medical emergency frequently associated with malignancy especially lung cancer and non Hodgkin's lymphoma. It is a constellation of signs and symptoms resulting from intrinsic or extrinsic obstruction of the superior vena cava. I present a case of a 31 year old female patient who presented with classical features of superior vena cava syndrome secondary to histopathologically confirmed Hodgkin's lymphoma. She significantly improved following therapy with oxygen, intra venous steroids and chemotherapy (doxorubicin, bleomycin, vinblastine and dacarbazine). This case report highlights one of the atypical presentations of Hodgkin's lymphoma. Clinicians in emergency care units should have a high index of suspicion of superior vena cava syndrome so that timely treatment is instituted promptly.

Keywords: Superior vena cava syndrome; Hodgkin's lymphoma; Case report

Introduction

Superior Vena Cava Syndrome (SVCS) is caused by gradual compression of the Superior Vena Cava (SVC), a major vessel in the superior mediastinum that collects venous return to the heart from the head, arms and the upper torso [1]. In clinical practice, SVCS is predominantly associated with malignancies that cause extrinsic compression. The commonly documented malignancies are lung carcinoma and non-Hodgkin's lymphoma. Hodgkin's lymphoma despite its common presentation with marked mediastinal lymphadenopathy infrequently causes SVCS [1-3]. Intrinsic compression of the SVC due to thrombosis is recently on the increase due to the use of pacemakers, central venous catheters, defibrillators and dialysis catheters [4-7].

SVCS has a very characteristic pattern of clinical presentation. Compression results into increase in resistance to venous blood flow with consequent collateral vessel formation, oedema of the head, neck and arms, cyanosis and plethora. Oedema may cause functional laryngeal or pharyngeal dysfunction which typically manifests as cough, hoarseness of the voice, stridor and dysphagia. Cerebral oedema is an extremely fatal complication of SVCS and is often associated with increased mortality [1].

Below I discuss a case of Hodgkin's lymphoma presenting initially as SVCS, a very atypical form of manifestation of this type of malignancy.

Case Report

A 31 year old HIV sero-negative female presented to our emergency medical unit with a 6 month history of progressive neck swelling associated with a one week history of gradual shortness of breath aggravated mainly in supine position and relieved on sitting upright. She also presented with generalised chest pain, mild in intensity and dull in nature associated with a persistent dry cough present at all times of the day, low grade fever and drenching night sweats.

During this same period, she noticed that she had developed swelling of the face which was of an insidious onset. She gave no history of swelling of the hands, dysphagia, hoarseness of the voice, dysphagia, recurrent headaches and blurring of vision.

She was a housewife by occupation and did not smoke cigarettes.

On general examination, she appeared very sick, was a febrile with

an axillary temperature of 36.7°C and in mild respiratory distress. She had marked facial oedema, partial ptosis of the right eye and palpable lymph nodes in the anterior and posterior triangles of the neck. The lymph nodes were solitary, freely mobile, non tender and firm. There was no pallor, cyanosis, finger clubbing or jaundice. Her neck was swollen with distended, non pulsatile veins and also had superficial downward flowing collaterals over the upper aspect of the chest. There were no features of enlarged or retrosternal goitre.

On examination of the respiratory system, her oxygen saturation was 89% on room air. She had a dullness percussion note on the left infra-clavicular, infra-axillary, supra and infra scapular areas with reduced intensity of breathe sounds in that area. On central nervous system examination, she was fully conscious with partial right ptosis, miosis of the right pupil, anhidrosis and enophthalmos on the right side. Cardiovascular and abdominal examinations were essentially uneventful.

Basing on the conventional clinical features of facial and neck swelling with distended neck veins, shortness of breath in supine position, superficial chest collaterals, generalised cervical adenopathy, partial ptosis, miosis and anhidrosis, a provisional diagnosis of SVCS-mild/ grade 1 severity basing on the Yale University Thoracic Oncology Program proposed classification of SVCS [8] and Horner's syndrome secondary to a mediastinal malignancy was made (Table 1).

Clinical investigations performed included a complete blood count that showed a normal total white blood cell count of 8,420 cells/mm³ (Normal: 4,000-10,000), haemoglobin level of 12.7 g/dl and platelet count of 320,000 cells/mm³ (Normal: 150,000-400,000). Liver and renal function tests, serum calcium and uric acid levels done were within normal range.

An antero-posterior chest X-ray done revealed a widened superior

*Corresponding author: Davis Kibirige, Department of Medicine, Uganda Martyrs Hospital Lubaga, P.O.Box 14130, Kampala, Uganda, Tel: 256 414 267012, +256 782 393955; E-mail: davouirek@yahoo.co.uk

Received February 18, 2013; Accepted April 16, 2013; Published April 19, 2013

Citation: Kibirige D (2013) Superior Vena Cava Syndrome as the Preliminary Manifestation of Hodgkin's Lymphoma in A 31 Year Old Female Patient: A Case Report. Emergency Med 3: 136. doi:10.4172/2165-7548.1000136

Copyright: © 2013 Kibirige D. This is an open-access article distributed under the terms of the Creative Commons Attribution License, which permits unrestricted use, distribution, and reproduction in any medium, provided the original author and source are credited.

mediastinum with a left para hilar density. The trachea was compressed and displaced to the right. The main bronchus was obliterated and the visualised lungs showed no infiltrates (Figure 1).

The neck ultrasound scan done showed normal sized thyroid gland with no retrosternal extension. A contrast enhanced chest CT scan was not done due to financial constraints. Abdominal scan, bone marrow biopsy, electrocardiography and echocardiography done were also essentially normal.

A lymph node in the posterior triangle of the neck was biopsied under local anaesthesia prior to initiation of any therapy and sent for histopathological analysis which revealed large pleomorphic cells with some Reed Sternberg like giant cells suggestive of nodular sclerosing classic Hodgkin's lymphoma, a type of classical Hodgkin's lymphoma. Immuno-histochemistry to supplement the histological diagnosis was not done due to financial limitations. Based on the above clinical workup, the final diagnosis made was SVCS and Horner's syndrome secondary to Hodgkin's lymphoma-nodular sclerosing, Ann Arbor clinical stage III B.

The patient was treated with intravenous frusemide, dexamethasone and high flow oxygen via nasal prongs on an elevated head of bed. There was marked symptomatic improvement with an increase in the measured oxygen saturation to 98% on room air in 2 days.

She was later referred to the Uganda Cancer Institute (UCI), Kampala where she was started on a full course of chemotherapy (doxorubicin, bleomycin, vinblastine and dacarbazine). Currently, the

patient is doing well and is undergoing regular clinical reviews at the UCI.

Case Discussion

SVCS is a clinical manifestation of SVC occlusion due to external compression by malignancy or intrinsic blockage by thrombosis of the SVC. The SVC forms the prime venous drainage system for blood flowing from the hands, head and the neck. Owing to its location (mediastinum) and its thin walled structure, it is highly susceptible to compression by malignancy, enlarged thymus, aortic aneurysm and mediastinal lymphadenopathy [1-2]. Its obstruction is associated with formation and blood flow through collateral vessels. These include azygos, intercostal, mediastinal, paravertebral, hemiazygos, internal mammary, thoracoepigastric and anterior chest wall veins [9].

Majority of the clinical cases of SVCS (about 90%) occur exclusively secondary to extrinsic compression by malignancy. Lung cancer, predominantly non small cell and small cell lung carcinoma, metastatic tumours and non-Hodgkin's lymphoma account for up to 85% of all cases of SVCS due to malignancy [2].

Hodgkin's lymphoma despite presenting with mediastinal lymphadenopathy infrequently causes SVCS [2-3]. Often, patients are asymptomatic at presentation with only clinically evident enlarged cervical adenopathy or enlarged mediastinum on chest radiography.

Our patient presented with the classical signs and symptoms of SVCS (progressive facial and neck swelling, engorgement of neck veins, dyspnea in supine position and relieved on sitting up, chest pain) described consistently in medical literature secondary to Hodgkin's lymphoma, a malignancy that unusually presents with SVCS as earlier discussed.

Hodgkin's lymphoma may also sporadically present with pruritis and alcoholic induced pain within the lymph nodes [3]. It has also been documented as a cause of Horner's syndrome, another infrequent clinical presentation of Hodgkin's lymphoma, as illustrated in this case report. Horner's syndrome is a constellation of signs that occur due to disruption of the cervical sympathetic pathway. Its diagnosis is made basing essentially on the presence of these clinical signs: miosis, partial ptosis, apparent enophthalmos and anhidrosis. Other rare features include facial flushing, transient lowering of intra-ocular pressure and hemi-atrophy of the face [10].

Since the SVC is a significant blood vessel in the venous drainage of the head, upper extremities and thorax, engorgement of those regions of the body occurs in patients with SVCS. However, the severity of the clinical presentation of SVCS ranging from mild or grade 1 to fatal or grade 5 will entirely depend on the degree of SVC obstruction. The rapidity of onset of presentation of the signs and symptoms of SVC will also depend on the rate of obstruction of the SVC and collateral formation [8].

As discussed, the patient presented with mild or grade 1 SVCS with the initial symptom being present for 6 months while the dyspnea and facial swelling developing in a week. This suggests a less significant extent and slower rate of SVC obstruction by the causative malignancy. This grading of severity of SVCS is based on the Yale University Thoracic Oncology Program proposed classification [8] (Table 1).

Radiological imaging is also very essential in complementing a clinical examination in the making of a diagnosis of SVCS. Majority of the patients have abnormal chest X-rays with a widened mediastinum and bilateral pleural effusions the commonest radiological findings [1]. Our patient's chest radiography showed mediastinal widening,

Grade	Category	Definition of grade
0	Asymptomatic	Radiographic superior vena cava obstruction in the absence of symptoms
1	Mild	Oedema in head or neck (vascular distension), cyanosis, plethora
2	Moderate	Oedema in head or neck with functional impairment (mild dysphagia, cough, mild or moderate impairment of head or jaw or eye lid movements or presence of visual disturbances).
3	Severe	Mild or moderate cerebral oedema (headache, dizziness) or mild/moderate laryngeal oedema or diminished cardiac reserve (syncope after bending)
4	Life threatening	Significant cerebral oedema (confusion, obtundation) or significant laryngeal oedema (stridor) or significant hemodynamic compromise
5	Fatal	Death

Table 1: Grading of severity of SVCS based on the Yale University Thoracic Oncology Program proposed classification of SVCS.

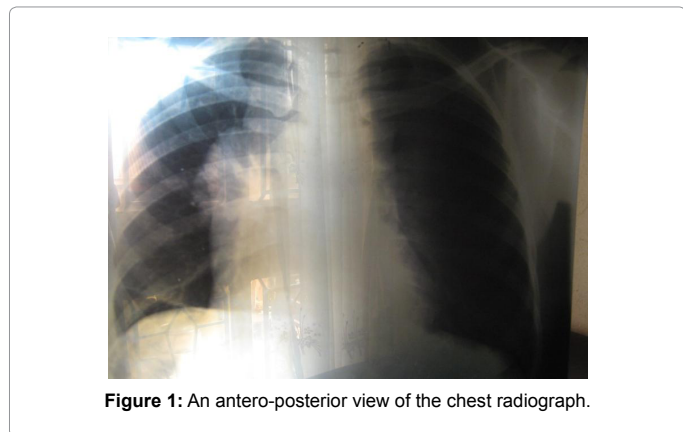


Figure 1: An antero-posterior view of the chest radiograph.

hilar adenopathy, tracheal deviation to the right, obliteration of the bronchus and bilateral pleural effusions. The lung fields were normal.

A contrast enhanced chest Computed Tomography (CT) is the most useful radiological investigation in patients with SVCS because it clearly identifies the cause of the SVC obstruction (whether intrinsic due to thrombosis or extrinsic due to malignancy), level and extent of SVC obstruction and extent of collateral system formed. The most frequent findings on a chest CT are paratracheal adenopathy with or without lung or pleural abnormalities [1,11,12]. However, CT scans are not readily available in the majority of resource limited settings like ours. When present, the cost of the investigation is prohibitive for most patients, like in this patient i have discussed.

Therapy of SVCS is divided into supportive and definitive treatment. Supportive measures like providing high flow oxygen, elevation of the head of bed, fluid limitation, diuretics and steroid therapy help in short term relief of oedema related symptoms. An emphasis should be made to identify symptoms suggestive of upper airway compromise like stridor and cerebral oedema and promptly manage them since both are associated with high mortality. Elevation of the head of bed, steroid therapy and the use of osmotic diuretics are standard supportive measures in such instances [1].

Definitive treatment involves management of the precise cause of the SVCS. Intrinsic causes like thrombosis are managed with thrombolysis. Catheter induced SVCS is managed with anticoagulants, thrombolysis and endovascular treatment. In cases of malignancy, appropriate chemotherapy with or without radiation often offer marked symptomatic relief [1]. The patient discussed was nursed on an elevated head of bed and received oxygen therapy, steroids and loop diuretics for management of the SVCS.

She also received chemotherapy for Hodgkin's lymphoma (doxorubicin, bleomycin, vinblastine and dacarbazine) from the regional oncology specialised treatment centre.

This chemotherapy combination of ABVD- doxorubicin, bleomycin, vinblastine and dacarbazine is the recommended and widely used in the management of Hodgkin's lymphoma globally. The patient was diagnosed with nodular sclerosis subtype of classical Hodgkin's lymphoma. Its histological features include sclerosis, nodules and lacunar cell variants of the classical Reed Sternberg cells with presence of fibrous bands. This is the only sub-type associated with a higher female predominance and common among younger patients (median age of 28 years) as illustrated in this case report. Majority of patients with this subtype present with bulky mediastinal disease and in Ann Arbor clinical stage II [3].

The identified poor prognostic factors among patients with Hodgkin's lymphoma as derived from the International Prognostic Index include serum albumin <4 g/l, haemoglobin level <10.5 g/dl, male gender, stage IV disease, age ≥45 years, white blood cell count >15,000/mm³, absolute lymphocyte count <600/μl or <8% of the total white blood cell count. One point is accorded each criterion and the higher the score, the worse the prognosis. Our patient had a very favourable score (no point on scoring) [13].

Conclusion

SVCS is typically encountered in patients with malignancies (especially in patients with lung cancer and non-Hodgkin's lymphoma). Hodgkin's lymphoma infrequently presents with SVCS despite marked associated mediastinal lymphadenopathy. The striking clinical presentation of SVCS is facial and neck swelling with accompanying engorgement of neck vessels, dyspnea especially in supine position and collateral formation. It is imperative that a histological diagnosis is made prior to initiation of supportive or definitive treatment as this may obscure the diagnosis. Chemotherapy with or without radiation is the mainstay of treatment for most patients presenting with SVCS. Thrombolysis, anticoagulation and intravascular stenting are effective in cases of SVCS secondary to thrombosis.

References

1. Wan JF, Bezjak A (2009) Superior vena cava syndrome. *Emerg Med Clin North Am* 27: 243-255.
2. Wilson LD, Detterbeck FC, Yahalom J (2007) Clinical practice. Superior vena cava syndrome with malignant causes. *N Engl J Med* 356: 1862-1869.
3. Schnitzer B (2009) Hodgkin lymphoma. *Hematol Oncol Clin North Am* 23: 747-768.
4. Chee CE, Bjarnason H, Prasad A (2007) Superior vena cava syndrome: an increasingly frequent complication of cardiac procedures. *Nat Clin Pract Cardiovasc Med* 4: 226-230.
5. Venturini E, Becuzzi L, Magni L (2012) Catheter-induced thrombosis of the superior vena cava. *Case Rep Vasc Med* 2012: 469619.
6. Aryana A, Sobota KD, Esterbrooks DJ, Gelbman AI (2007) Superior vena cava syndrome induced by endocardial defibrillator and pacemaker leads. *Am J Cardiol* 99: 1765-1767.
7. Aggarwal SK, McCauley W (2005) Tunnelled central venous catheter-induced thrombosis: a rare case of superior vena cava syndrome. *CJEM* 7: 273-277.
8. Yu JB, Wilson LD, Detterbeck FC (2008) Superior vena cava syndrome--a proposed classification system and algorithm for management. *J Thorac Oncol* 3: 811-814.
9. Trigaux JP, Van Beers B (1990) Thoracic collateral venous channels: normal and pathologic CT findings. *J Comput Assist Tomogr* 14: 769-773.
10. Walton KA, Buono LM (2003) Horner syndrome. *Curr Opin Ophthalmol* 14: 357-363.
11. Schwartz EE, Goodman LR, Haskin ME (1986) Role of CT scanning in the superior vena cava syndrome. *Am J Clin Oncol* 9: 71-78.
12. Bechtold RE, Wolfman NT, Karstaedt N, Choplin RH (1985) Superior vena caval obstruction: detection using CT. *Radiology* 157: 485-487.
13. Armitage JO (2010) Early-stage Hodgkin's lymphoma. *N Engl J Med* 363: 653-662.