

Successful Treatment of Refractive Anisometropia with Prismatic Progressive Additional Lenses: A Technical Report

Li-Ju Lai^{1,2*} and Wei-Hsiu Hsu^{2,3}

¹Ophthalmology, Chang Gang Memorial Hospital, Chia-Yi, Taiwan

²Department of Chinese Medicine, College of Medicine, Chang Gang University, Kwei-San, Tao Yuan, Taiwan

³Department of orthopedics surgery, Chang Gang Memorial Hospital, Chia-Yi, Taiwan

*Corresponding author: Li-Ju Lai, MD, No.6, West section, Chia-Pu Road, Puzih City, Chia-Yi Hsien, 61363, Taiwan, Tel/Fax: 886-5-3621000 ext 2580; Email: lynnlai@cgmh.org.tw

Received date: Feb 20, 2015, Accepted date: May 28, 2015, Published date: May 30, 2015

Copyright: © 2014 Li-Ju Lai, et al. This is an open-access article distributed under the terms of the Creative Commons Attribution License, which permits unrestricted use, distribution, and reproduction in any medium, provided the original author and source are credited.

Abstract

Background: Anisometropia was a challenge for ophthalmologists to treat unilateral refraction condition. Failure of build-up the same clear image from two eyes together was the major cause for quitting spectacle wearing, which usually led to amblyopia in the eye with more myope.

Case presentation: The two patients with anisometropia were found that the two eyeballs position were asymmetric by photography (RTV, Carl Zeiss Meditec, Co). Binocular visual acuity was analyzed by using polarized lens in the both eyes for stereo-acuity in far vision (Polatest, Carl Zeiss, Germany) by following the guidelines from the Internationale Vereinigung für Binokulare Vollkorrektion (IVBV). Binocular vision was corrected by the stereo-acuity in the far vision, and prism measurement was done by subjective opinion from the patient.

Conclusion: Asymmetric eyeball position and size are the risk of anisometropia progression. Under the guidelines from MKH (Measuring and correcting Methodology after H.J.- Haase) for correction of associated phoria, the vision was corrected not only in the spherical and cylinder amount but also in binocular full-correction. Prism improved in binocular vision function in the far vision. By using the prismatic progressive additional lenses, the unilateral myopia progression was well controlled after followed for 4 years.

Keywords: Anisometropia; Myopia progression; Prism; Progressive addition lens

Introduction

Anisometropia, an interocular difference in refraction, is an important condition in children because it can lead to significant visual problems, including aniseikonia, impaired stereopsis, amblyopia and strabismus [1]. Treatment of anisometropic amblyopia with corrective lenses alone has been shown to improve vision by at least 2 Snellen lines in 77–93% of patients and completely resolve the condition in 27–45% of patients [2]. Unfortunately, spectacle fitting can be difficult in young children because patients often do not perceive an improvement in their vision from their glasses. Additionally, these young patients often feel dizzy and sometimes even develop headache from spectacle because of the asymmetry in lens weight and retinal image size. As a result, patient spectacle compliance is often poor. Without good alternative treatment strategies, the progression of unilateral myopia can occur, frustrating ophthalmologists and parents alike. In this case report, asymmetric ocular position occurred and served as a clue for ophthalmologists to detect the anisometropia. MKH3 has shown that correction of impaired binocular vision could mostly be achieved by fully correcting any existing phoria with prisms. Prismatic PAL provided accurate results and was a good tool to treat myopic progression.

Report of cases

Written informed consent was obtained from the patients' parents for the publication of the case report and the accompanying images.

Case 1

An 8 year old boy first presented at our clinical in May 2010 with a chief complaint of unilateral progression of myopia (-7.00 Diopters [D] over 3 years) in the right eye. The patient was born at a gestational age (G/A) of 39 weeks and had a birth body weight (BBWt) of 3220 gm. The uncorrected distance visual acuity (VA) was 20/400 OD and 20/30 OS. The best-corrected distance visual acuity (CDVA) was 1.00 in both eyes, with a cycloplegic manifest refraction of -7.5 OD/ -1.25 D × 175° OD and -0.50 D/-2.25 D × 180° OS. Intraocular pressure (IOP) in both eyes was normal, measuring at 12 mmHg OD and 13 mmHg OS. The axial length (AL), measured by the IOLMaster® (Carl Zeiss Meditec Inc., Germany), was 25.52 mm OD and 23.14 mm OS. The anterior chamber depth (ACD) was 3.43 mm OD and 3.60 mm OS. The patient's stereoacuity was 200 arcsec by the Titmus test. Both the anterior and posterior chambers appeared normal on slit-lamp biomicroscopy and indirect ophthalmoscopy. There was no ocular suppression in the near vision, but the right eye showed suppression in the distance vision by the Balgolini test. The patient was found alternative exophoria by cover and un-cover test at the distance of 1 meter, and the right eyeball was found higher than the left eyeball by red reflex examination (Figure 1). The prismatic PAL prescribed for this patient were 7.00D /-1.25D × 175°, 2 (prism diopter) × 270° (Base

down) OD, and plano (pl)/-2.00D × 180°, 3×90° (Base up) OS. The addition lens power was +1.50 D.

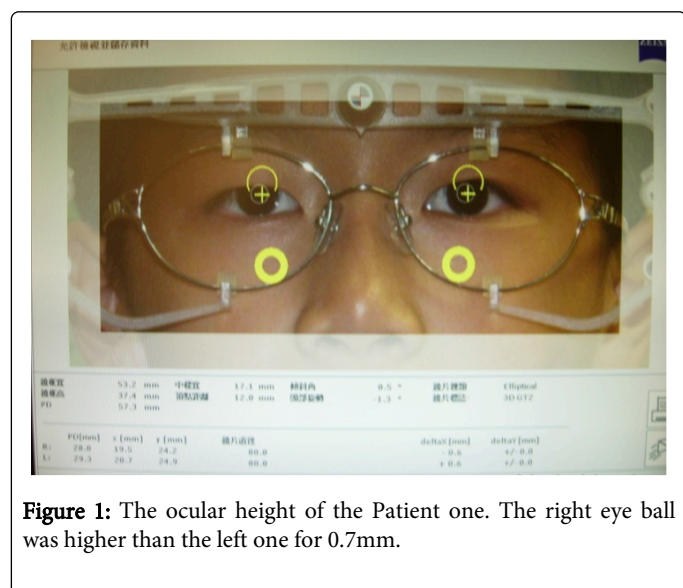


Figure 1: The ocular height of the Patient one. The right eye ball was higher than the left one for 0.7mm.

Three months after consultation, the patient was found in a marked improvement in the outdoor activities (such as table tennis, and roller skating). In January 2015, the best visual acuity of both eyes was 20/20 with the manifested refractions -7.25D/-1.25D × 175°, 2× 270° OD, and plano/-2.00 D × 180°, 3× 90° OS. The stereoacuity was 60 arcsec. The axial lengths were 25.87 mm OD and 23.52 mmOS.

Case 2

A 5-year-old male patient, diagnosed with refractive anisometropia at age 3, presented to our clinic with myopia progression in the right eye (-5.00 D in 2 years). No other ocular diseases were present in either eye. There was no essential birth abnormality or congenital diseases. The BBWt was 3450 gm with gestational age of 39 weeks. The VA was 20/400 OD and 20/30 OS. The CDVA was 20/30 OD (refraction of -5.75D/-1.25D × 140°) and 20/20 OS (+0.75D/-1.00 D × 170°). The IOP was 16 mmHg OD and 19 mmHg OS. The ALs were 23.12 mm OD and 22.17 mm OS. The ACDs were 2.68 mm OD and 2.98 mm OS. The initial ocular examination showed exotropia and right hypertropia. The Hess chart examination was consistent with ocular alignment (Figure2). Prismatic PALs were -5.50 D/-1.5D × 140°, 4Δ × 0° OD and plano/-1.50 D × 180°, 3Δ× 180°OS. The addition lens power was +1.50 D. The distances from pupil to midline were 27.8mm OD and 27.3 mm OS.

Four and half years later, the CDVA was 20/25 (-5.75D/-1.50 D × 180°) OD and 20/20 (plano/-1.50 D × 180°) OS. The ALs were 23.37 mm OD and 22.31 mm OS. Additionally, the stereoacuity improved from fly negative to fly positive by the Titmus test.

Comment

Dr. Hans-Joachim Haase developed a systematic set of test for evaluating binocular vision call the Pola Test. The Pola Test measures associated phoria and stereoacuity at distance and near using a variety of different targets of each. This testing method and interpretation is referred to as MKH-Haase (Measuring and Correcting Methodology after H.J. Haase- the MKH) method. The MKH method is more

commonly used in Germany and other European countries than English speaking countries. The MKH-Haase method has been considered a reliable method for prescribing prisms to symptomatic binocular vision patients. The test consisted of five subtests: horizontal associated phoria, vertical associated phoria, rotational phoria, aniseikonia, and stereopsis. The Pola test used polarized objects for dichoptic presentation. In addition to the dichoptic targets, there are either peripheral or central fusion locks, which are not polarized.

One of the first attempts to describe binocular single vision was presented by Worth. Worth classified binocular single vision into three degrees. The first degree was Simultaneous Perception, which is the perception of the two images of an object of regard from both eyes at the same time. The second degree was Fusion, which is combining the two images into one image. Fusion was sub-categorized into sensory fusion and motor fusion. Sensory fusion was the ability of fusing the two images into one. Motor fusion was the ability to maintain the fused image through a specified range of vergence. The third degree was Stereoscopic Vision, which was the ability to perceive fine depth from retinal disparities. Based on the above definition, a person will have normal binocular vision if the image of an object of regard falls exactly on both foveae and both foveae are assigned the same visual direction. In this situation, the tow foveae are related or corresponding. However, abnormal binocular vision will occur when the fovea of one eye corresponds with another retinal point of the other eye. That is, abnormal retinal correspondence occurs when the fovea of each eye has different visual directions or the visual direction of the fovea of one eye is the same visual direction as an extra-foveal point in the other eye.

The Brückner test, on the MTI photoscreener (Medical technologies, Inc., USA), provided a high positive predictive value (96%) for the diagnosis of anisometropia [4,5]. Assessing eyeball position symmetry and ocular alignment are still valuable tools in helping ophthalmologists diagnose anisometropia. Combining this observation method with the Brückner test, eyeball position symmetry and pupillary reflex assessment, anisometropia was successfully identified. Weiss [6] showed that unilateral high myopia should be diagnosed using axial length measurements, clinical findings and relevant patient history. In the two cases presented here, emmetropization occurred from by rule out other ocular deformities, such as buphthalmos, optic nerve hypoplasia, macular coloboma and corneal or lens opacities. Sorsby et al. [7] inferred that increased axial length was the major cause of anisometropic myopia. In the two cases presented here, the axial length was compatible with refractive results.

Anisometropia is a condition that occurs when an interocular refractive difference results in disparate images on the two foveae. The eye that receives the blurred image could suffer visual loss, even after fully correcting for refractive error [8,9]. Following the guidelines of the Internationale Vereinigung für Binokulare Vollkorrektur (IVBV), any associated phoria was corrected with both monocular (spherical and cylinder correction) and binocular vision (prism correction). In our two cases, the small amount of prism helped patients focus more easily and resulted in less muscle strain. With proper binocular vision, patients also demonstrated improved performance in outdoor activities.

The degree of myopia and axial length stabilized after 4 years of therapy with prismatic progressive addition lens in these two cases. Further study with more case number and longer duration of follow-up might be helpful for the effectiveness of prismatic progressive addition lens for anisometropia.

Source of Support

This work was supported by grant FCRPF6A0011 from the Chang Gung Memorial Hospital in Taiwan.

References

1. Huynh SC, Wang XY, Ip J, Robaei D, Kifley A, et al. (2006) Prevalence and associations of anisometropia and aniso-astigmatism in a population based sample of 6 year old children. *Br J Ophthalmol* 90: 597-601.
2. Cotter SA; Pediatric Eye Disease Investigator Group, Edwards AR, Wallace DK, Beck RW, et al. (2006) Treatment of anisometropic amblyopia in children with refractive correction. *Ophthalmology* 113: 895-903.
3. Haase HJ Guidelines for the Correction of Associated Phoria (3rd edn.) Internationale Vereinigung für Binokulare Vollkorrektur IVBV.
4. <http://EyeRounds.org/cases/134-anisometropic-amblyopia.htm>
5. Longmuir SQ, Pfeifer W, Leon A, Olson RJ, Short L, et al. (2010) Nine-year results of a volunteer lay network photoscreening program of 147 809 children using a photoscreener in Iowa. *Ophthalmology* 117: 1869-1875.
6. Weiss AH (2003) Unilateral high myopia: optical components, associated factors, and visual outcomes. *Br J Ophthalmol* 87: 1025-1031.
7. Sorsby A, Leary GA, Richards MJ (1962) The optical components in anisometropia. *Vis Res* 2: 43-51.
8. Chen PL, Chen JT, Tai MC, Fu JJ, Chang CC, et al. (2007) Anisometropic amblyopia treated with spectacle correction alone: possible factors predicting success and time to start patching. *Am J Ophthalmol* 143: 54-60.
9. Kutschke PJ, Scott WE, Keech RV (1991) Anisometropic amblyopia. *Ophthalmology* 98: 258-263.