

Successful Pregnancy Outcome in a Woman with Prior Temporal Lobe Surgery for Intractable Epilepsy

Gowri Dorairajan* and Himabindu N

Department of Obstetrics and Gynecology, JIPMER, Puducherry, India

*Corresponding author: Dr. Gowri Dorairajan, Professor, Department of Obstetrics and Gynecology, JIPMER, Puducherry, India, Tel: +914132298041; E-mail: gowridorai@hotmail.com

Received date: October 15, 2016; Accepted date: November 22, 2016; Published date: November 24, 2016

Copyright: © 2016 Dorairajan G et al. This is an open-access article distributed under the terms of the Creative Commons Attribution License, which permits unrestricted use, distribution, and reproduction in any medium, provided the original author and source are credited.

Abstract

Temporal lobectomy as a treatment of intractable epilepsy is well established though rare. There is lack of literature on detailed management of pregnancy after temporal lobe surgery for epilepsy. We report one such woman who had undergone right temporal lobectomy and unco-amygdalo-hippocampectomy ten years back. The woman presented even before conception. The management during pregnancy is detailed. The course during labour is detailed. Mono therapy with newer anti-epileptics, strict surveillance during pregnancy and labour as per the guidelines can result in successful pregnancy outcome in woman with epilepsy who have undergone temporal lobe operation.

Keywords: Temporal lobectomy; Anti-epileptic agents; Pregnancy; Amygdalo hippocampal epilepsy; Epilepsy

Introduction

Intractable epilepsy requiring surgery is rare but well-established. There is lack of detailed reports of outcome and management of pregnancy in these women who have undergone temporal surgery for epilepsy earlier. We report one such case of pregnancy after right temporal lobectomy and unco-amygdalo-hippocampectomy ten years back for intractable temporal focus epilepsy. The details of the case bring out the supervision and management strategies for successful outcome.

Case History

A 35-year-old woman came for a checkup. She was married for six years and had not conceived yet. She had regular menstrual cycles.

Her past medical history revealed that she had undergone unco-amygdalo-hippocampectomy for temporal lobe epilepsy. Her last convulsion was five years back.

She was a known epileptic since she was seven years old. Seizures were left focal type, lasting for 8-10 minutes followed by generalization with the loss of consciousness and irrelevant speech. It was preceded by an aura. She had studied till 10th class and discontinued due to forgetfulness and poor scholastic performance. Her records revealed that despite antiepileptic treatment she had frequent attacks of 2-3 per week. The MRI brain had confirmed a hypointense lesion in the T1 weighted, and a hyperintense lesion in the T2 weighted scan and flair images in the region of the right temporal lobe, Ammon's horn and unco- hippocampal area. Nuclear brain spectral had shown increased traces concentration in the left temporal region with reduced traces concentration in the right temporal region and the left posterior parietal region. Electroencephalogram revealed the presence of a temporal predominance with frequent bursts of slow waves at times interspersed with sharp discharges bilaterally and synchronously

accentuated by hyperventilation in frontal and temporal region. Neuropsychological report revealed high anxiety, hypersensitivity, emotional lability and poor stress tolerance. The serum Gamma Glutamyl Trans Peptidase level was 42 units (within normal limits).

Since the epilepsy was intractable despite the medical treatment and as all the investigations had pointed towards temporal lobe focus, right temporal lobectomy and unco-amygdalo-hippocampectomy were carried out at the age of 24 years (in the year 2000). Histopathology had confirmed a subpial gliosis with focal anoxic change and evidence of neuronal migration disorder. She was continued carbamazepine as the post operative EEG showed potentially epileptiform dysfunction. The serum carbamazepine level was maintained around 12 micrograms/ml. She had occasional seizures after the surgery. Repeat MRI done in 2002 confirmed right temporal lobectomy status with gliotic changes of the residual temporal lobe (Figure 1).

Her mother had diabetes for the last five years. There was no other contributory history in the family. Her younger sister and brother were normal. She was born to her mother by normal vaginal delivery without any antenatal complications in her mother.

On examination, she was thinly built with a body mass index of 18. The general physical, systemic and gynecological examinations did not reveal any abnormality. We started her on 5 mg folic acid tablets daily and investigated. The serum prolactin and thyroid function was normal. We started her on insulin sensitizer metformin 250 mg twice daily for a month. The woman conceived in the next cycle and pregnancy was confirmed at five weeks.

In consultation with the neurosurgeon and the treating physician carbamazepine was converted to levetiracetam after confirmation of pregnancy. The screening for Down syndrome with nuchal thickness and later the triple screen was negative. Targeted fetal morphology scan at 18 weeks and 24 weeks' period of gestation confirmed a normal morphology of the fetus.

There was no complication. She was prescribed folic acid throughout pregnancy. The total weight gain was 10 kilograms. There

was no episode of convulsion. Her blood group was O⁺; glucose tolerance test was normal. Infection screen for syphilis, hepatitis B, and HIV was negative. She was not anemic.

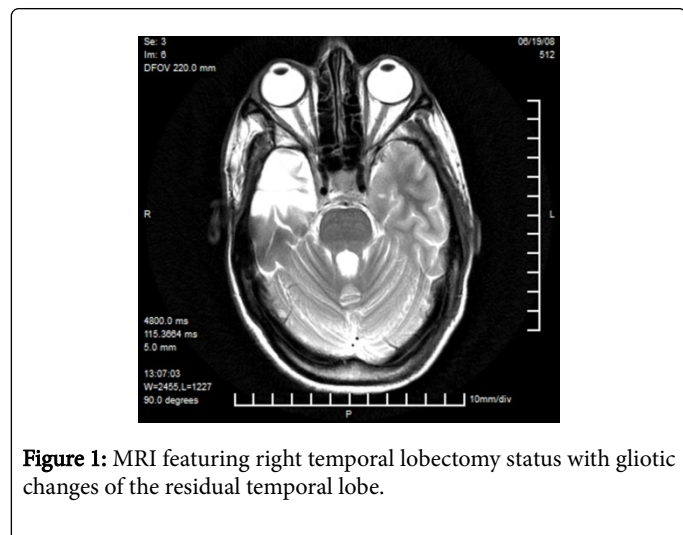


Figure 1: MRI featuring right temporal lobectomy status with gliotic changes of the residual temporal lobe.

Vitamin K injection was given at term. She had spontaneous labor at 37 completed weeks. The labor progress was satisfactory with the partograph to the left of the alert line. She was administered the anti-epileptics as scheduled. She was kept well sedated. Her blood pressure remained normal. The labor lasted for 8 hours. There was no convulsion during labor. In view of the previous brain surgery, prophylactic forceps were applied to minimize the duration of and straining at the second stage. A 3-kg female baby with good Apgar score was delivered.

Discussion

Sexual dysfunction and infertility have been reported in women who have epilepsy. Studies have shown altered LH and FSH ratio and increased androgen levels in women with epilepsy and on anti-epileptics [1].

Pregnancy can precipitate attacks of generalized seizures in about 15% to 32% of cases. The women with focal seizures are more likely to have exacerbations than the ones with generalized seizures. Pregnancy changes the pharmacokinetics of the anti-epileptics by altering the drug distribution and clearance [2]. The increase in seizure frequency can also be due to changes in the estrogen and progesterone levels that can affect the neurons [3].

In a recently published observational study [4], the authors reported that the temporal lobe surgery improves the birth rate in women with intractable focal epilepsy and their results support surgical management early in the management for women with intractable temporal lobe focal epilepsy. However, the management of pregnancy in woman with previous temporal lobe surgery has not been detailed in literature. The case reported brings out that pregnancy should be carefully supervised. The recommended guidelines [5] should be strictly followed right from preconception to throughout pregnancy for the best outcome, as was done in our case. The anti-epileptic drug

should be switched over to the third-generation ones if possible and specially if seen in the first trimester. Monotherapy is preferred.

Carbamazepine and Valproic acid are category D drugs whereas levetiracetam is category C drug. Studies have shown the risk of malformation to be increased by five times and two times with valproic acid and carbamazepine respectively [6] Carbamazepine specifically causes spina bifida and in addition to spina bifida, valproic acid can cause atrial septal defect, cleft palate, hypospadias, polydactyly etc. [7,8]. The incidence of malformation has been observed to be lesser with the newer antiepileptic drugs compared to the conventional anti-epileptics [9].

Epilepsy in pregnancy is associated with increased risk of severe pre-eclampsia, bleeding in early pregnancy, induction, caesarean section and preterm birth [10]. In view of the previous temporal lobe surgery, we used outlet forceps to cut short second stage of labor to prevent the rise in pressure and to prevent seizure.

Temporal lobectomy and unco-amygdalo-hippocampectomy for temporal lobe epilepsy is rare but well-established. Our patient underwent surgery nearly ten years back Pregnancy in women who have undergone temporal lobectomy can result in successful outcome by close supervision and guidelines' based management. Monotherapy with third generation anti-epileptics will reduce the risk of malformations. Normal delivery can be anticipated and is possible in them without adversely affecting the maternal outcome.

References

1. Thomas SV, Sarma PS, Nirmala C, Mathai A, Thomas SE, et al. (2013) Women with Epilepsy and Infertility Have Different Reproductive Hormone Profile than Others. *Ann Indian Acad Neurol* 4: 544-548.
2. Battino D, Tomson T, Bonizzoni E, Craig J, Lindhout D, et al. (2013) Seizure control and treatment changes in pregnancy: observations from the EURAP epilepsy pregnancy registry. *Epilepsia* 54: 1621-1627.
3. Borgelt LM, Hart FM, Bainbridge JL (2016) Epilepsy during pregnancy: focus on management strategies. *Int J Womens Health* 8: 505-517.
4. Fabris RR, Cascino TG, Mandrekar J, Marsh WR, Meyer FB, et al. (2016) Drug-resistant focal epilepsy in women of childbearing age: Reproduction and the effect of epilepsy surgery. *Epilepsy Behav* 60: 17-20.
5. Krishnamurthy KB (2012) Managing Epilepsy During Pregnancy: Assessing Risk and Optimizing Care. *Curr Treat Options Neurol* 14: 348-355.
6. Vajda FJ, O'Brien TJ, Graham J, Lander CM, Eadie MJ (2015) Is carbamazepine a human teratogen? *J Clin Neurosci* 23: 34-37.
7. Jentink J, Dolk H, Loane MA, Morris JK, Wellesley D, et al. (2010) Intrauterine exposure to carbamazepine and specific congenital malformations: systematic review and case-control study. *BMJ* 341: c6581.
8. Jentink J, Loane MA, Dolk H, Barisic I, Garne E, et al. (2010) Valproic acid monotherapy in pregnancy and major congenital malformations. *N Engl J Med* 362: 2185-2193.
9. Mawhinney E, Craig J, Morrow J, Russell A, Smithson WH, et al. (2013) Levetiracetam in pregnancy: results from the UK and Ireland epilepsy and pregnancy registers. *Neurology* 80: 400-405.
10. Ahmed R, Apen K, Endean C (2014) Epilepsy in pregnancy - a collaborative team effort of obstetricians, neurologists and primary care physicians for a successful outcome. *Aust Fam Physician* 43: 112-116.