

Streptococcus viridans Pelvic Osteomyelitis after Dental Procedures in an Adolescent Male: A Case Report Illustrating the Importance of Dental History

Rachael Hayden* and Toni Sanchez DO

Department of Pediatrics, Oklahoma State University, USA

*Corresponding author: Rachael Hayden, Department of Pediatrics, Oklahoma State University, College of Osteopathic Medicine, 1111 W 17th St. Tulsa, OK 74107, USA, Tel: +1-916-207-7828; E-mail: rachael.hayden@okstate.edu

Rec date: Aug 23, 2014, Acc date: Sep 23, 2014, Pub date: Sep 25, 2014

Copyright: © 2014 Hayden R, et al. This is an open-access article distributed under the terms of the Creative Commons Attribution License, which permits unrestricted use, distribution, and reproduction in any medium, provided the original author and source are credited.

Abstract

Pelvic osteomyelitis is a rare entity with a highly variable clinical presentation. Patients usually present with hip or groin pain, difficulty walking, and sometimes fever. In children, it can mimic septic arthritis of the hip, an acute abdomen, and an inguinal hernia, making it a diagnostic challenge for many physicians. Predisposing risk factors include immunodeficiency, intravenous drug abuse, pelvic or urologic surgery, and young age. A more unfamiliar predisposing factor is strenuous physical activity in athletes, suggesting the presence of osseous microtrauma occurring in the setting of excessive stress to the pelvis during exercise. Although the most common pathogen in osteomyelitis is *Staphylococcus aureus*, other bacterial causes should be suspected based on the patient's immune status and medical, dental and social history. This case highlights an unusual presentation of *Streptococcus viridans* osteomyelitis of the acetabulum in an otherwise healthy 13-year-old athletic male. The patient had undergone significant dental work prior to his symptom onset, which likely resulted in transient bacteremia and subsequent hematogenous seeding in areas of osseous microtrauma. Although exceedingly rare, *Streptococcus viridans* osteomyelitis has previously been reported in association with dental procedures. Osteomyelitis of the pelvis is an uncommon yet debilitating disease that should be included in the differential diagnosis of young athletes presenting with unexplained sudden onset hip or groin pain, atypical gait, painful range of motion of the hip, and fever. The novel bacterial etiology presented in this case should call attention to the association between dental procedures and *Streptococcus viridans* osteomyelitis. Dental history is commonly overlooked during many hospital medical evaluations, and we believe this case report should highlight the importance of obtaining a basic dental history, especially in patients presenting with signs and symptoms of pelvic osteomyelitis.

Keywords: *Streptococcus viridans* osteomyelitis; Pelvic osteomyelitis; Dental complications; Hip pain in young athletes; C-Reactive Protein versus ESR to monitor osteomyelitis

Introduction

Pelvic osteomyelitis is a rare entity with a highly variable clinical presentation. Patients usually present with hip or groin pain, difficulty walking, and sometimes fever. In children, it can mimic septic arthritis of the hip, an acute abdomen, and an inguinal hernia, making it a diagnostic challenge for many physicians [1]. Predisposing risk factors include immunodeficiency, intravenous drug abuse, pelvic or urologic surgery, and young age [2]. A more unfamiliar predisposing factor is strenuous physical activity in athletes, suggesting the presence of osseous microtrauma occurring in the setting of excessive stress to the pelvis during exercise [3-5].

Osteomyelitis is an infection of the bone that leads to serious tissue destruction and often to debility [6]. Osteomyelitis can be acute or chronic, hematogenous or contiguous, and can be caused by a multitude of organisms depending on predisposing factors including history of recent injury, physiologic status of the host, prosthetic joint implants, recent genitourinary surgery, and the presence of underlying chronic illnesses such as diabetes or sickle cell anemia. The most common organism responsible for osteomyelitis is *Staphylococcus aureus*, with the metaphysis of long bones being the most common site of infection [7]. However, there are unusual organisms that should be suspected in certain patient situations; for example, *Salmonella*

paratyphi osteomyelitis is more prevalent in patients with sickle cell disease, while *Bartonella henselae* is associated with cat scratches, and osteomyelitis caused by coagulase-negative staphylococci is more frequently found in patients with prosthetic joint implants.

In an effort to highlight another possible osteomyelitis etiology association, we describe a novel case of isolated *Streptococcus viridans* osteomyelitis of the acetabulum in an otherwise healthy adolescent male following extensive dental treatment. The viridans streptococci are a group of alpha-hemolytic Gram-positive cocci, which are a part of the normal oral flora and are important agents involved in dental caries and subacute bacterial endocarditis [6]. *Streptococcus viridans* is an unusual causative organism of osteomyelitis, but other documented cases of hematogenous osteomyelitis following dental procedures may alert physicians to begin more seriously considering this association [3,8,9]. To our knowledge, this is the first reported case of hematogenous acetabular osteomyelitis secondary to *streptococcus viridans* in a previously healthy child.

Case Presentation

A 13-year-old active, previously healthy male presented to the Children's Hospital from his primary care physician's office with worsening left hip pain and new onset fever. The hip pain began 3 weeks prior at basketball practice, during which he did not recall any significant falls or trauma to the hip. Since that time, the pain has been persistent, with a 3/10 severity, but sometimes getting so severe as to cause nocturnal awakenings. The patient further described the pain as

“constant and achy,” occurring deep in his left hip and radiating inward toward his groin. He reported some associated intermittent tingling of the left anterior medial thigh. The pain was worse at night, while standing, and with extension of the hip. The patient stated the pain was somewhat alleviated with ibuprofen and was better with his hip held in a flexed and externally rotated position. Associated symptoms included a 3-day history of nausea, sore throat, and decreased oral intake.

The patient was first examined by his pediatrician approximately 1 week prior to his hospital admission, at which time he was diagnosed with transient synovitis of the hip and started on ibuprofen. Approximately 24 hour prior to hospital admission, the patient spiked a fever of 38.3° Celsius, which prompted a return visit to his primary care physician. Initial labs were drawn at that visit: white blood cell count was 16, erythrocyte sedimentation rate was 50, C-reactive protein and ANA were normal. The patient was then transferred to the Children’s Hospital for concern and workup of a septic joint.

On examination, the patient was a slender, physically-fit young Caucasian male who appeared slightly pale, and was seated in a wheelchair with his left hip held in a flexed position. On initial assessment in the hospital, he was afebrile with a temperature of 37.6° Celsius, blood pressure 112/57 mmHg, respirations at 16 breaths per minute, and a pulse of 100 beats per minute. On musculoskeletal evaluation, an abnormal gait with left-sided limp was noted. Significant pain with range of motion was noted, specifically with extension and internal rotation of the left hip. Strength and motor examination was limited due to the patient’s severe pain and discomfort. On evaluation of his hip and lower extremities, there was no evidence of penetrating trauma or overlying erythema or induration. There was moderate tenderness with deep palpation of the left hip. Tenderness was elicited with palpation of the left lower quadrant and left anterior groin. Active bowel sounds were noted in all four quadrants, with no rebound tenderness or involuntary guarding. The patient had normal male external genitalia with bilaterally descended testes, and no palpable inguinal hernias. Respiratory examination was unremarkable, and there were no murmurs noted on cardiac auscultation. The patient was noted to have poor dentition, geographic tongue, and mild erythema of the posterior pharynx.

The patient’s history was fairly noncontributory; the patient was an uncomplicated term vaginal delivery, who has since developed appropriately, and has no remarkable past medical or surgical history. During his hospitalization, the patient’s mother revealed a significant dental history that included multiple dental procedures within the last year due to a non-healing broken tooth with associated periodontal abscess.

On admission to the hospital, blood cultures and routine labs were drawn: white blood cell count 11000/mm³ (normal level= 4600 - 12400/mm³) with 72% polymorphonuclear cells (normal level= 39.2 -73.9%) and no bands, ESR of 96 mm/h (normal level= 0-17), and C-reactive protein of 19.27 mg/dL (normal level= 0-0.80 mg/dL). The patient was started on IV fluids and empiric antibiotic therapy including intravenous vancomycin and rifampin. A left hip ultrasound revealed a complex echogenicity in the inguinal region of uncertain significance, and was followed up with a CT of the abdomen and pelvis which suggested osteomyelitis of the left acetabulum with 1 or 2 foci of bony sequestrum and a large periosteal/soft tissue abscess ventral to the left hip anterior column extending to the left iliacus musculature. On day 2, the patient was seen and examined by pediatric orthopedic surgery, and immediately taken to the operating room for an open

arthrotomy with irrigation and debridement of the left hip and pelvic abscess, with subsequent drain placement. Osteomyelitis of the left acetabulum was noted along with a large intrapelvic abscess located deep to the left iliacus muscle. On day 6, the patient underwent a repeat surgical evaluation with incision and irrigation of the left hip, where no additional abscesses were noted. The drain was removed at this time.

The blood cultures on admission continued to show no growth, but the purulent material cultures obtained during surgery grew a moderate amount of alpha hemolytic Gram-positive cocci that were identified on day 5 as *Streptococcus viridans*. Sensitivity results showed that the organism was sensitive to penicillin, vancomycin, cefotaxime, chloramphenicol, erythromycin and clindamycin. At this time, vancomycin was discontinued and the patient was continued on intravenous rifampin with ampicillin. Despite intermittent pyrexia occurring from the night of admission until day 8 (body temperature spiking to 38.8° Celsius), the patient gradually improved on antibiotics. He reported significantly decreased pain, began ambulating, and ceased to have febrile episodes after day 8. Serial CRP and ESR levels were followed, with the CRP level seeming to better correlate with his clinical presentation (CRP came down to 7.76 mg/dL from a maximum value of 34.54 mg/dL on day 3 after the first surgical debridement, where the ESR was 111 mm/h upon discharge on day 12, after fluctuating from 96 mm/h on initial presentation to 1 mm/h on day 7). After being afebrile for over 48 hours, the patient was discharged on day 12 with a 6-week course of oral rifampin and intravenous ampicillin given through his peripherally inserted central catheter. He was closely followed up outpatient by his pediatrician and the pediatric orthopedic surgeon and showed complete clinical recovery.

Discussion

The viridans streptococci have often been associated with dental caries and endocarditis, but this report illustrates the potential for this minimally virulent bacteria to cause osteomyelitis in an immunocompetent host. While *streptococcus viridans* is considered a rare cause of osteomyelitis, most reported cases arose from a contiguous anatomical site, occurring subsequent to oral surgery, periodontal infections or local penetrating trauma [10]. There are only a handful of documented cases illustrating hematogenous *Streptococcus viridans* osteomyelitis, the majority of which occurred in the setting of a recent major or minor dental procedure. Of the suspected hematogenous cases of *Streptococcus viridans* osteomyelitis, we found two cases of vertebral osteomyelitis [8,4], two cases of femoral osteomyelitis [9,11], and one case of pubic osteomyelitis [3].

Acute hematogenous osteomyelitis (AHOM) of the pelvis is an uncommon presentation of pediatric osteomyelitis that can be a diagnostic challenge owing to its nonspecific and highly variable clinical presentation. In a review of 179 cases of pediatric pelvic osteomyelitis, the majority of patients presented with pain localized to the hip/inguinal region (46%), thigh (22%), or abdomen (18%) [12]. In a study series investigating the specific clinical presentations of 19 pediatric patients with pelvic osteomyelitis, all presented with an obvious limp and restricted hip mobility, 89% had elevated CRP levels, 63% were febrile, and only 32% had a white blood cell count greater than 12/mm³ [12]. Another issue is that children with pelvic AHOM may present similarly to those with a septic hip (history of fever, non-weight bearing, elevated ESR, and WBC greater than 12/mm³), often warranting a hip ultrasound to assess for septic arthritis [13].

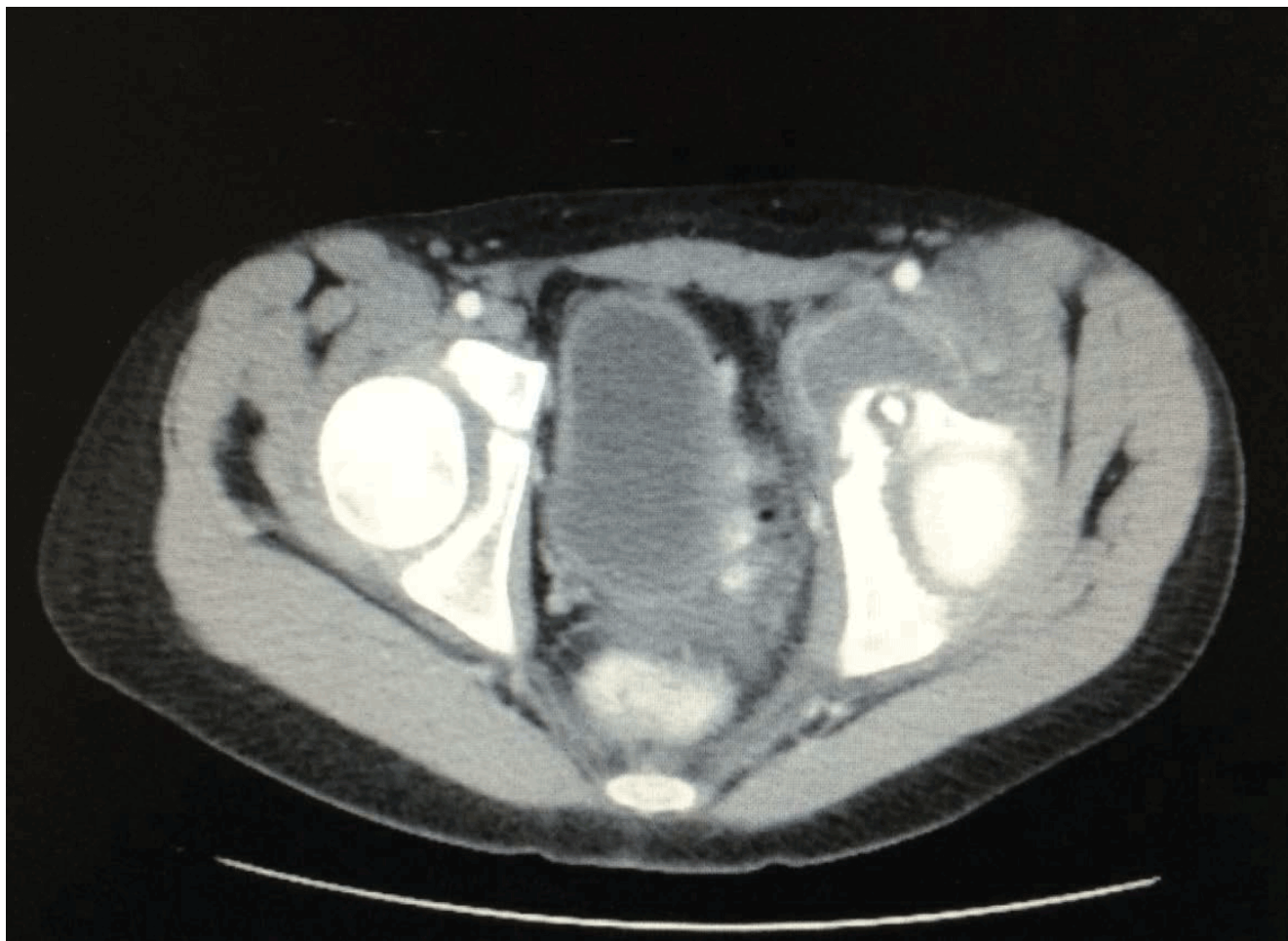


Figure 1: CT of the pelvis showing osteomyelitis of the left acetabulum with foci of bony sequestrum and a large periosteal/soft tissue abscess ventral to the left hip anterior column extending to the left iliac musculature.

However, as seen in our case, ultrasonography in patients with pelvic AHOM will likely fail to show a significant hip effusion, essentially resulting in further imaging and further delay in diagnosis.

The diagnosis of acute pelvic osteomyelitis based on the diagnostic criteria of acute hematogenous osteomyelitis (AHOM) in general is established by the presence of two or more of the following: 1) local signs of inflammation, 2) positive culture results from blood or needle aspiration of bone, 3) subperiosteal purulent transudate aspirated from bone, and 4) typical radiographic changes or positive isotope bone scan [14]. The diagnosis of AHOM in our patient was based on the presence of bone transudate, positive bone aspirate cultures, and radiographic changes. While our case did not have positive blood cultures, the lack of any local penetrating trauma or antecedent soft tissue infection, combined with the presence of an obvious infection source in the mouth suggests osteomyelitis due to hematogenous seeding. The multiple recent dental procedures most likely served as a port of entry and predisposed our patient to transient bacteremia.

Even in the setting of transient bacteremia, what would cause an immunocompetent child to become susceptible to developing such a severe case of pelvic osteomyelitis? According to Harrison's Principles

of Internal Medicine, the most common predisposing factor for the development of osteomyelitis is an area of bone or contiguous surrounding tissue that is abnormal in terms of viability, blood supply, sensation, or edema [6]. It has been previously reported that athletes who participate in strenuous physical activity, much like our patient, are at increased risk of pelvic osteomyelitis [4]; the pathogenesis of this disease is thought to involve exercise-related osseous microtrauma with subsequent seeding of this area during transient bacteremia [15]. Among athletes, the pediatric population is even more at risk for hematogenous osteomyelitis due to the presence of physes, which are inherently predisposed to infection secondary to bacterial seeding because of the sluggish blood flow of the metaphyseal and transphyseal vessels, low PO₂, and reticuloendothelial deficiency [16].

Correctly diagnosing osteomyelitis early in its clinical course is crucial to minimizing disability, loss of function, treatment cost and mortality. A plain radiograph is usually performed during the initial workup of osteomyelitis, and although it may be useful for excluding other causes of hip pain such as a tumor or fracture, it is not a sensitive diagnostic tool. The hallmark findings of osteomyelitis on x-ray (bone loss, sequestra, periosteal elevation or swelling) may not be apparent for several weeks or more [6]. Computed tomography (CT) is more

sensitive than plain radiography and may be useful in detecting soft tissue swelling and abscess formation. Magnetic resonance imaging (MRI) is the most sensitive imaging technique for early detection of pelvic osteomyelitis, but the high cost and need for sedation in children younger than 4 to 5 years precludes wide application of this modality in the diagnosis of acute hematogenous osteomyelitis [17,12]. In one retrospective study, 19 of 20 children with pelvic osteomyelitis had diagnostic findings of osteomyelitis by MRI; plain radiographs were diagnostic in only one child [18]. In a review of 146 reported cases of pelvic osteomyelitis, it was suggested that technetium bone scan may actually be the most practical imaging procedure, with regards to cost and sensitivity, for the diagnosis of pelvic AHOM [17]. The classic laboratory tests for diagnosing and for monitoring recovery from AHOM are the erythrocyte sedimentation rate (ESR) and the white blood cell (WBC) count, but recent studies suggest that

serum C-reactive protein (CRP) may be of greater value for monitoring AHOM, especially in the pediatric population [19]. In our particular case, the WBC count was within normal limits upon admission, while the CRP and ESR were markedly elevated. When comparing the significance of the CRP and ESR values, the CRP level appeared to better correlated with the patient's clinical presentation (Table 1). In a prospective study of 44 children with AHOM, the CRP was elevated at the time of admission in 98% of cases, while the ESR was elevated in 92% of cases. Furthermore, it was concluded that the CRP increased and especially decreased significantly faster than ESR, reflecting the effectiveness of the therapy given and predicting recovery more sensitively than ESR or WBC count [19]. As suggested in previous studies [19-21], our case further illustrates that CRP may be a superior indicator of treatment response in pediatric patients with osteomyelitis when compared to WBC count and ESR.

Time (day)	WBC (K/cmm)	ESR (mm/h)	CRP (mg/dL)	Notes
0*	11.0	96	19.27	
2	-	70	24.54	Surgical debridement #1
3	12.1	93	34.54	
4	10.0	85	27.46	
5	-	-	-	Surgical debridement #2
6	-	1	17.47	
7	14.8	107	15.45	
9	-	>140	10.97	
10	-	113	8.77	
11	-	111	7.76	

*day 0 is the day of admission

Table 1: Values of Serum C-Reactive Protein (CRP), Erythrocyte Sedimentation Rate (ESR), and White Blood Cell (WBC) Count taken during the course of our patient's hospitalization.

Conclusion

Although rare, pelvic osteomyelitis should be suspected in young athletes with unexplained sudden onset pelvic or groin pain and painful range of motion of the hip. Transient bacteremia with subsequent bacterial seeding in the setting of pre-existing osseous microtrauma of the pelvis due to rigorous exercise may explain the pathogenesis of pelvic osteomyelitis in an otherwise healthy athlete. Prompt diagnosis of pelvic osteomyelitis is imperative, as a delay in treatment may result in long-term morbidity. A high index of suspicion depends on thorough history taking, a detailed physical examination, and proper imaging techniques and blood tests. As suggested in previous studies, this case further demonstrates that the CRP may be a better indicator of treatment response in acute pediatric osteomyelitis when compared to the laboratory tests traditionally used for this condition-ESR and WBC count. Furthermore, the novel bacterial etiology presented in this case should call attention to the rare, but important association between dental procedures and *Streptococcus viridans* osteomyelitis. Dental history is commonly overlooked during many hospital medical evaluations, but we hope this case report alerts physicians to the significance of obtaining a basic

dental history, especially in patients presenting with signs and symptoms of pelvic osteomyelitis.

References

1. Takemoto RC, Strongwater AM (2009) Pelvic osteomyelitis mimicking septic hip arthritis: a case report. *J Pediatr Orthop B* 18: 248-251.
2. Edwards MS, Baker CJ, Granberry WM, Barrett FF (1978) Pelvic osteomyelitis in children. *Pediatrics* 61: 62-67.
3. Naqvi N, Naqvi R, Wong C, Pearce S (2008) A novel observation of pubic osteomyelitis due to *Streptococcus viridans* after dental extraction: a case report. *J Med Case Rep* 2: 255.
4. Meirovitz A, Gotsman I, Lilling M, Bogot NR, Fridlender Z, et al. (2004) Osteomyelitis of the pubis after strenuous exercise. A case report and review of the literature. *J Bone Joint Surg Am* 86-86A: 1057-60.
5. Karpos PA, Spindler KP, Pierce MA, Shull HJ Jr (1995) Osteomyelitis of the pubic symphysis in athletes: a case report and literature review. *Med Sci Sports Exerc* 27: 473-479.
6. Kasper DL, Harrison TR (2012) Osteomyelitis: Harrison's Principles of Internal Medicine. New York: McGraw-Hill, Medical Pub. Division 1: 18.
7. Goljan, Edward F (2011) Rapid Review Pathology. Elsevier.

8. Choudhury M, Patel BR, Patel M, Bashir T (2009) *Streptococcus viridans* osteomyelitis and endocarditis following dental treatment: a case report. *Cases J* 2: 6857.
9. Kim SH, Park MS, Song SH, Lee HJ, Choi EH (2010) Hematogenous osteomyelitis caused by *Streptococcus anginosus* group in a previously healthy child. *Pediatr Int* 52: e209-211.
10. Griffin AT, Timbrook T, Harting J, Christensen D (2013) *Streptococcus anginosus* group and osteomyelitis: a single centre clinical experience. *Postgrad Med J* 89: 262-265.
11. Ribner BS, Freimer EH (1982) Osteomyelitis caused by viridans streptococci. *Arch Intern Med* 142: 1739.
12. Weber-Chrysochoou C, Corti N, Goetschel P, Altermatt S, Huisman TA, et al. (2007) Pelvic osteomyelitis: a diagnostic challenge in children. *J Pediatr Surg* 42: 553-557.
13. Kocher MS, Mandiga R, Murphy JM, Goldmann D, Harper M, et al. (2003) A clinical practice guideline for treatment of septic arthritis in children: efficacy in improving process of care and effect on outcome of septic arthritis of the hip. *J Bone Joint Surg Am* 85-85A: 994-9.
14. Gold R (1991) Diagnosis of osteomyelitis. *Pediatr Rev* 12: 292-297.
15. Sève P, Boibieux A, Pariset C, Clouet PL, Bouhour D, et al. (2001) [Pubic osteomyelitis in athletes]. *Rev Med Interne* 22: 576-581.
16. Alderson M, Speers D, Emslie K, Nade S (1986) Acute haematogenous osteomyelitis and septic arthritis--a single disease. An hypothesis based upon the presence of transphyseal blood vessels. *J Bone Joint Surg Br* 68: 268-274.
17. Zvulunov A, Gal N, Segev Z (2003) Acute hematogenous osteomyelitis of the pelvis in childhood: Diagnostic clues and pitfalls. *Pediatr Emerg Care* 19: 29-31.
18. McPhee E, Eskander JP, Eskander MS, Mahan ST, Mortimer E (2007) Imaging in pelvic osteomyelitis: support for early magnetic resonance imaging. *J Pediatr Orthop* 27: 903-909.
19. Unkila-Kallio L, Kallio MJ, Eskola J, Peltola H (1994) Serum C-Reactive Protein, Erythrocyte Sedimentation Rate and White Blood Cell Count in Acute Hematogenous Osteomyelitis of Children. *Pediatrics* 93: 59-62.
20. Peltola H, Unkila-Kallio L, Kallio MJ (1997) Simplified treatment of acute staphylococcal osteomyelitis of childhood. The Finnish Study Group. *Pediatrics* 99: 846-850.
21. Roine I, Faingezicht I, Arguedas A, Herrera JF, Rodríguez F (1995) Serial serum C-reactive protein to monitor recovery from acute hematogenous osteomyelitis in children. *Pediatr Infect Dis J* 14: 40-44.