

Stentablation as a Successful Treatment Strategy for Stent Underdeployment due to Calcified Plaque

Chelliah RK*, Bourantas C, Thackray SD and Alamgir MF

Hull & East Yorkshire Centre for Cardiology & Cardiothoracic Surgery, Castle Hill Hospital, Cottingham HU16 5JQ, UK

Abstract

Underexpansion of coronary stents represents an increased risk for subsequent stent thrombosis. Rotational atherectomy is now a commonly used technique to reduce the calcium burden in heavily calcified plaques prior to stent deployment. However, once deployed in such plaques prior to rotablation, stent underexpansion may be a challenge and dilemma exists on how best to deal with this clinical situation. In this report we describe a case where an underexpanded stent due to a heavily calcified plaque was successfully treated with stentablation, allowing for full stent expansion afterwards.

Introduction

Underexpansion of coronary stent represents an increased risk for subsequent stent thrombosis [1,2]. Stent underexpansion may be multifactorial, but the presence of heavy calcium burden in plaques remains a significant cause. Predilatation with compliant and non compliant balloons to high pressures alone may not be sufficient. Rotational atherectomy is now a commonly used technique to reduce the calcium burden in heavily calcified plaques prior to stent deployment [3,4]. However, once deployed in such plaques prior to rotablation, stent underexpansion may be a challenge and dilemma exists on how best to deal with this clinical situation. In this report, we describe a case where an underexpanded stent due to a heavily calcified plaque was successfully treated with stentablation, allowing for full stent expansion afterwards.

Case Report

An 81-year-old patient presented with crescendo angina and Canadian Cardiovascular Society (CCS) Class III symptoms. He underwent Coronary Artery Bypass Grafting (CABG) in 1992 with saphenous vein grafts (SVG) to the Left Anterior Descending artery (LAD), first Obtuse Marginal artery (OM) and the Right Coronary Artery (RCA). He had documented occlusion of the vein grafts to the LAD and RCA in 2007. He was initially referred for a redo CABG but this was deemed to be high risk in view of multiple co-morbidities, which included previous colorectal carcinoma and a right upper lobectomy for metastatic carcinoma. Echocardiography showed preserved ejection fraction. Coronary angiography revealed a patent SVG to the OM. The native RCA was heavily diseased in the mid-vessel with subtotal occlusion and heavily calcified plaque (Figure 1). It also provided retrograde collaterals to the LAD and was hence a vital artery and we elected to perform percutaneous coronary intervention (PCI) to the RCA.

Procedure

The RCA was wired with an Asahi Confianza Pro wire. After predilatation, two Promus (Boston Scientific) drug-eluting stents were deployed to the mid-RCA (2.75 × 28 mm proximally and 2.5 × 28 mm distally) (Figure 2). The proximal stent was underexpanded (Figure 2A) and multiple post-dilatations with noncompliant balloons ranging from 2-3 mm in diameter failed to adequately expand the stent. Larger balloons (> 3 mm) failed to track. Intravascular ultrasound (IVUS) was then attempted but the probe failed to track as well. In view on the high contrast load and procedure time, the procedure was halted and the

patient was transferred to the coronary care unit. Glycoprotein IIb/IIIa inhibitor was commenced for 24 hours and the patient returned to the catheter lab the following day.

Two simultaneous balloon inflations (2.5 mm in diameter) were inflated to high pressures (Figure 2B) but this still failed to adequately expand the stent. Stepped rotablation of the proximal stent and plaque was then undertaken with a 1.25 mm and 1.5 mm burr. Post dilatation was then performed with 3.5 mm non-compliant balloon and this successfully dilated the lesion, with good angiographic result (Figure 2C). An IVUS study showed that there was good and adequate stent expansion (Figure 3) and we then decided not to deploy a further stent in this region. He was commenced on dual anti-platelet therapy for 1 year and was discharged the following day uneventfully.

He was assessed at 6 months follow-up and his symptom have improved dramatically and is currently in CCS functional class I. Angiographically, the vessel remains patent with TIMI III flow with no evidence of significant pathology within the rotablated stent (Figure 4).

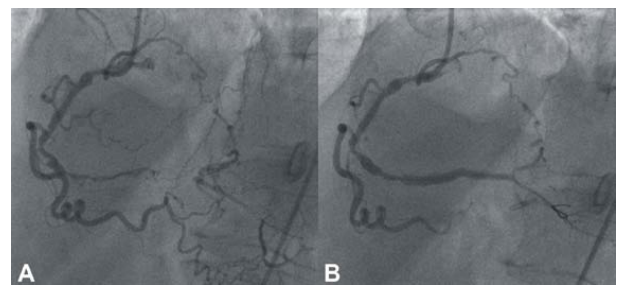


Figure 1: A - The initial appearance of the right coronary artery. B - Appearance following initial wiring and balloon dilatations.

*Corresponding author: Chelliah RK, Hull & East Yorkshire Centre for Cardiology & Cardiothoracic Surgery, Castle Hill Hospital, Cottingham HU16 5JQ, UK, E-mail: raj.chelliah@ed.ac.uk

Received March 21, 2012; Accepted April 06, 2012; Published April 09, 2012

Citation: Chelliah RK, Bourantas C, Thackray SD, Alamgir MF (2012) Stentablation as a Successful Treatment Strategy for Stent Underdeployment due to Calcified Plaque. J Clinic Experiment Cardiol 3:185. doi:10.4172/2155-9880.1000185

Copyright: © 2012 Chelliah RK, et al. This is an open-access article distributed under the terms of the Creative Commons Attribution License, which permits unrestricted use, distribution, and reproduction in any medium, provided the original author and source are credited.

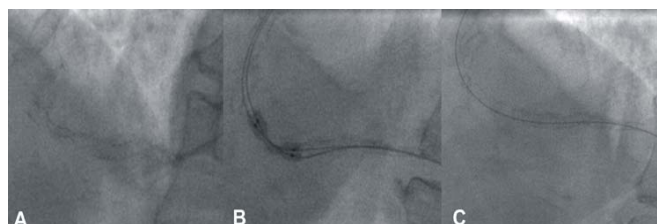


Figure 2: A - Appearances of the artery following initial stent deployment. The under-deployed stent is clearly visible. B - The double balloon technique for post-dilatation of the under-deployed stent. C - Appearance of the stent following stentablation, with the interrupted stent struts visible.

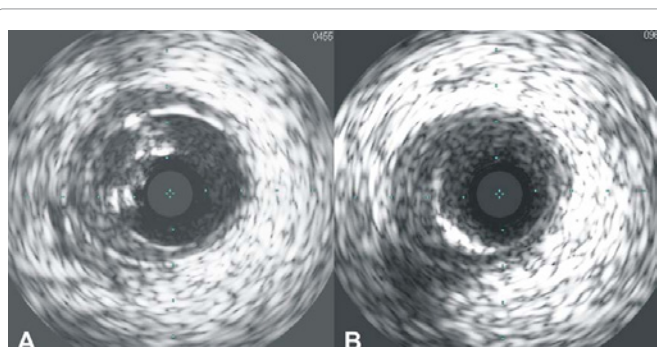


Figure 3: A - Intravascular ultrasound (IVUS) of the RCA following initial stent implantation. The under-deployed struts of the stent and heavy calcium burden are visible. B - IVUS appearance following stentablation. The calcium burden and under-deployed stent struts are no longer visible.

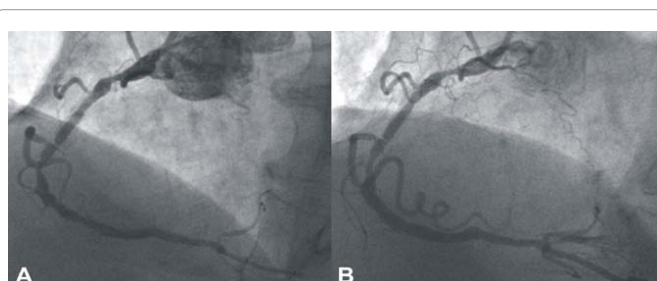


Figure 4: A - Angiographic appearance of the artery immediately following stentablation. B - The appearance following post-dilatation of the rotablated stent.

Discussion

Rotablation has become common practice for lesion preparation prior to stent deployment in heavily calcified plaques as evidence suggests they facilitate balloon and stent expansion [3,4]. However, the calcium burden in certain plaques may be underappreciated during coronary angiography, complicating the procedure. It is therefore, important to use adequately sized predilatation balloons in order to appreciate the adequate expansion of a lesion. If this fails, rotablation is usually carried out at a separate sitting to reduce the risk of coronary complications. In an attempt to generate higher radial and longitudinal forces to facilitate stent expansion, a simultaneous double balloon technique was used and the failure to do so provided us with an indication of the severity of the calcification.

There is limited evidence for best practice in this situation and others have previously reported similar situations as ours [5,6], with

similar clinical outcomes. Ideally the operators should take every necessary precaution to prevent the situation of an underdeployed stent, including ensuring adequate predilatation and ensuring sufficient balloon expansion, and also using IVUS to better understand the lesion anatomy as calcium burden may easily be underestimated. Rotablation can then be performed as necessary, prior to stent implantation.

It is well known that contrast induced nephropathy may present itself only after several days. Hence if the patient is stable, the operator may need to allow sufficient time for contrast washout to ensure stability of renal function. However in this case, we elected to perform the second procedure after 24 hours for clinical reasons, as there was a concern that the patient was still experiencing intermittent chest discomfort.

The case we describe is unique in that the ablated stent was not covered with a further stent. This was a clinical decision taken as we were satisfied with the results achieved and to reduce the further risk of coronary complications, procedure time and dye load. We instead elected to commence glycoprotein IIb-IIIa inhibitors to reduce the risk of acute stent thrombosis and no-reflow phenomena during the stentablation procedure. IVUS should ideally be performed before the stentablation and remains a vital adjunct during such procedures as it gives us vital additional information regarding stent apposition and calcium burden.

Conclusion

Despite advances in interventional techniques and technology, this case highlights the need for careful lesion preparation prior to stent implantation. If stent underexpansion does occur due to calcified plaques, stentablation with rotational atherectomy appears to be a safe and well-tolerated procedure based on this experience, allowing for full stent expansion afterwards and reducing the risk of stent thrombosis. However, there is limited data on this matter and further studies are required to address this rare but important clinical scenario.

References

1. Uren NG, Schwarzacher SP, Metz JA, Lee DP, Honda Y, et al. (2002) Predictors and outcomes of stent thrombosis: an intravascular ultrasound registry. *Eur Heart J* 23: 124-132.
2. Cheneau E, Leborgne L, Mintz GS, Kotani J, Pichard AD, et al. (2003) Predictors of subacute stent thrombosis: results of a systematic intravascular ultrasound study. *Circulation* 108: 43-47.
3. Dill T, Dietz U, Hamm CW, Kuchler R, Rupprecht HJ, et al. (2000) A randomised comparison of balloon angioplasty versus rotational atherectomy in complex coronary lesions (COBRA study). *Eur Heart J* 21: 1759-1766.
4. Niccoli G, Testa L, Mongiardo R, Ricco A, Belloni F, et al. (2006) Directional atherectomy before stenting versus stenting alone in percutaneous coronary interventions: a meta-analysis. *Int J Cardiol* 112: 178-183.
5. Lee S, Park KW, Kim HS (2010) Stentablation of an underexpanded stent in a heavily calcified lesion using rotational atherectomy. *J Cardiovasc Med (Hagerstown)* 13: 284-288.
6. Kobayashi Y, Tierstein P, Linnemeier T, Stone G, Leon M, et al. (2001) Rotational atherectomy (stentablation) in a lesion with stent underexpansion due to heavily calcified plaque. *Catheter Cardiovasc Interv* 52: 208-211.