

Sport-Induced Vasculitis

Alessandra Pavesi, Francesco Drago, Davide Basso* and Aurora Parodi

Department of Endocrinological and Metabolic Sciences, Section of Dermatology, University of Genoa, Italy

Abstract

Sport-induced vasculitis is a frequently misdiagnosed or ignored disease that occurs after prolonged muscular activity. Erythematous, urticarial or purpuric lesions arise on the lower leg. They are asymptomatic or sometimes itchy, painful or burning; usually fade after resting for a few days to relapse promptly when training is resumed. We present an unusual case arising in a water-sport never reported before.

Keywords: Vasculitis; Exercise purpura; Sport associated diseases

Introduction

Worldwide there is a growing interest in people for sports and fitness and in sports medicine. Exercise-induced vasculitis is an underestimated erythematous, urticarial or purpuric lesions developing on the lower legs in healthy subjects after a strenuous muscular activity as running or climbing, especially in hot weather [1-4].

Recently it has also been described in golfers and hikers. Our report describe the case of an exercise-induced vasculitis in a young swimmer, sport never reported before in literature.

Case Report

A 16 years old girl, otherwise healthy, agonist swimmer, came to our observation complaining of the onset, one year earlier, of persistent and diffuse erythematous lesions on lower limbs. The patient denied any drug intake and her prior medical history was irrelevant.

Clinical examination displayed on her legs a few patches and pinpoint erythematous-purpuric macules and papules, irregularly shaped, measuring around 1 cm in diameter and partly persistent under diascopy; some lesions had resolved leaving slight hyperpigmentation (Figure 1 and Figure 2). The lesions were asymptomatic with occasional burning sensation before their appearance.

Laboratory investigations including full blood examination, coagulation times, thyroid and rheumatic tests, antinuclear antibodies, pharyngeal and vaginal swabs, urine culture, urea breath test and serology for viruses were negative or within normal values. Chest X rays, electrocardiogram, ovarian and adrenal glands ultrasounds, lower limbs doppler ultrasonography displayed no abnormalities.

A biopsy specimen from a lesion demonstrated orthokeratotic

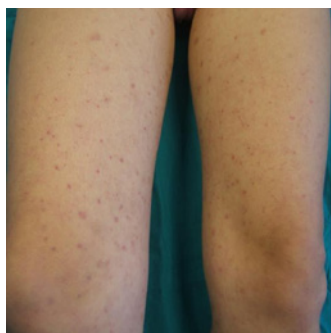


Figure 1: Erythematous-purpuric macules and papules on thighs.

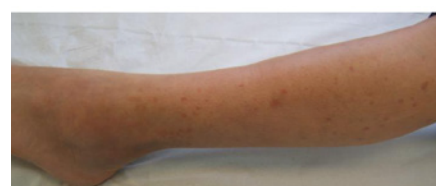

Figure 2: Erythematous-purpuric macules and papules on lower legs.

hyperkeratosis, with some focal vacuolar degeneration of the basal membrane and a mostly lymphocytic perivascular mononuclear infiltrate with scanty leucocytoclasia of neutrophils in the superficial dermis, vessels hyperplasia and endothelial swelling with some extravasated erythrocytes.

Direct immunofluorescence demonstrated granular IgM and C3 deposits at the dermoepidermal junction and C3 in superficial dermal vessels. A diagnosis of leukocytoclastic vasculitis was done.

Meanwhile, the patient referred clinical improvement with resolution of the eruption during summertime, when she stopped swimming, then followed by a prompt relapse in autumn, just a few weeks after the resumption of her training program.

A therapy with oral diosmine and esperidine has been established and the patient was advised to wear elastic socks (medium graduated compression).

After 2 months of therapy the lesions partially subsided on clinical examination, displaying only slightly hyperpigmented post-inflammatory maculae, and no evidence of new lesions.

Discussion

Exercise-induced vasculitis is an under-recognized and frequently misdiagnosed disease. It affects healthy subjects following a strenuous

*Corresponding authors: Davide Basso, Department of Endocrinological and Metabolic Sciences, Section of Dermatology, University of Genoa, Italy, Tel: 390105555768, 393491507577; Fax: 390105556509; E-mail: dassio@fastwebnet.it

Received January 17, 2011; Accepted March 30, 2011; Published March 31, 2011

Citation: Pavesi A, Drago F, Basso D, Parodi A (2011) Sport-Induced Vasculitis. J Clin Exp Dermatol Res 2:119. doi:10.4172/2155-9554.1000119

Copyright: © 2011 Pavesi A, et al. This is an open-access article distributed under the terms of the Creative Commons Attribution License, which permits unrestricted use, distribution, and reproduction in any medium, provided the original author and source are credited.

effort as long distance running or hiking. However it has also been described in jogging [5], step aerobics [6], body building [7], and recently in a series of golfers [8].

The mean age at onset was over 50 years and males seem to be affected more rarely than females.

Clinical features are asymptomatic or sometimes itchy or burning, erythematous, urticarial or purpuric lesions, typically worsened by high temperatures. There is a neither abdominal nor systemic symptom. Usually the lesions fade spontaneously after some days, with frequently relapses during similar exercise. Many patients and physicians believe that is an allergic reaction to grasses or chemicals.

Histology showed aspects of leucocytoclastic vasculitis with immunologic deposits at direct immunofluorescence. In addition the microscopic finding may depend on the delay between the onset of the eruption and the time of biopsy.

Laboratory investigations usually gave no results though very recently a case of exercise induced vasculitis has been reported associated with autoimmune disease.

Though etiology is still unknown a main role might be played by the heat produced by big muscle groups, especially in wet warm weather or climate. In such conditions heat-regulation mechanisms are deficient and muscular hyperthermia may develop and reach temperatures even higher than 41°C inducing damage of muscle fibers [9,10].

In addition anaerobiosis increasing lactic acid load, may worsen tissue damage. Complement activation has also been reported to occur in association with prolonged exercise [11,12]. The mechanism of activation of complement is not known, but may be a non-specific immune response to muscle cell inflammation caused by prolonged physical activity. Cytokine release and changes in the expression of adhesion molecules may contribute to inflammation and complement activation.

Lower limbs edema or lipoedema, quite rare in athletes, may be important, although not necessary, predisposing factor. In fact fat tissue greatly reduces transcutaneous heat loss, increasing active muscles temperature. Chronic venous insufficiency and sun exposure [13,14] are not generally considered predisposing factors.

Our patient is the first case of exercise-induced vasculitis in a swimmer. This is rather curious since it is well known that aqua exercise promotes the recovery of physiological functioning of the muscles in the

legs after high-intensity eccentric exercise such as downhill running [15].

In addition, in a swimmer, the pool water should compensate the increase of muscular hyperthermia that happens during prolonged exercise. Finally the age of the patient is lower than the average of patients suffering from this condition.

Our case stresses how exercise-induced vasculitis may arise even in water-sports, where muscle temperature doesn't get to the higher values reached during land-sports as marathon or biking. Dermatologists should be aware of this relatively common condition that is still poorly described in the literature or in the textbooks.

References

1. Prins M, Veraart JC, Vermeulen AH, Hulsmans RF, Neumann HA (1996) Leucocytoclastic vasculitis induced by prolonged exercise. *Br J Dermatol* 134: 915-918.
2. Ramelet AA (2006) Exercise-induced vasculitis. *JEADV* 20: 423-427.
3. Ramelet AA. (2004) Exercise-induced purpura. *Dermatology* 208: 293-296.
4. Knoell KA (2009) Exercise-induced vasculitis associated with autoimmune disease. *Cutis* 83: 319.
5. Cohen HJ (1968) Jogger's petechiae. *N Engl J Med* 279: 109.
6. Allan SJR, Humphreys F, Buxton PK (1994) Annular purpura and steps aerobics. *Clin Exp Dermatol* 19: 418.
7. Schapira D, Braun Y, Bergman R, Nahir M (1999) Leucocytoclastic vasculitis in a young body builder. *Clin Exp Rheumatol* 17: 125-126.
8. Kelly RI, Opie J, Nixon R (2005) Golfer's vasculitis. *Australas J Dermatol* 46: 11-14.
9. Armstrong RB (1986) Muscle damage and endurance events. *Sports Med* 3: 370-381.
10. Couzan S, Pruffer M (2002) Un nouveau concept de contention-compression. Apport de l'écho-doppler couleur avec prise des pressions veineuses et de l'IRM. *Phlébologie* 55: 159-171.
11. Dufaux B, Order U (1989) Complement activation after prolonged exercise. *Clin Chim Acta* 179: 45-49.
12. Smith JK, Chi DS, Krish G, Reynolds S, Cambron G (1990) Effect of exercise on complement activity. *Ann Allergy* 65: 304-310.
13. Veraart JC, Prins M (1994) Influence of endurance exercise on the venous refilling time of the leg. *Phlebology* 23: 120-123.
14. Veraart JC, Prins M (1995) Effet d'une marche de 80 km sur le système veineux. *Phlebology* 48: 429-431.
15. Takahashi J, Ishihara K, Aoki J (2006) Effect of aqua exercise on recovery of lower limb muscles after downhill running. *J Sports Sci* 24: 835-842.